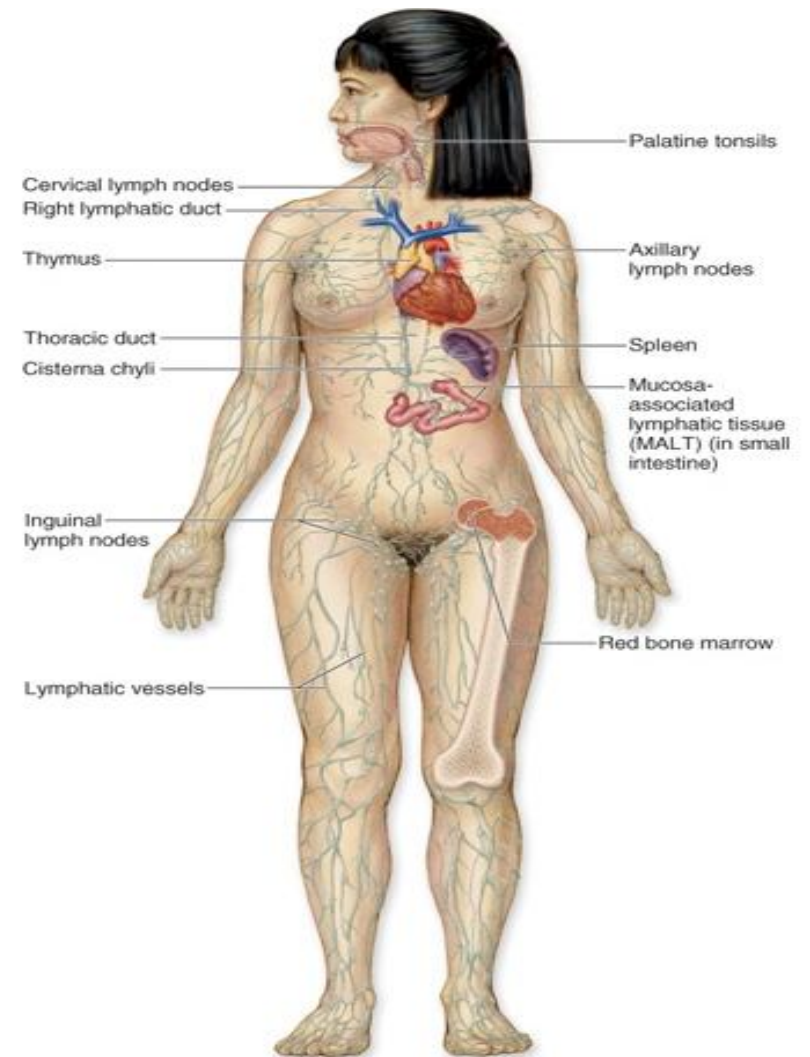


# LYMPHATIC SYSTEM



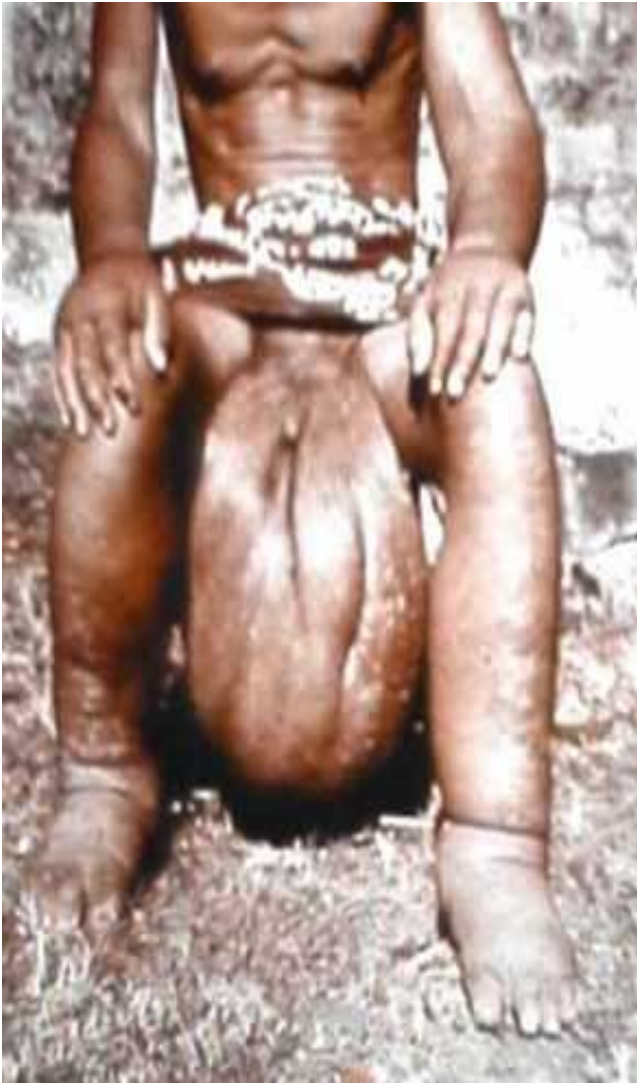**Lymphatics are found in all tissues except the :**

- CNS,**
- cartilage,**
- bone**
- bone marrow,**
- thymus,**
- teeth,**
- placenta.**

Lymphatics are sometimes difficult to demonstrate satisfactorily in normal tissues because these **large, thin-walled vessels frequently collapse to the point of invisibility during tissue processing.**


Lymphatics are often most easily visualized and studied during pathological processes (e.g., inflammation).

Lymphatics start as blind-ended lymphatic capillaries which coalesce to form lymphatic vessels and finally empty into the circulation via the lymphatic ducts (thoracic and right lymphatic).

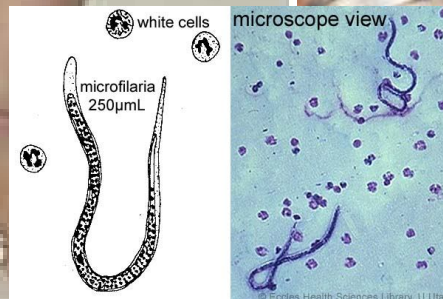
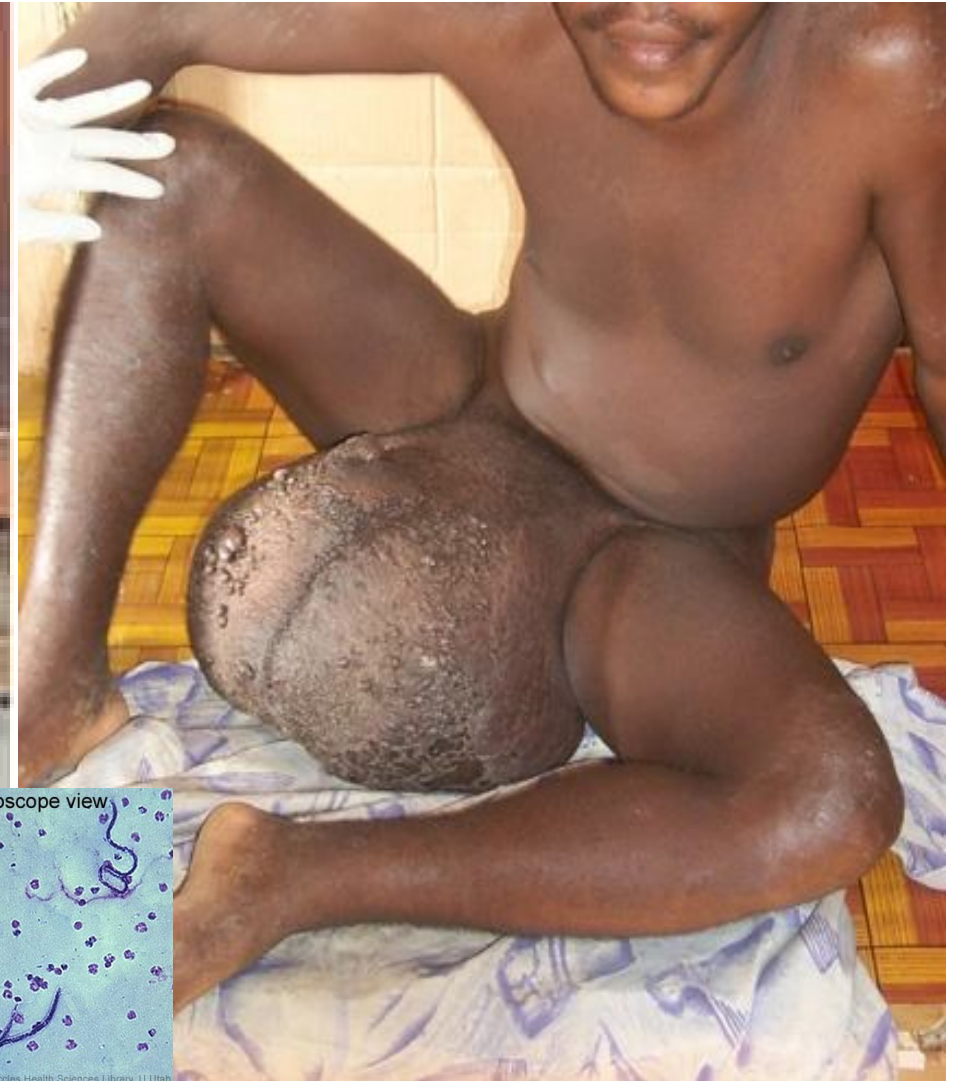
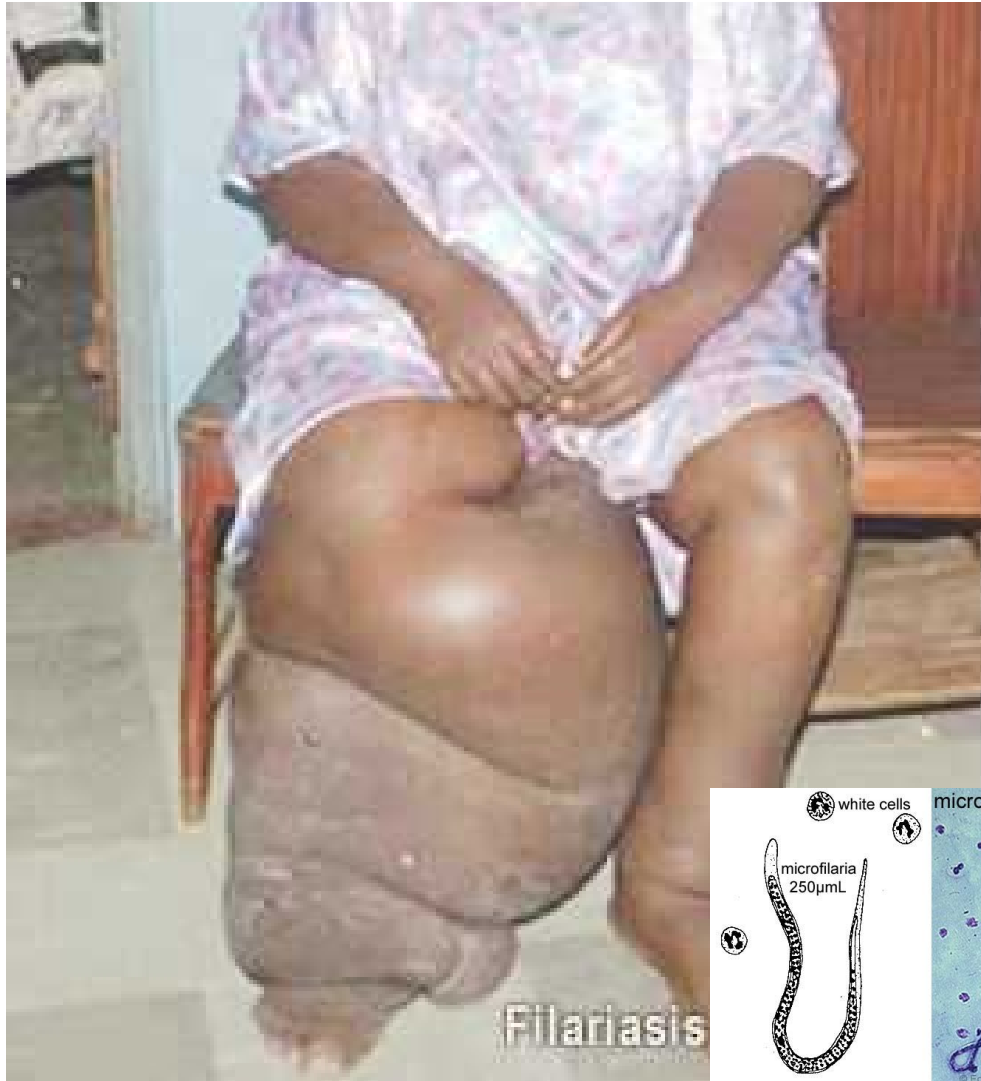
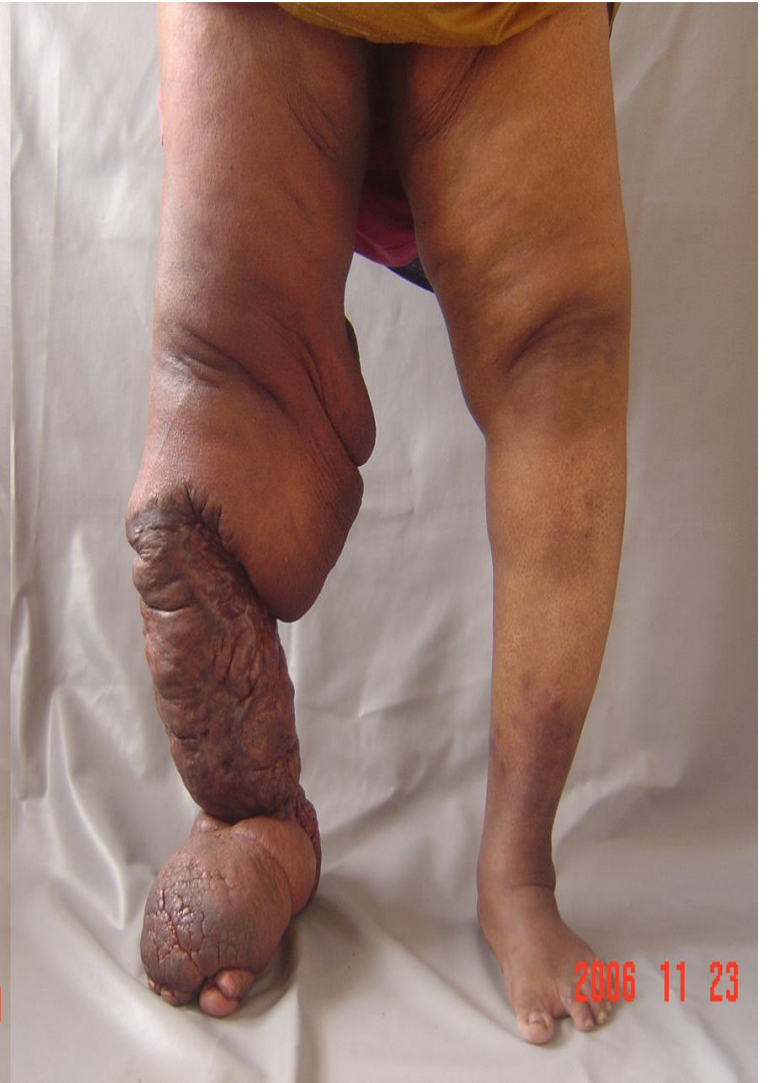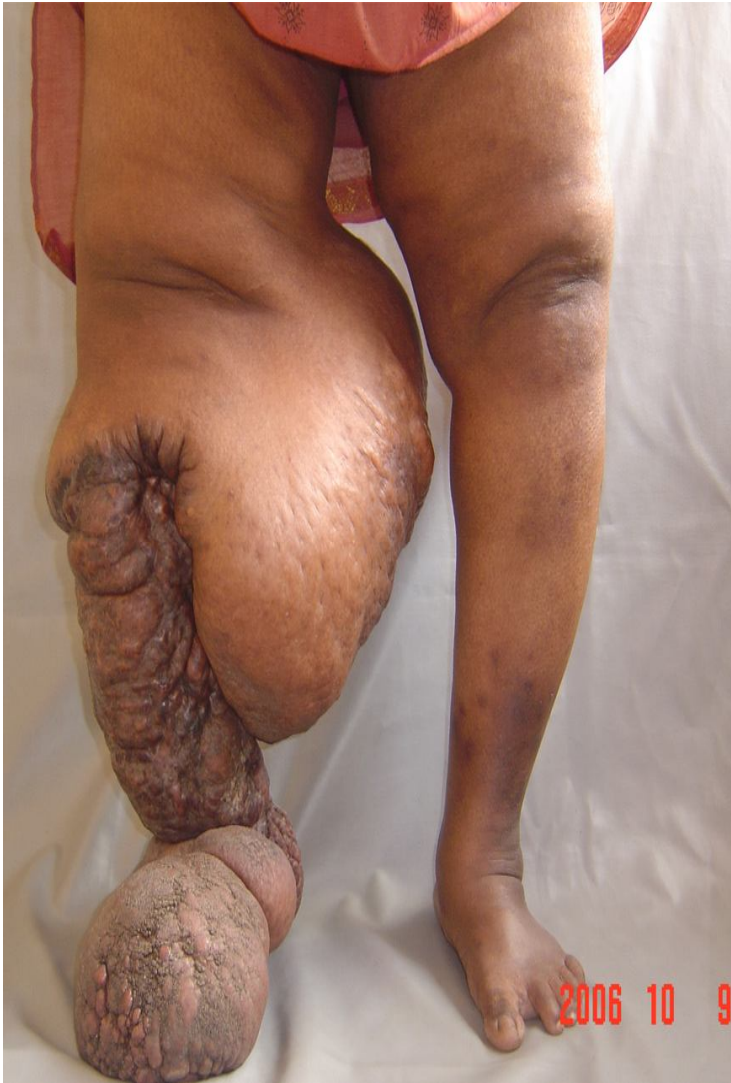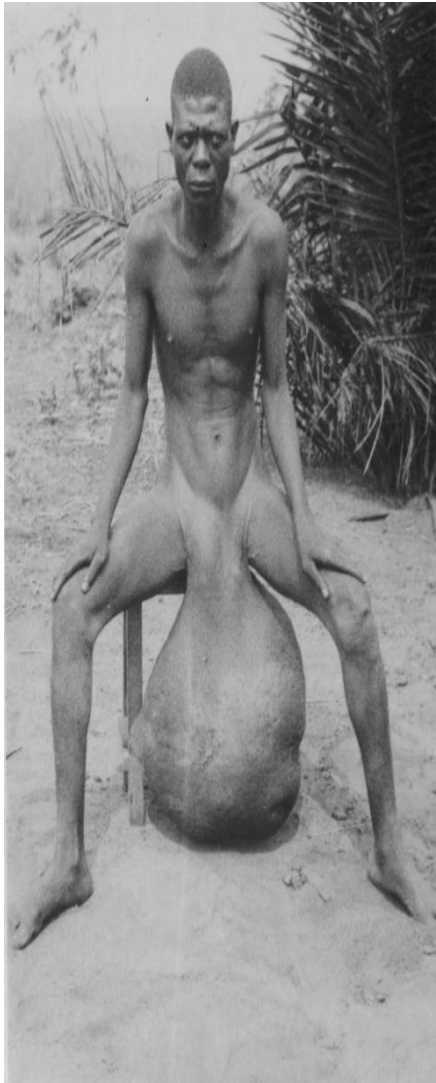### **Elephantiasis.**

Elephantiasis is a condition of extreme edema that occurs when lymph vessels become blocked by filarial worms. Here the left leg is swollen with the fluids accumulated in the tissues as a result of the blockage.



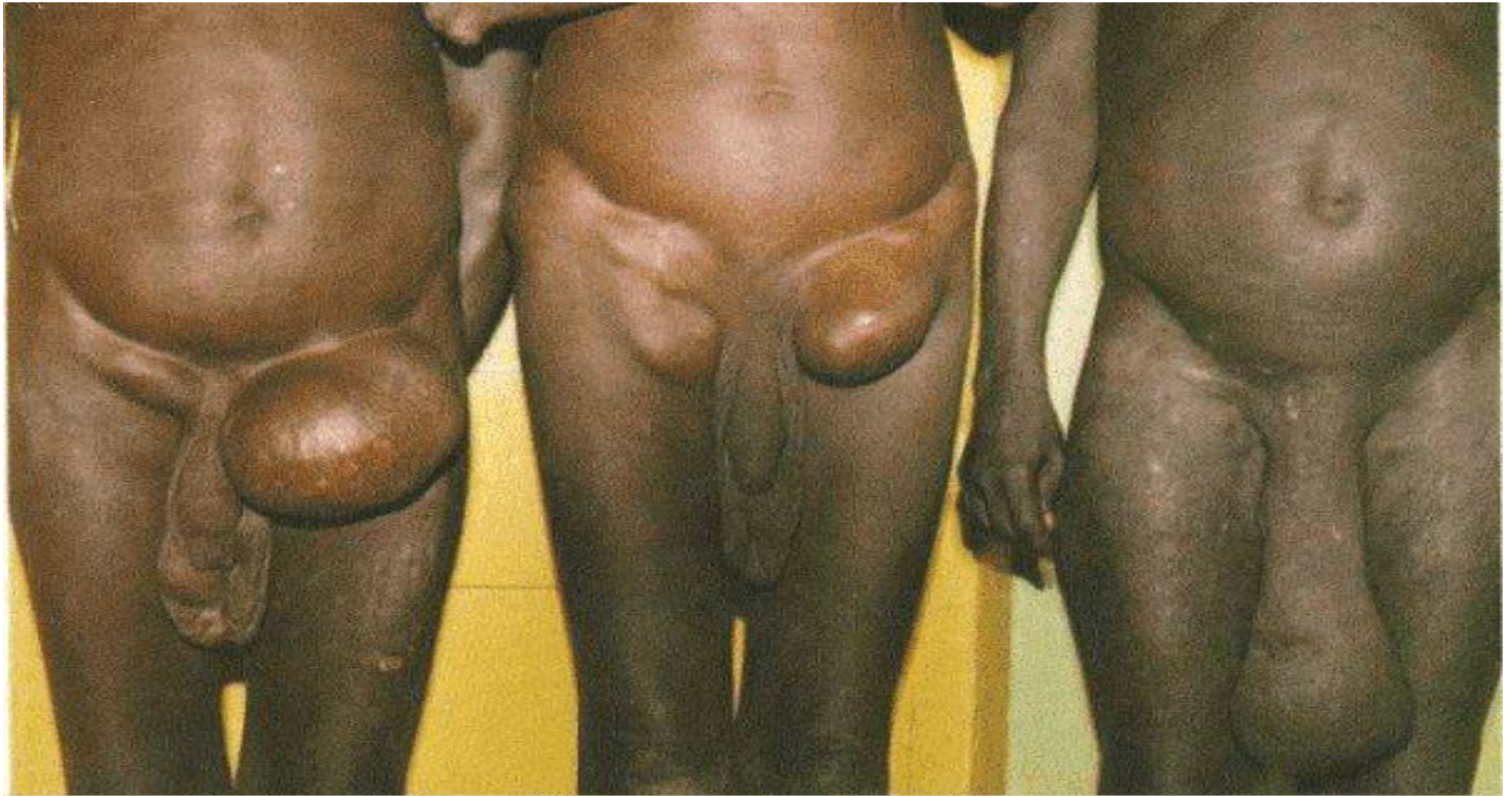








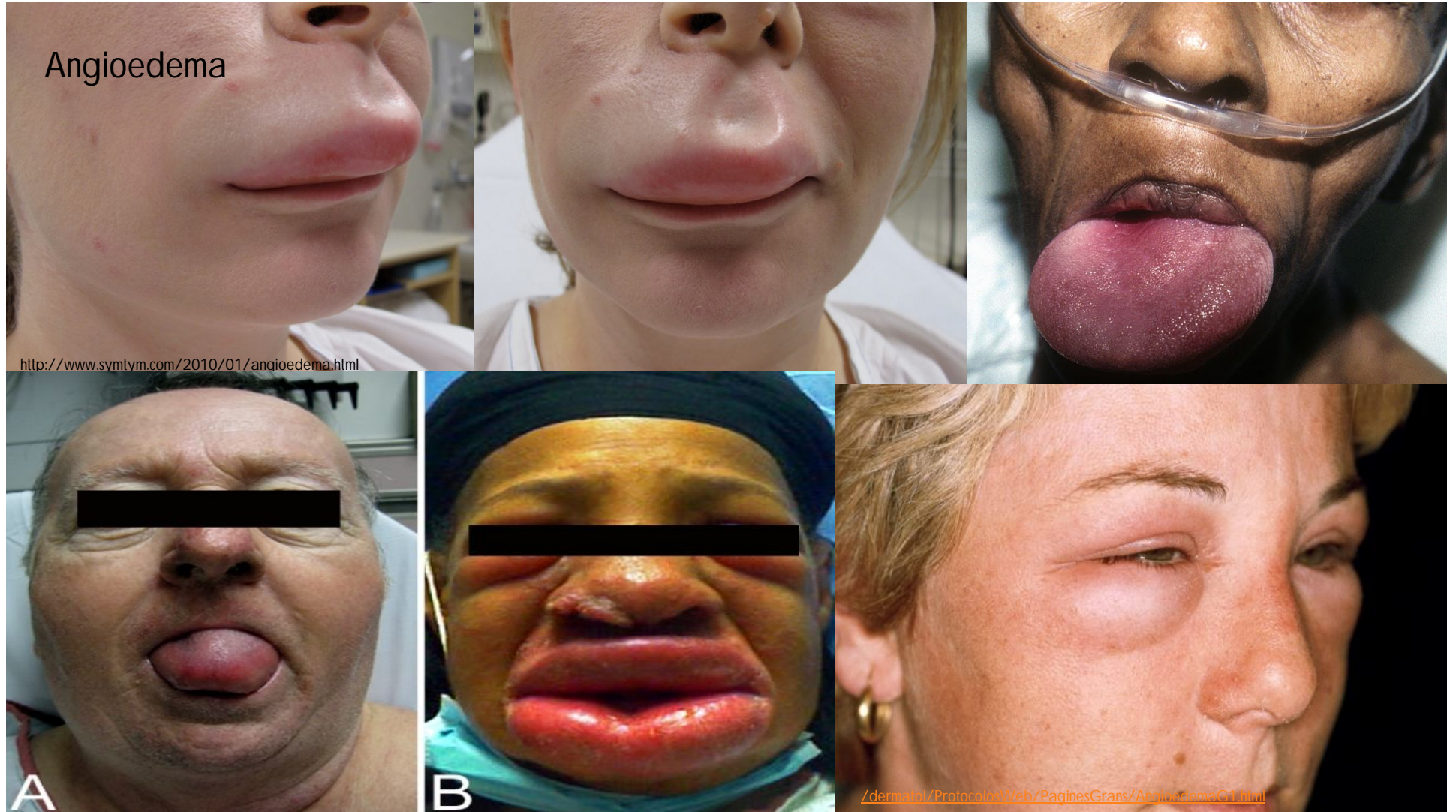


***Wuchereria bancrofti* - (bancroftian filariasis) (Elephantiasis)**

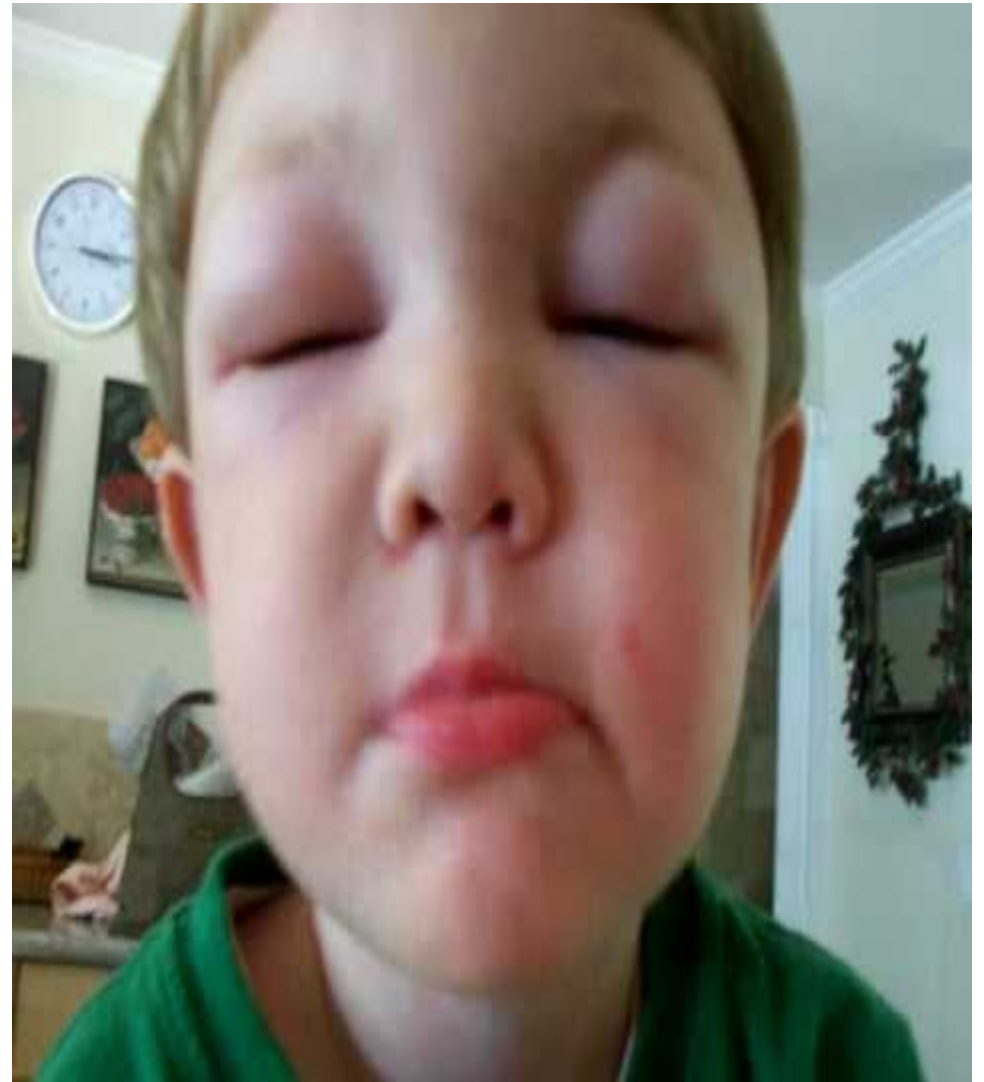

# Angioedema



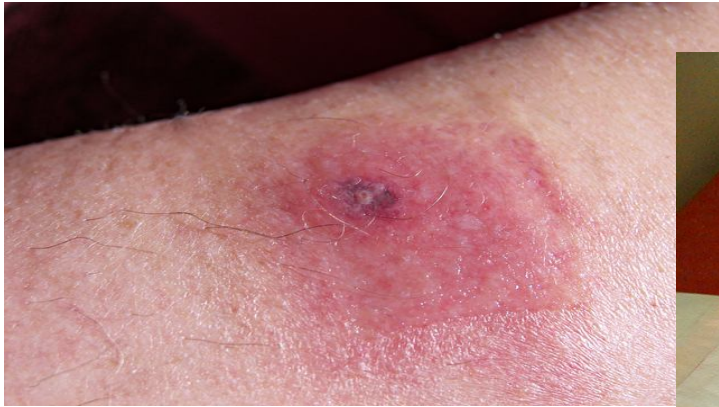Angioedema refers to increased vascular permeability below the dermis leading to edema. This process is similar to urticaria and is the result of vasoactive mediators such as histamine, serotonin, and bradykinin.

Angioedema has many causes, including: food, drugs/medication, hymenoptera exposure, complement-mediated, hereditary, malignancy, and idiopathic.

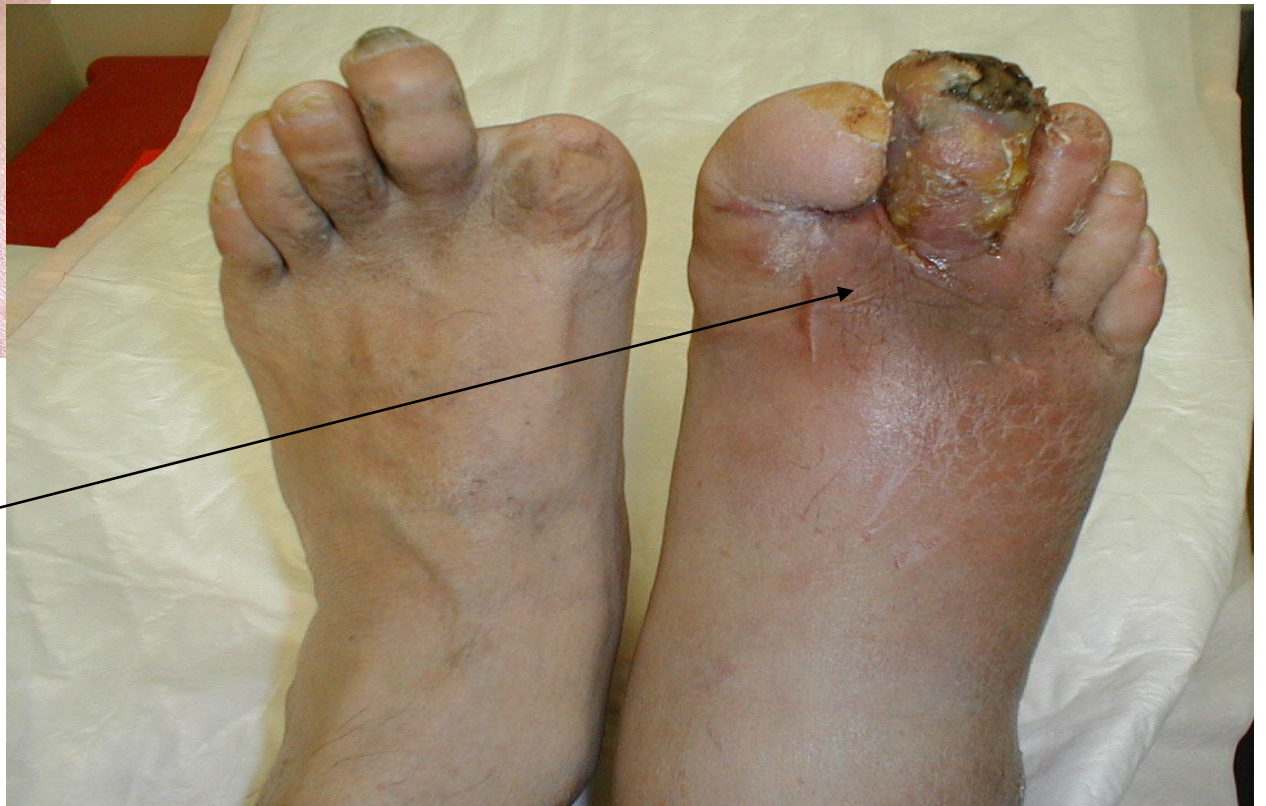




Crucial in helping the body ward off  
disease and heal from injury



Advanced infection from  
poor circulation



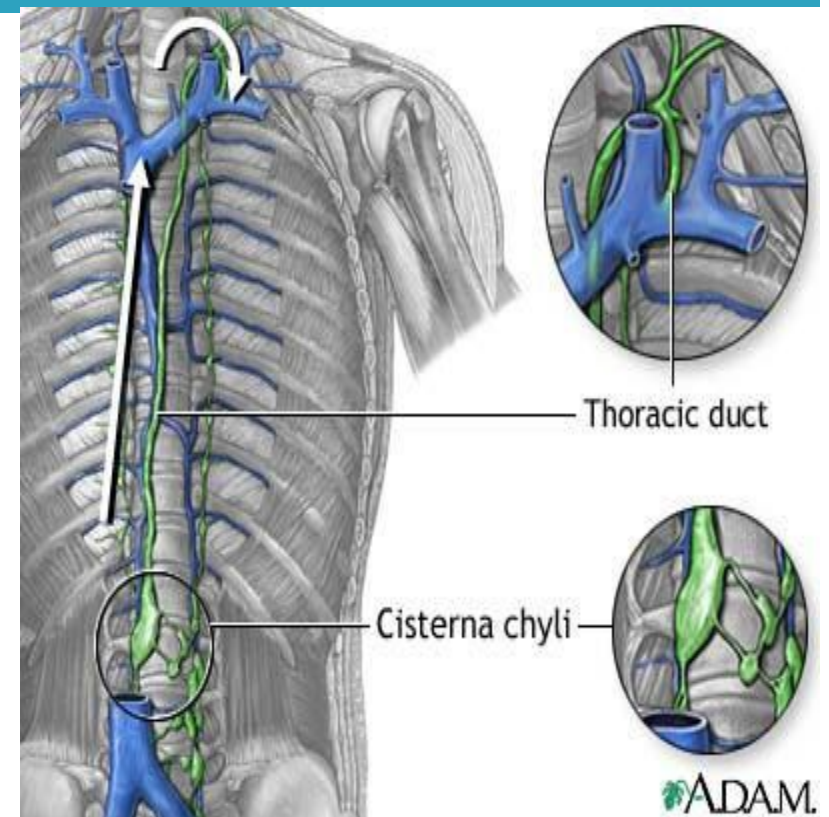
# Importance of the Lymphatic System

- Two most important functions
  - Maintenance of fluid balance in the internal environment.
  - Immunity
- Importance of the lymphatic system in maintaining fluid balance.
  - Plasma filters into the interstitial spaces from blood flowing through the capillaries.
  - Much of this interstitial fluid is absorbed by tissue cells or reabsorbed by the blood before it flows out of the tissue.
    - A small amount of interstitial fluid is left behind.
      - If this would continue over even a brief period of time, the increased interstitial fluid would cause massive edema.
  - This edema would causes tissue destruction or death
  - This problem is avoided by the presence of lymphatic vessels that act as "drains" to collect the excess fluid and return it to the venous blood just before it reaches the heart.
- The lymphatic system is a specialized component of the circulatory system.
  - Consists of a moving fluid (lymph) derived from the blood and tissue fluid and a group of vessels (lymphatics) that returns lymph to the blood.
  - Lymphatic vessels parallel veins.

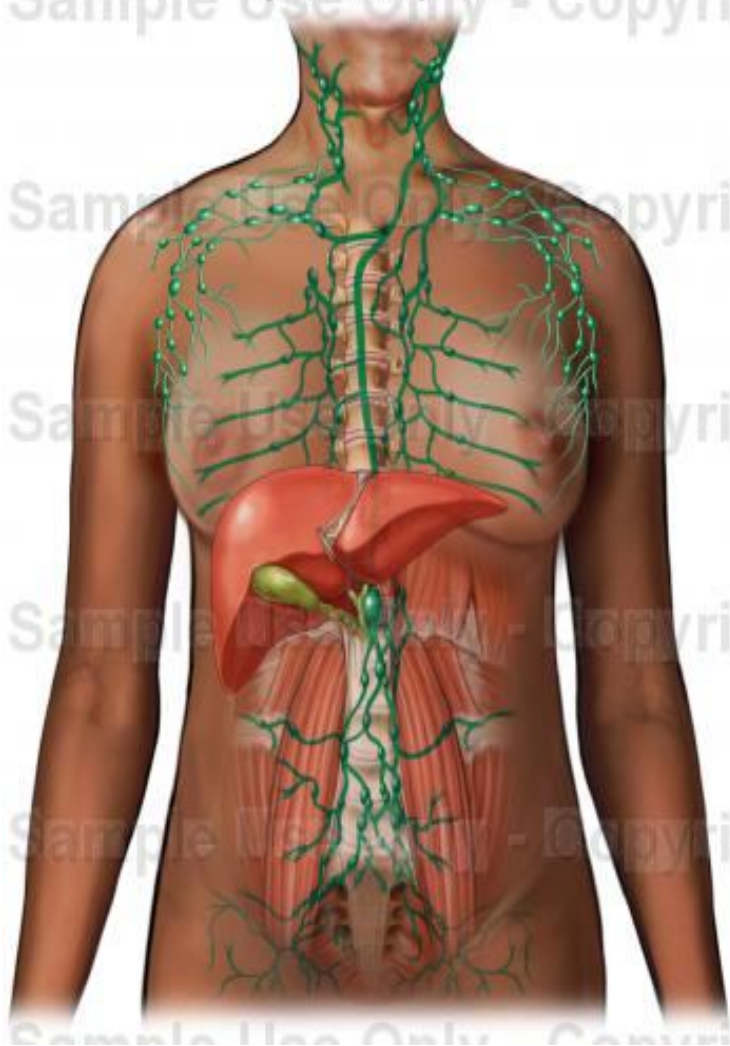


# Functions of Lymphatic System

- ❑ Drain fluid from around cells
- ❑ Absorb fat from intestines
- ❑ Circulate lymph
- ❑ Filter lymph
- ❑ Immunity



Lymphatic System



- The lymphatic system serves several important functions in the body.
  - \*It drains fluid from around cells to prevent fluid build up.
  - \*Lymphatic capillaries are also able to absorb fat from the intestines.
  - \*The fluid that is circulated by the lymphatic system is called lymph.
  - Lymph is filtered by the lymphatic system to remove such things as microorganisms and wandering cancer cells.
- \*The lymphatic system also gives us our immunity.

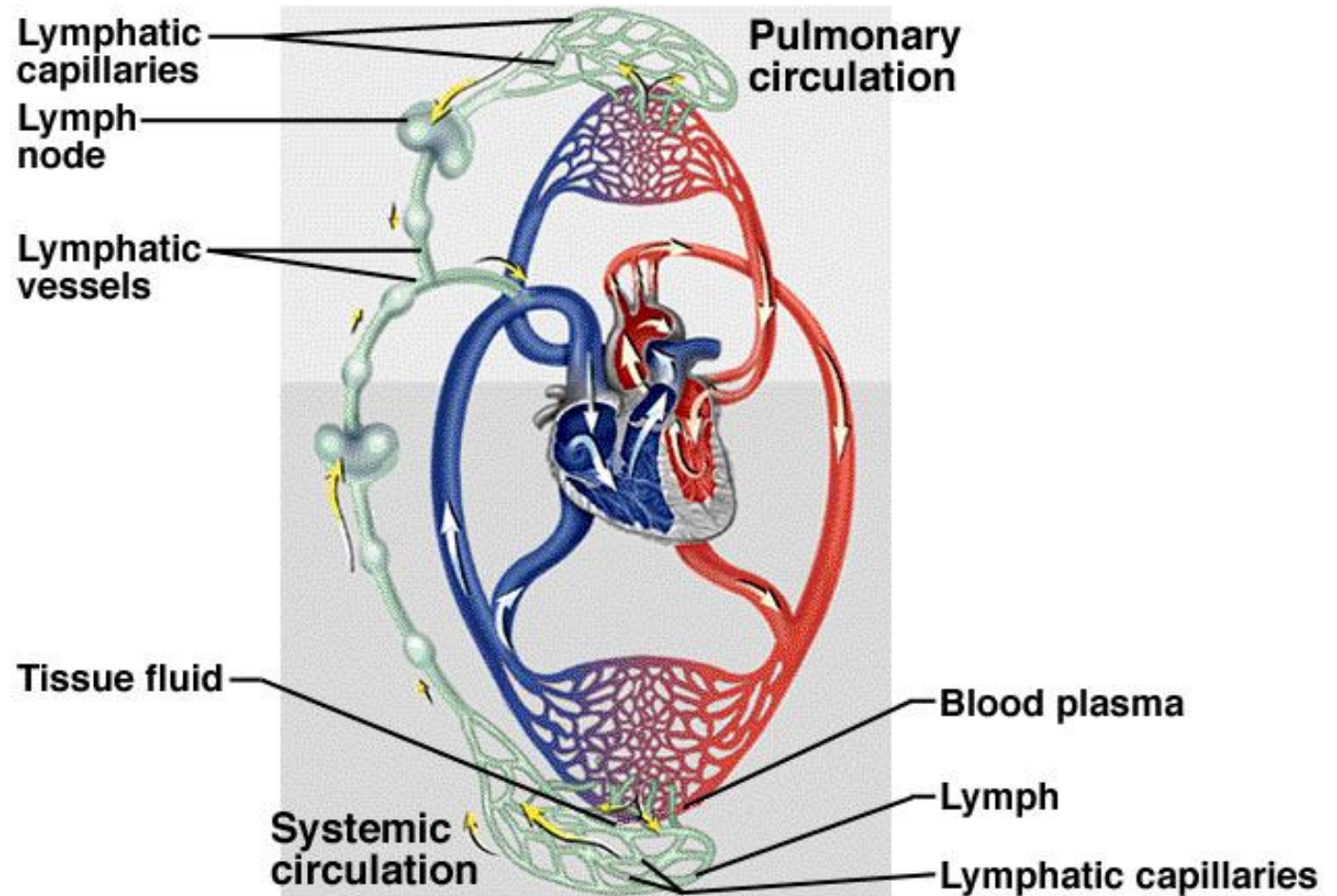
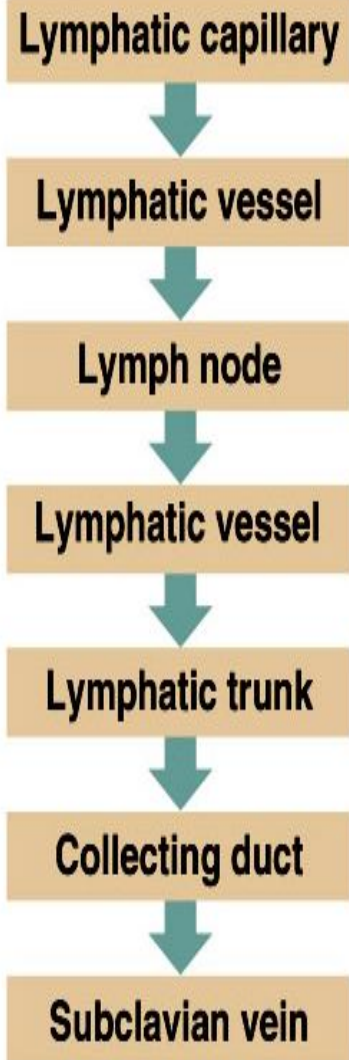
# Lymph (lymph = clear fluid)

- ❑ derived from tissue fluid
  - ❑ contains more white blood cells than plasma
  - ❑ enters node through afferent lymphatic vessels
  - ❑ flows through node in one direction
- flows through sinuses in lymph node cortex and then into the medulla
  - exits the lymph node through efferent lymphatic vessels
  - must be returned to blood stream to maintain blood volume and pressure

# Lymphatic System: Overview

---

- Consists of two semi-independent parts:
  - ▣ A network of lymphatic vessels
  - ▣ Lymphoid tissues and organs scattered throughout the body
- Returns interstitial fluid and leaked plasma proteins back to the blood
- Lymph – interstitial fluid once it has entered lymphatic vessels

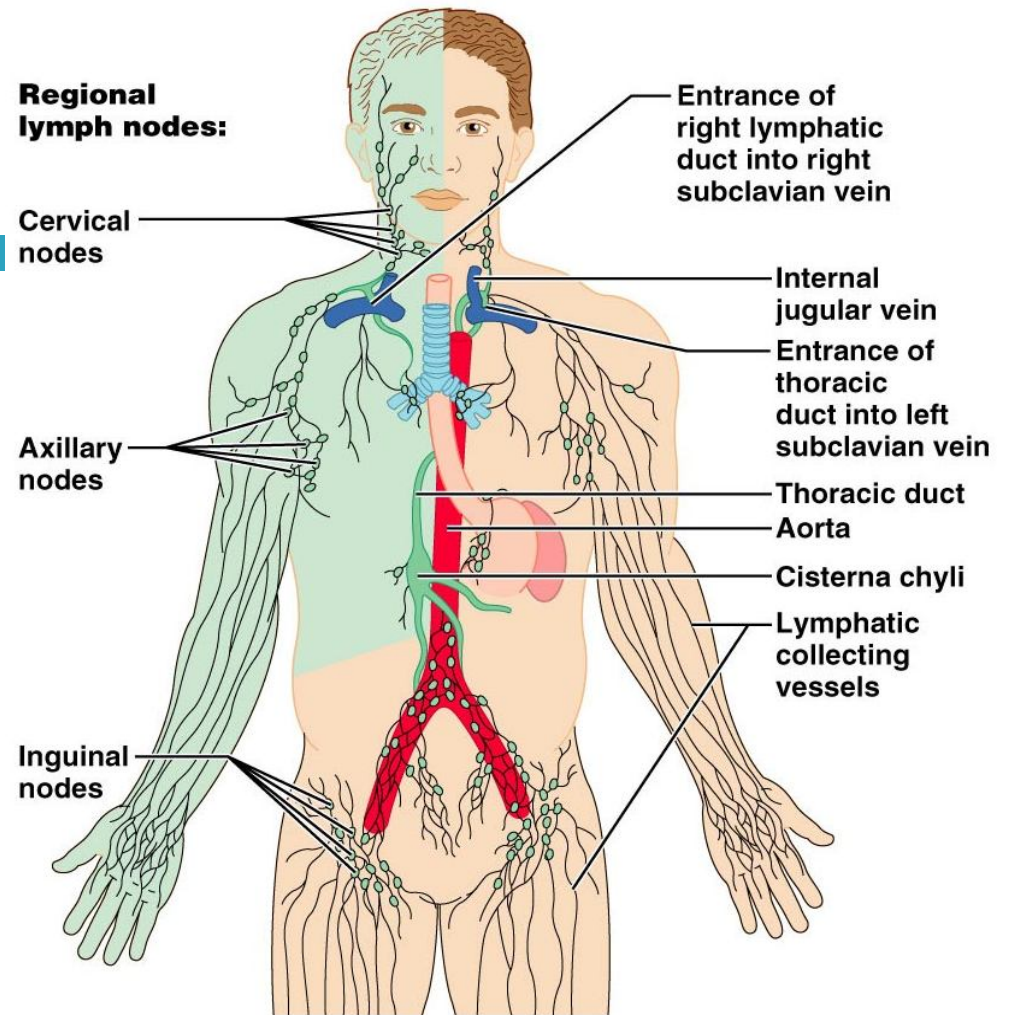




# Lymphatic System

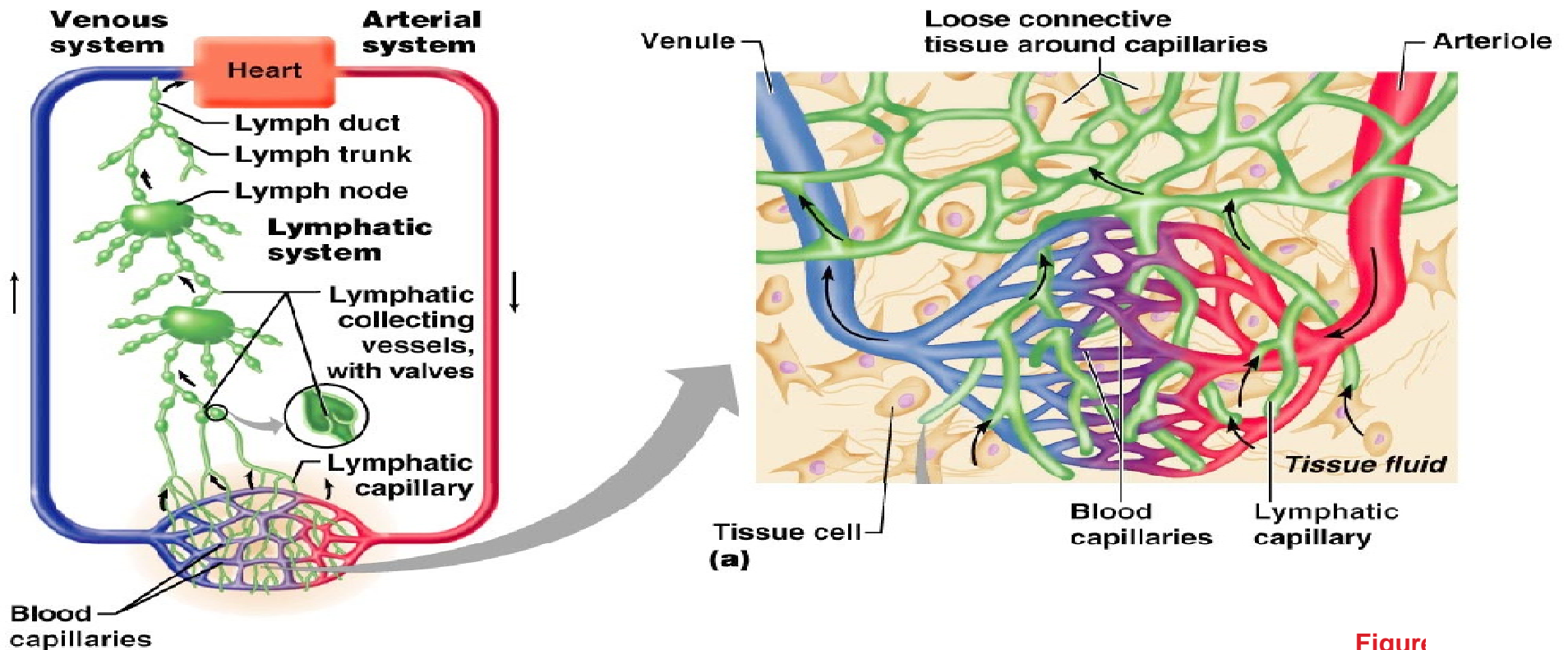
## □ Consists of:

- lymph
- network of vessels
- lymph nodes and nodules
- tonsils
- spleen
- thymus gland
- bone marrow



(a)

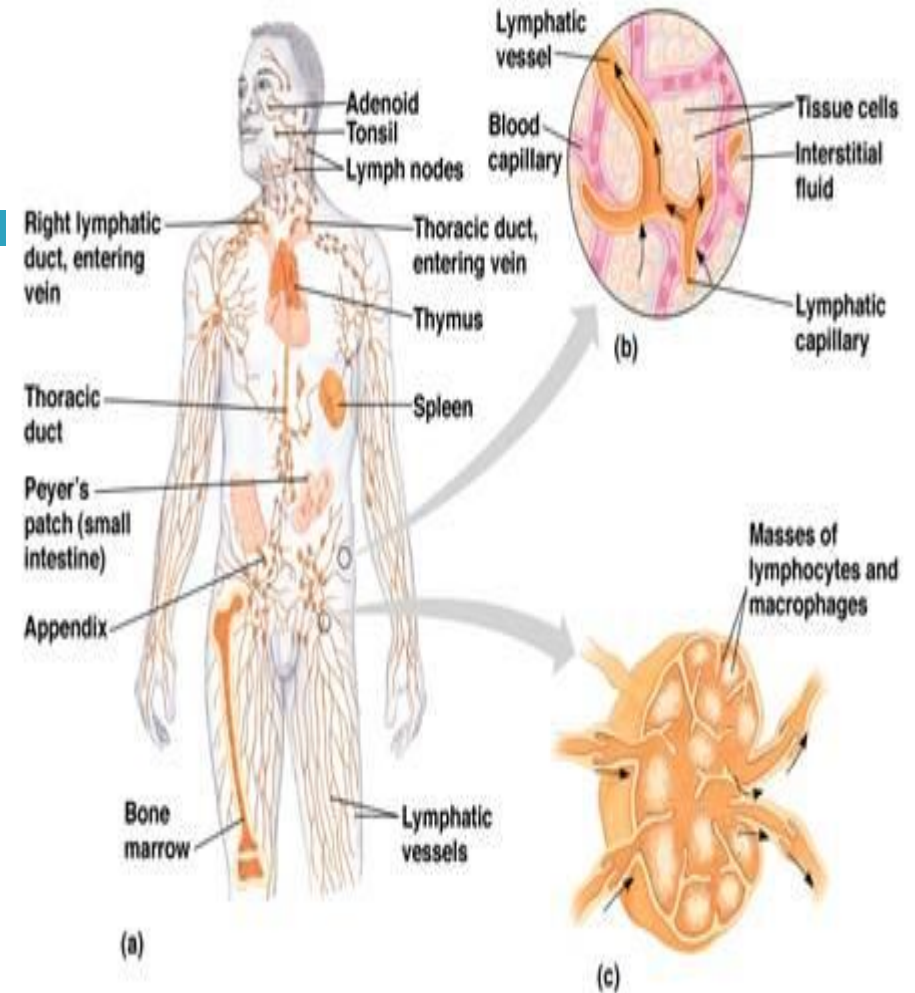
# Lymphatic System: Overview



Figure

# Lymphatic Vessels

- One-way system, lymph flows toward the heart
- Lymph vessels include:
  - ▣ Microscopic, permeable, blind-ended capillaries
  - ▣ Lymphatic collecting vessels
  - ▣ Trunks and ducts





**Lymphatic vessels resemble veins in structure with these exceptions:**

- Lymphatics have thinner walls.**
- Lymphatics contain more valves.**
- Lymphatics contain lymph nodes located at certain intervals along their course.**

# Lymph Vessels

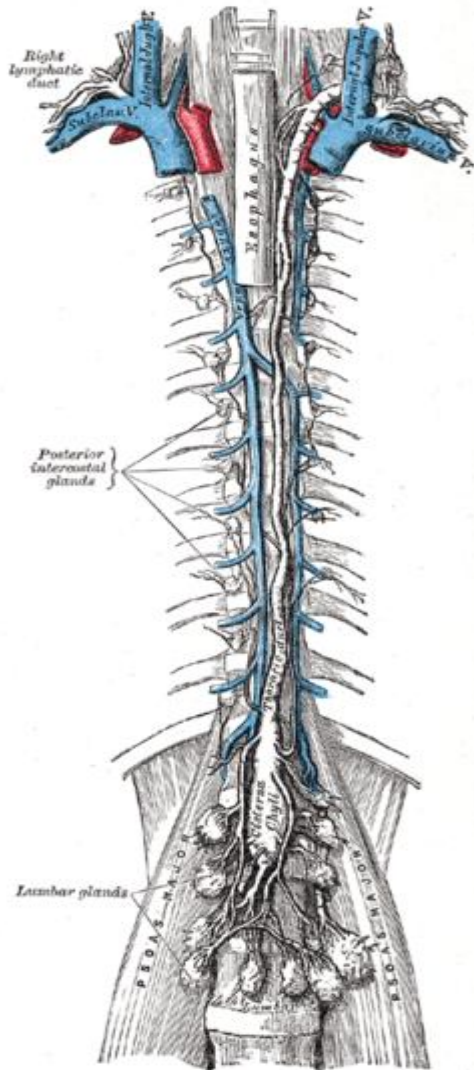
---

- no pump for lymph
- **Lymph is kept moving by:**
  - *constriction of vessels*
  - *skeletal muscle pump*
  - *respiratory pump*
- at intervals along vessels lymph flows into lymph nodes
- lymphatic vessels unite to form lymph trunks

# Lymphatic Trunks

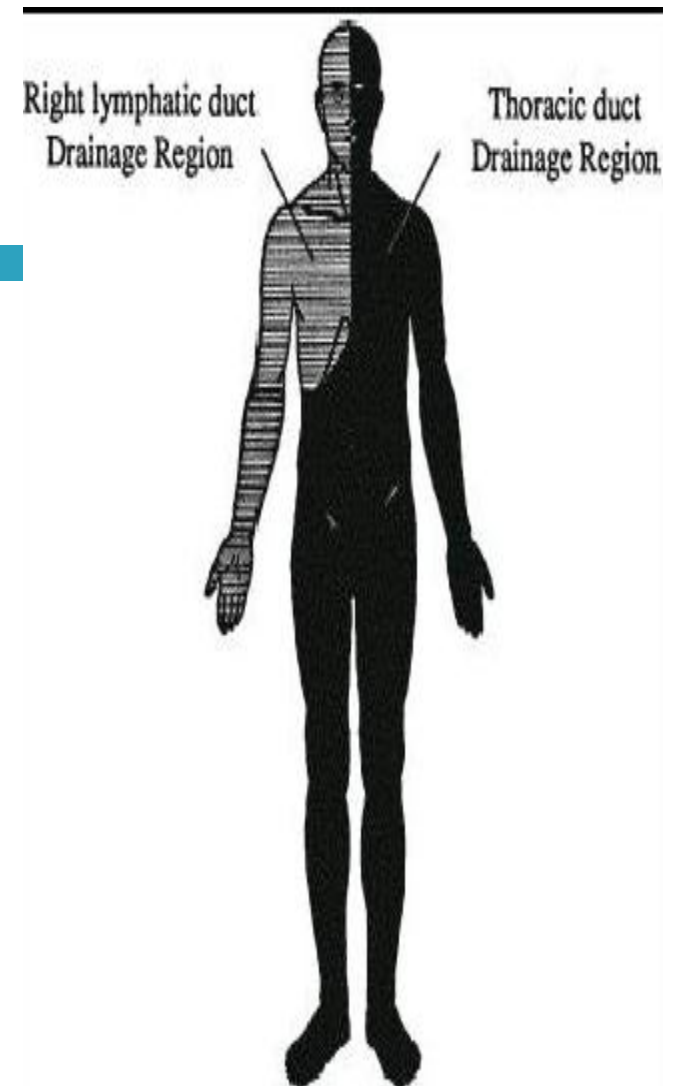
formed by lymphatic vessels uniting  
large tubes  
empty their lymph into lymphatic ducts

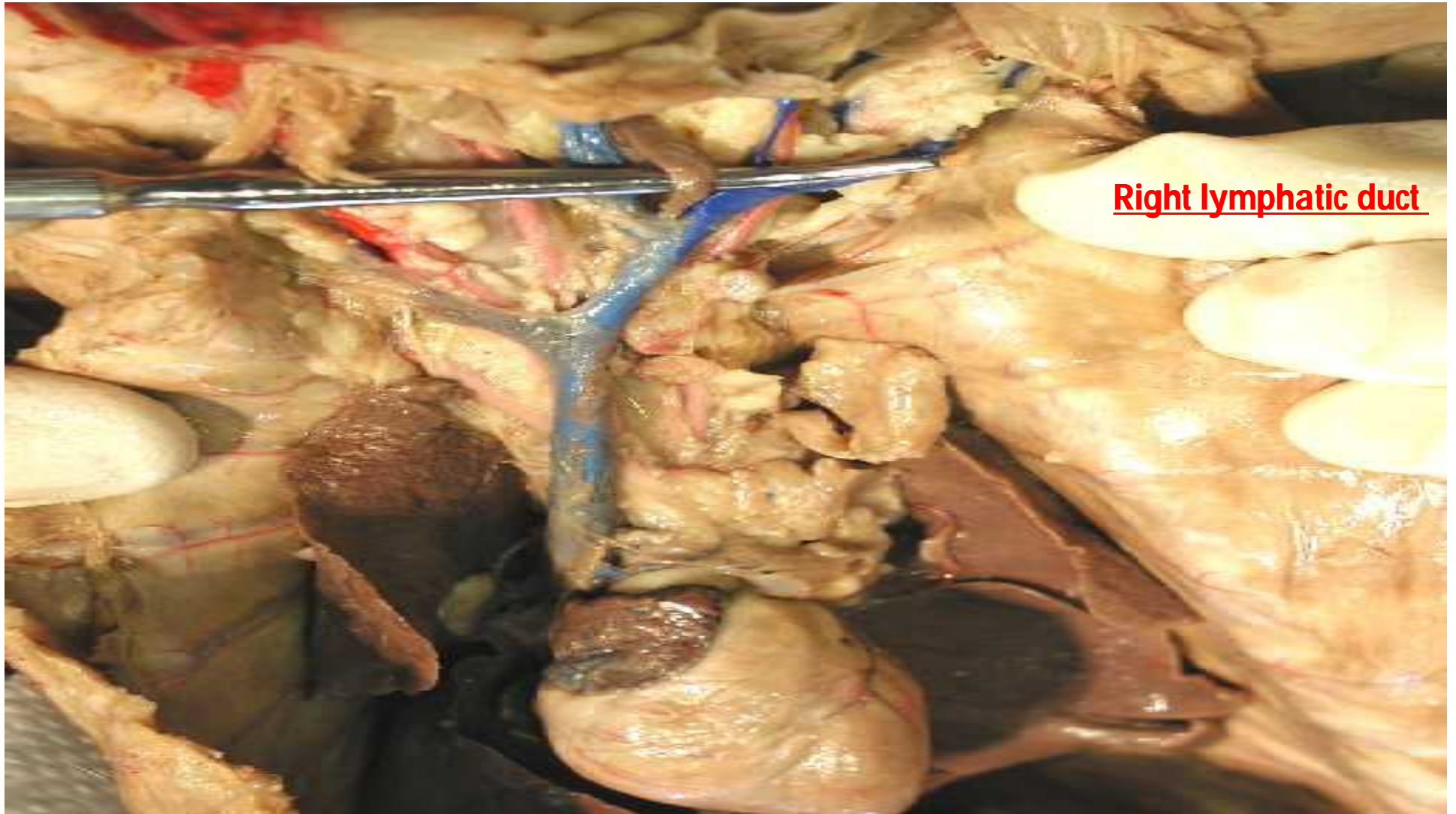- Lymphatic trunks are formed by the union of the largest collecting ducts
- Major trunks include:
  - ▣ Paired lumbar, bronchomediastinal, subclavian, and jugular trunks
  - ▣ A single intestinal trunk



# Lymphatic Trunks

- Lymph is delivered into one of two large trunks
  - ▣ **Right lymphatic duct** – drains the right upper arm and the right side of the head and thorax
  - ▣ **Thoracic duct** – arises from the cisterna chyli and drains the rest of the body






Right lymphatic duct

# Drainage

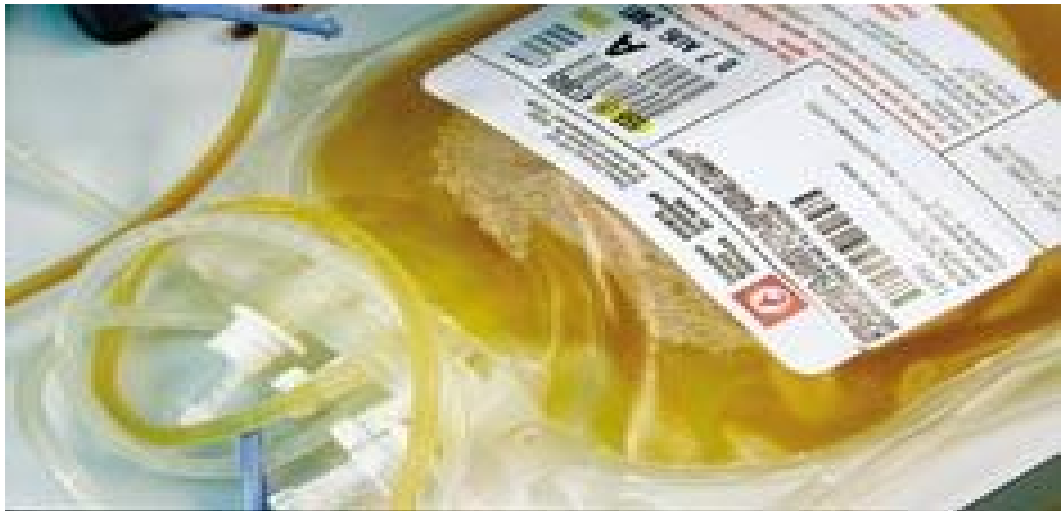- The right duct drains lymph fluid from:
  - ▣ the upper right section of the trunk, (right thoracic cavity, via the right bronchomediastinal trunk),
  - ▣ the right arm (via the right subclavian trunk),
  - ▣ and right side of the head and neck (via the right jugular trunk),
  - ▣ also the lower lobe of the left lung.
- All other sections of the human body are drained by the thoracic duct.

- 
- From lymphatic capillaries, lymph flows through progressively larger lymphatic vessels to eventually reenter blood at the junction of the internal jugular and subclavian veins.

# Components of the Lymphatic System

A. Lymph – fluid collected in lymph vessels

Clear straw colored fluid – same basic component as plasma

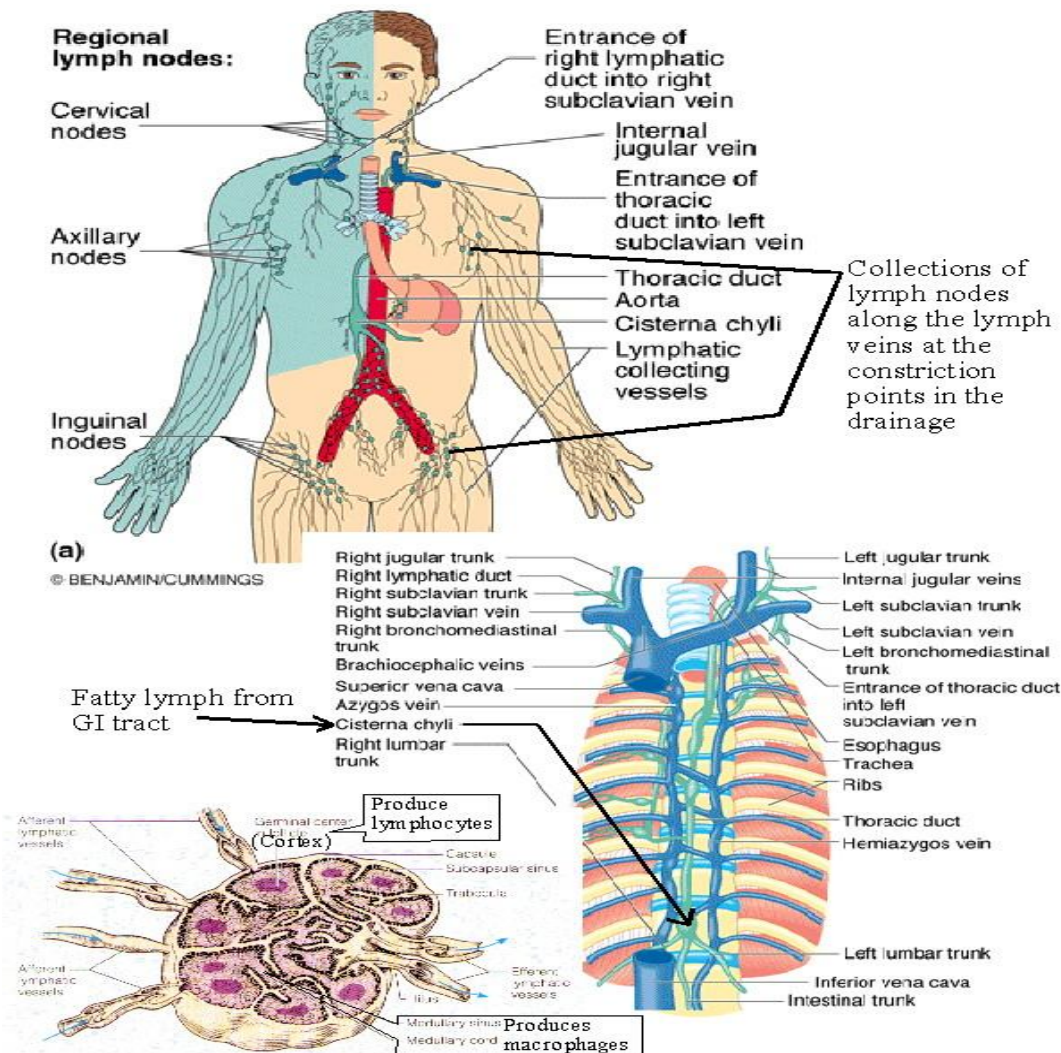




# The Lymphatic Pump

- Although there is no muscular pumping organ connected with the lymphatic vessels to force lymph onward as the heart forces blood, still lymph moves slowly and steadily along its vessels.
  - ▣ Lymph flows through the thoracic duct and reenters the general circulation at the rate of 125 mL/hour.
    - Occurs despite the fact that most of the flow is against gravity or "uphill".
  - ▣ It moves through the system in the right direction because of the large number of valves that permit fluid flow only in one direction.
  - ▣ The movement is due to breathing movements and skeletal muscle contractions.
- Activities that result in central movement or flow are called **lymphokinetic actions**.

- **The mechanism of inspiration, resulting from the descent of the diaphragm, causes intraabdominal pressure to increase as intrathoracic pressure decreases.**
  - ▣ This simultaneously causes pressure to increase in the abdominal portion of the thoracic duct and to decrease in the thoracic portion.
  - ▣ Research has shown that thoracic duct lymph is literally "pumped" into the venous system during inspiration.
    - **The rate of flow of lymph into venous circulation is proportional to the depth of inspiration.**
  - ▣ The total volume of lymph that enters the central veins during a given time period depends on both the depth of inspiration and the overall breathing rate.
- Contracting skeletal muscles also exert pressure on the lymphatics to push the lymph forward.
- a. During exercise, lymph flow may increase as much as 10-15x.
- Other pressure generating factors:
  - ▣ Arterial pulsations
  - ▣ Postural changes
  - ▣ Passive compression (massage) of the body soft tissues.



The lymphatic veins flow into one of two lymph ducts.

•The right lymph duct drains the right arm, shoulder area, and the right side of the head and neck.

•The left lymph duct, or thoracic duct, drains everything else, including the legs, GI tract and other abdominal organs, thoracic organs, and the left side of the head and neck and left arm and shoulder.

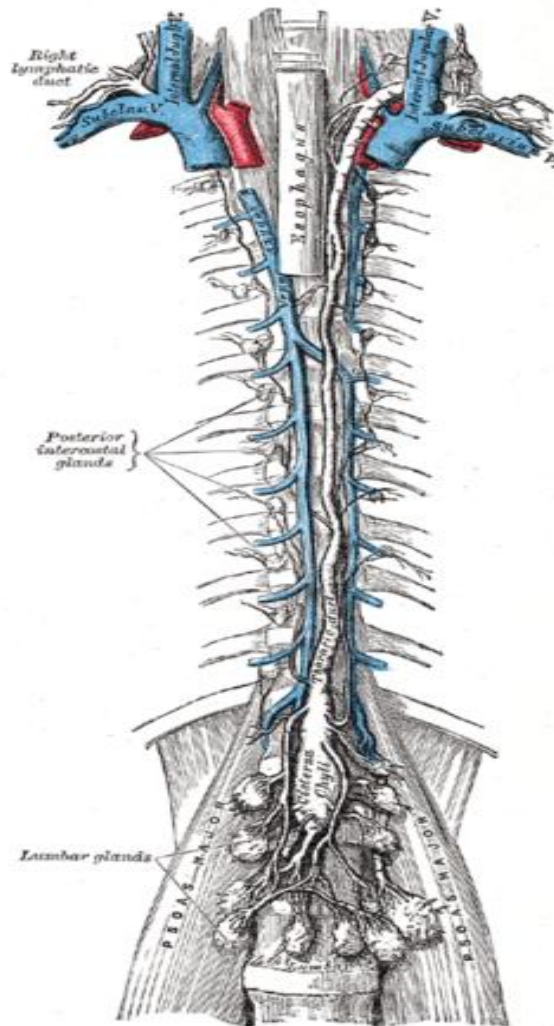
These ducts then drain into the subclavian veins on each side where they join the internal jugular veins to form the brachiocephalic veins.

Lymph nodes lie along the lymph veins successively filtering lymph.

Afferent lymph veins enter each node, efferent veins lead to the next node becoming afferent veins upon reaching it

## Right Lymphatic Duct

- about 0.5 inches (1.5 cm) in length
- receives lymph from upper right quadrant
- empties into the right subclavian vein



In adults, the thoracic duct is typically 38-45cm in length and an average diameter of about 5mm.

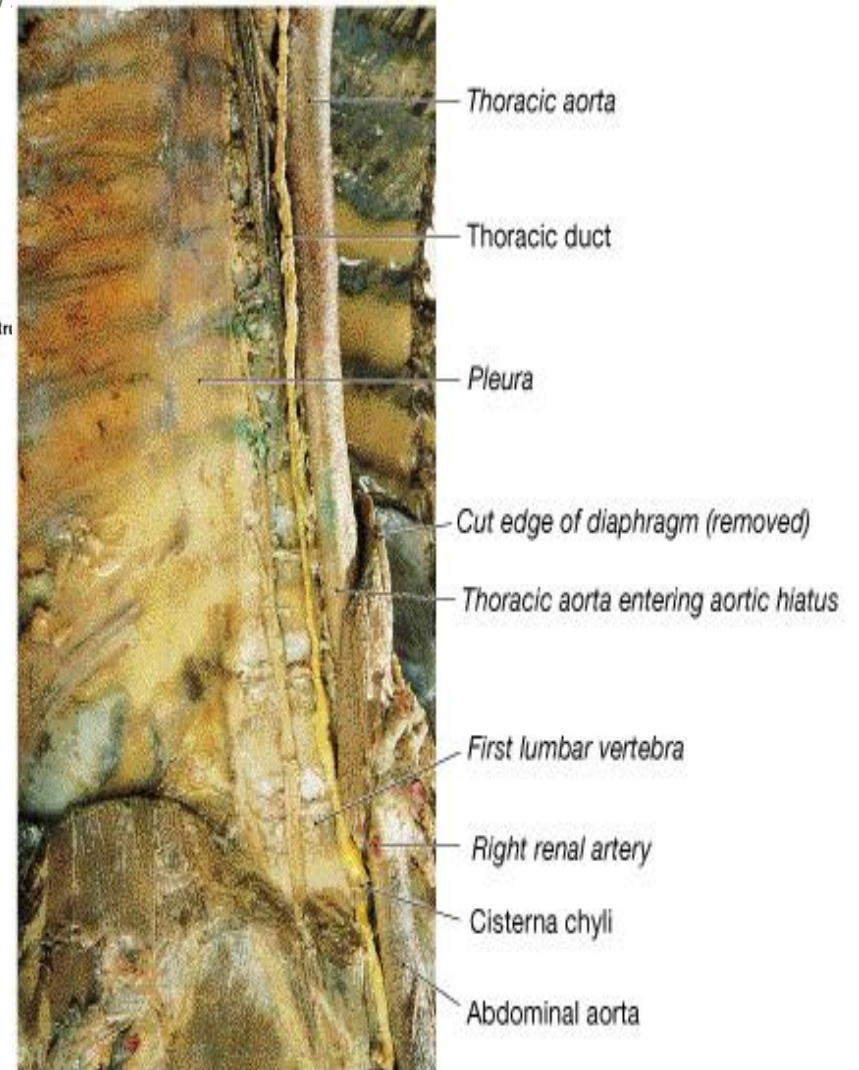
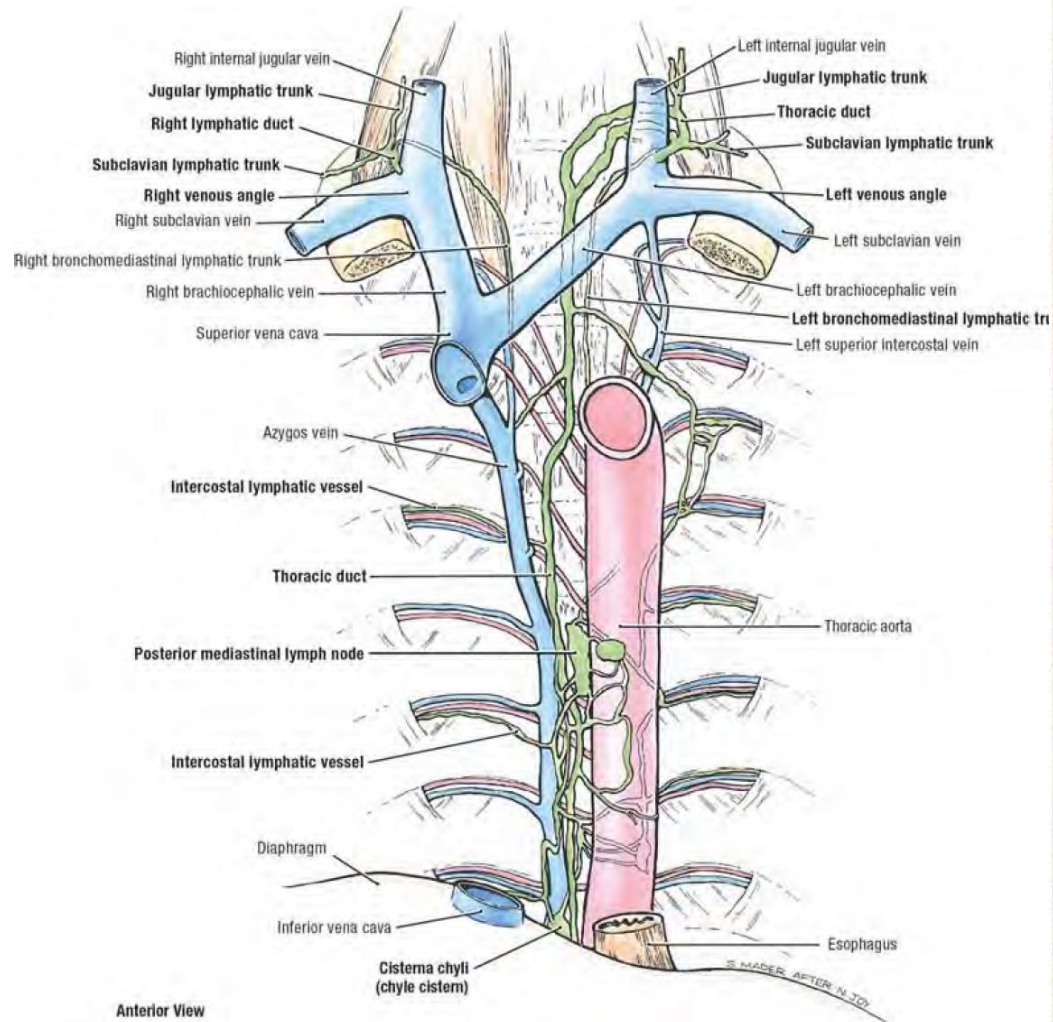
It usually starts from the level of the second lumbar vertebra and extends to the root of the neck.

It originates in the abdomen from the confluence of the right and left lumbar trunk and the intestinal trunk, forming a significant pathway upward called the cisterna chyli.

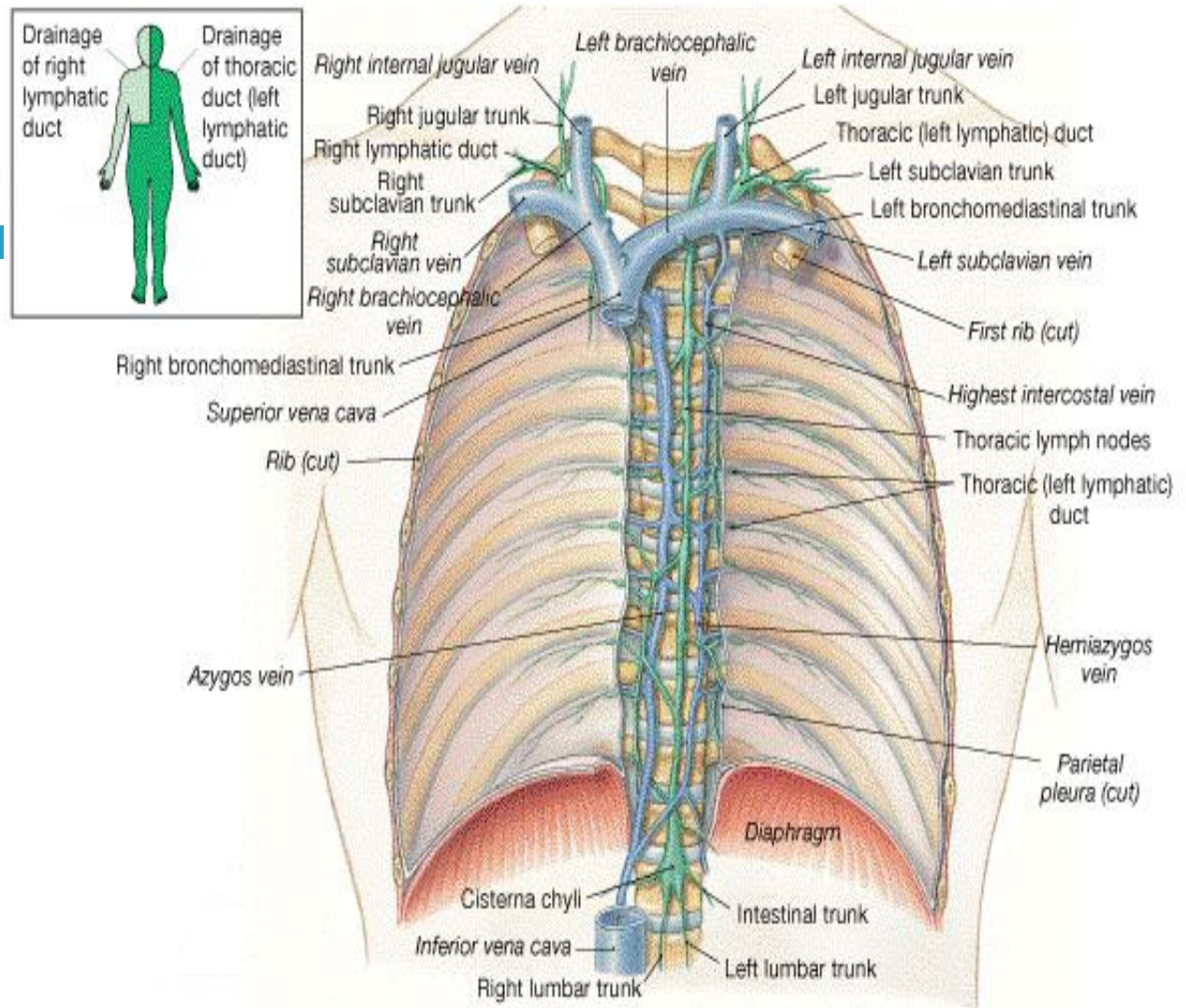
It extends vertically in the chest and curves posteriorly to the left carotid artery and left internal jugular vein at the C7 vertebral level to empty into the junction of the left subclavian vein and left jugular vein, below the clavicle, near the shoulders.

It traverses the diaphragm at the aortic aperture and ascends the posterior mediastinum between the descending thoracic aorta (to its left) and the azygos vein (to its right).



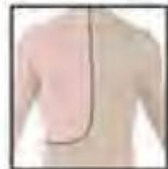

# Main Channels of Lymphatics

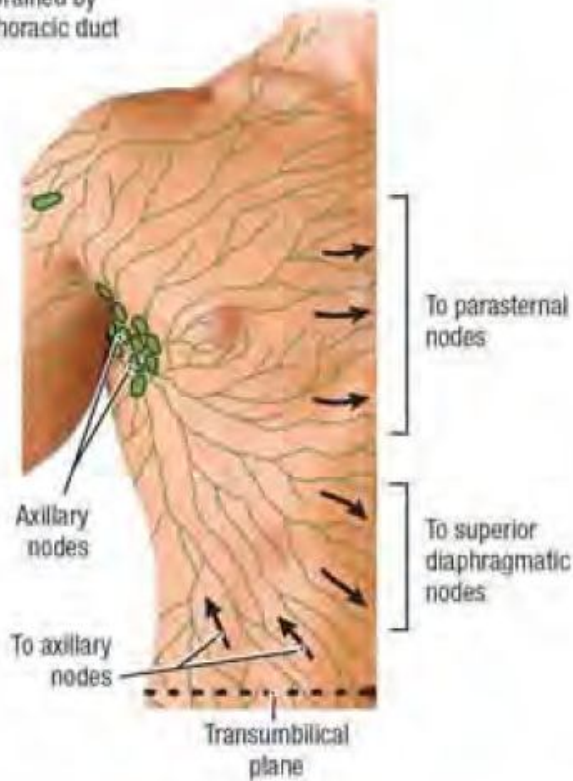




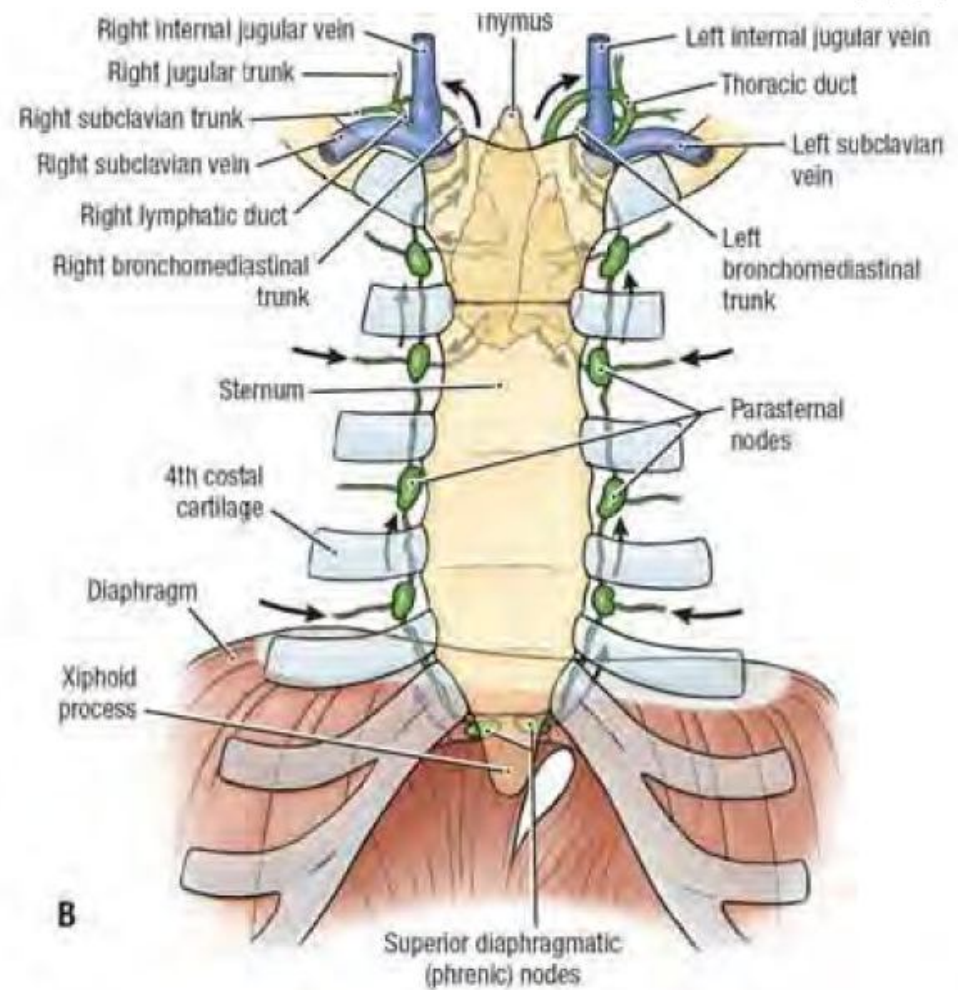
Areas of thorax (superficial and deep):



- Drained by right lymphatic duct
- Drained by thoracic duct



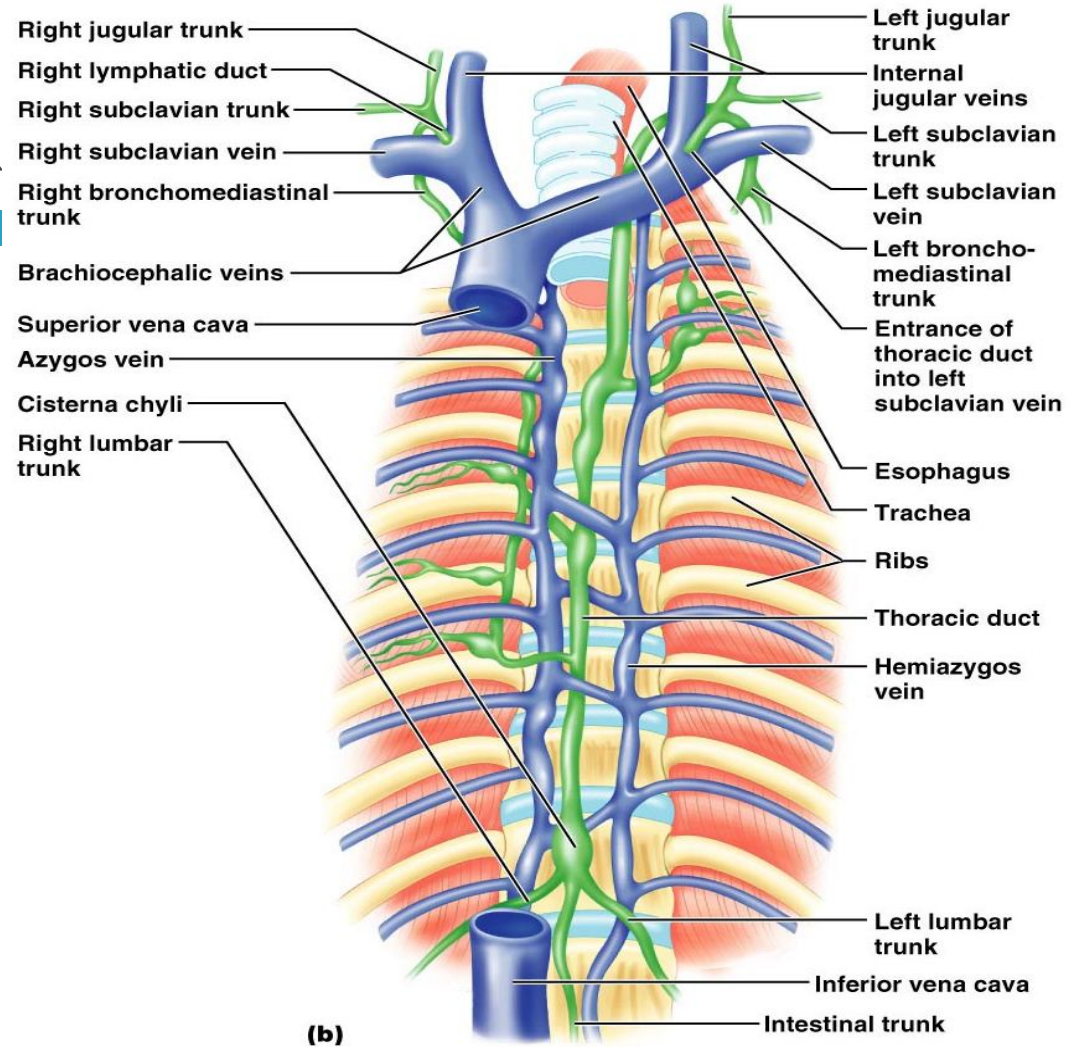
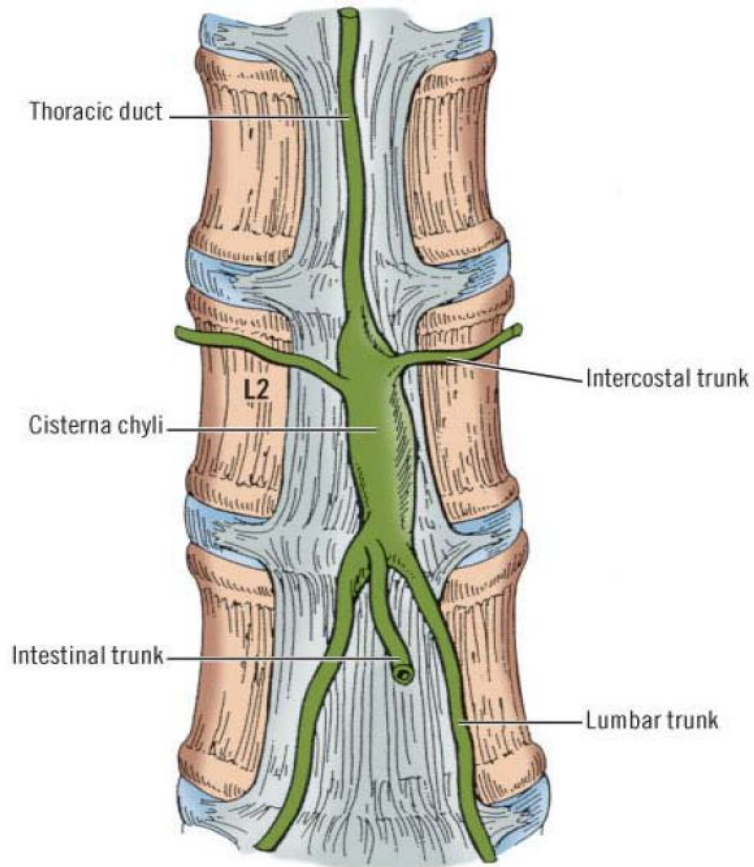
A



B



# Lymphatic Trunk



# Thoracic Duct

## (left lymphatic duct)

---

- about 15-18 inches (38-45 cm) in length
- begins as a dilation called the cisterna chyli
- main collecting duct of lymphatic system
- receives lymph from lower body and upper left quadrant
- empties into the left subclavian vein

## Lymphatic Ducts

- **Lymph empties into two conducting ducts:**
  - the thoracic duct (left lymphatic duct)
  - the right lymphatic duct

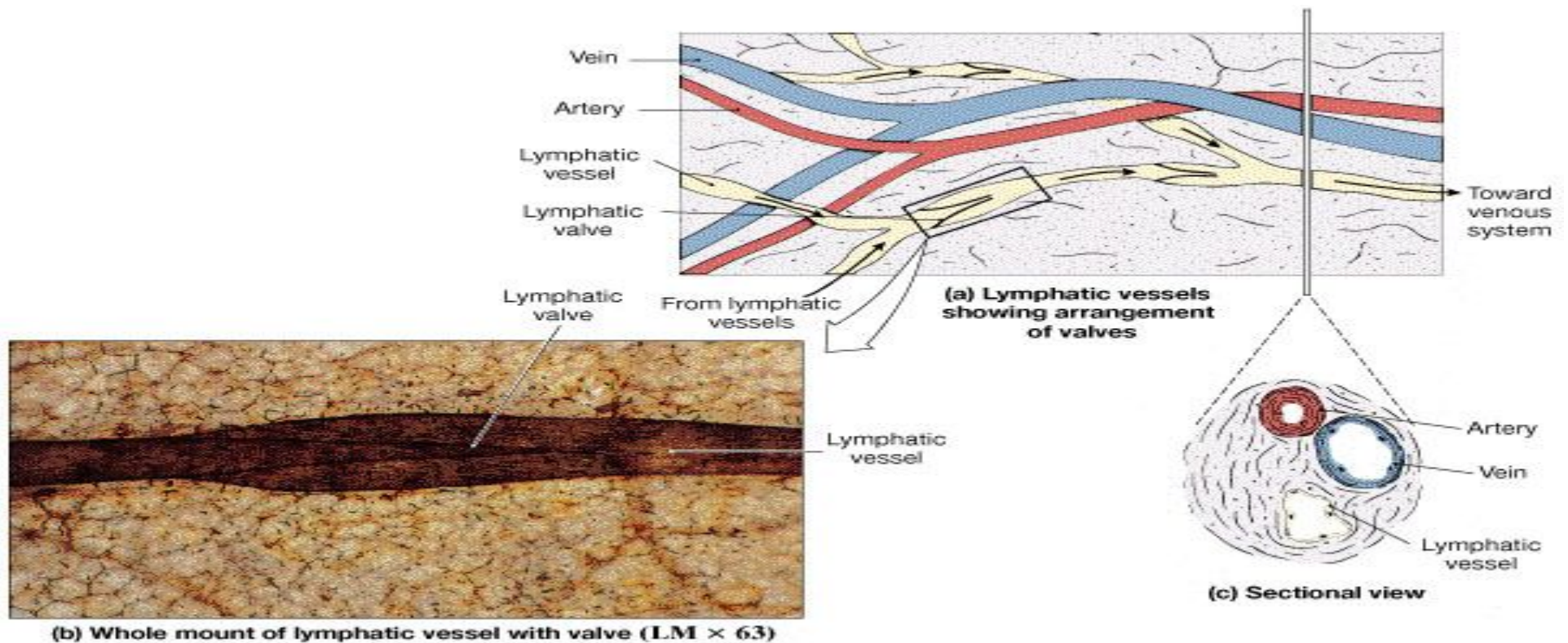
Lymph from these ducts enters the blood stream via the left subclavian vein and the right subclavian vein

# Cisterna Chyli

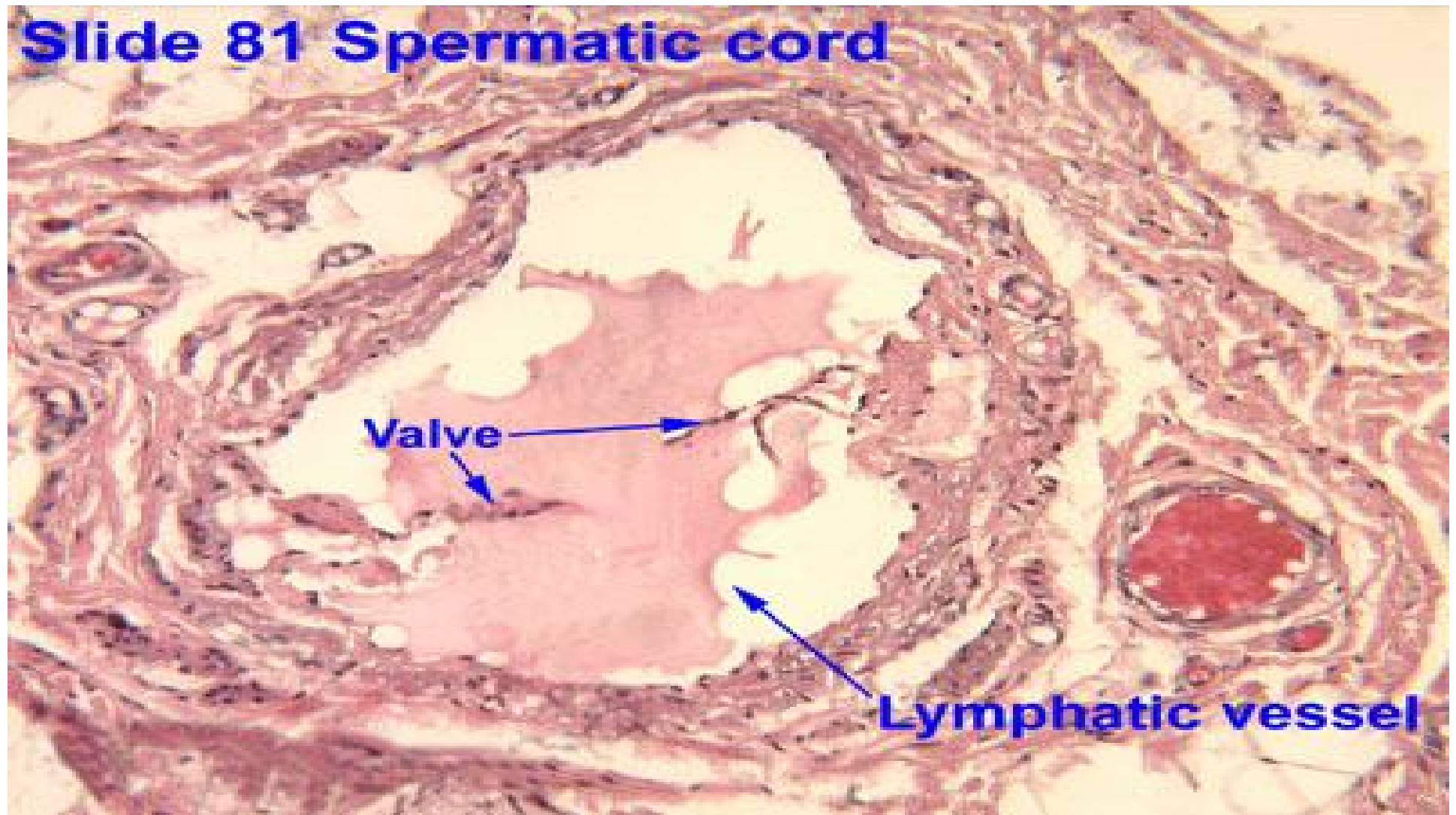
---

- ❑ large lymph vessel
- ❑ formed by the union of lymph vessels from lower body
- ❑ located anterior to the second lumbar vertebra
- ❑ continues superiorly as thoracic duct

# Lymphatic Vessels

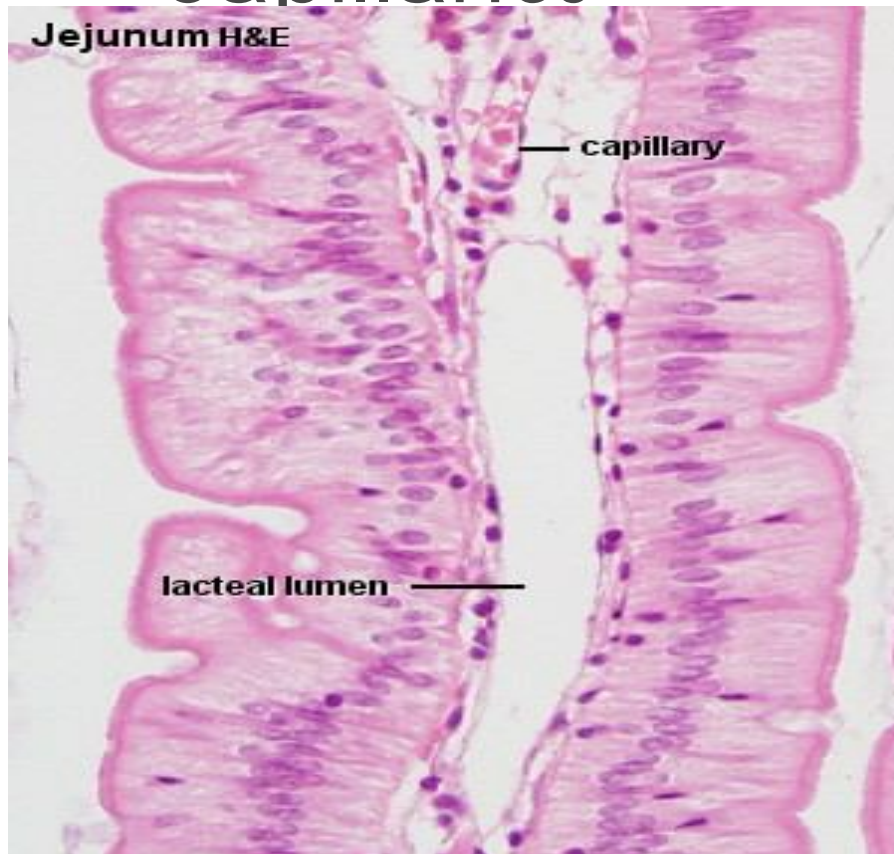


## Slide 81 Spermatic cord





# Lymphatic Capillaries

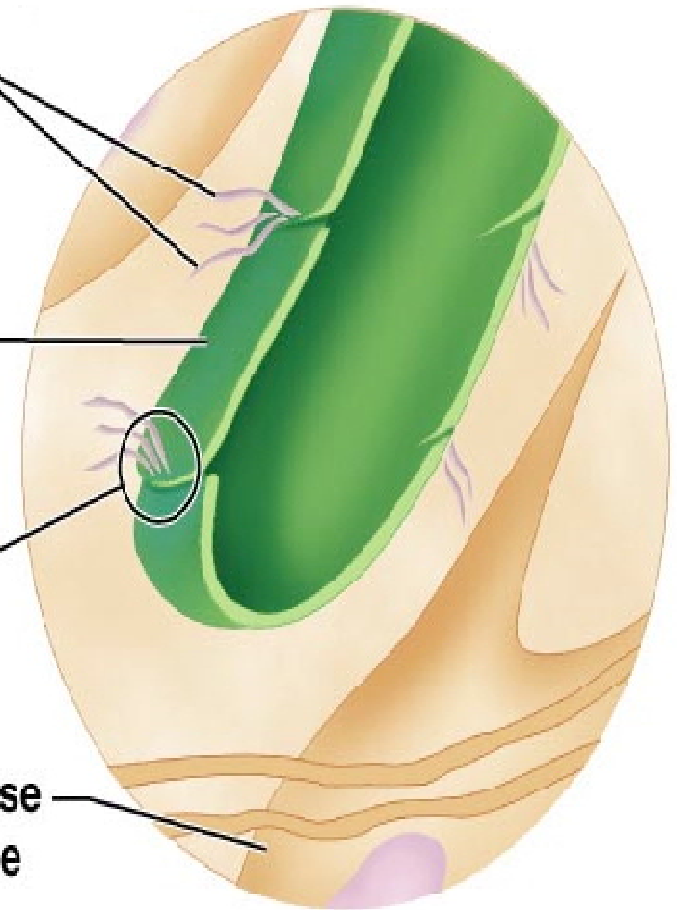


Filaments  
anchored to  
connective  
tissue

Endothelial  
cell

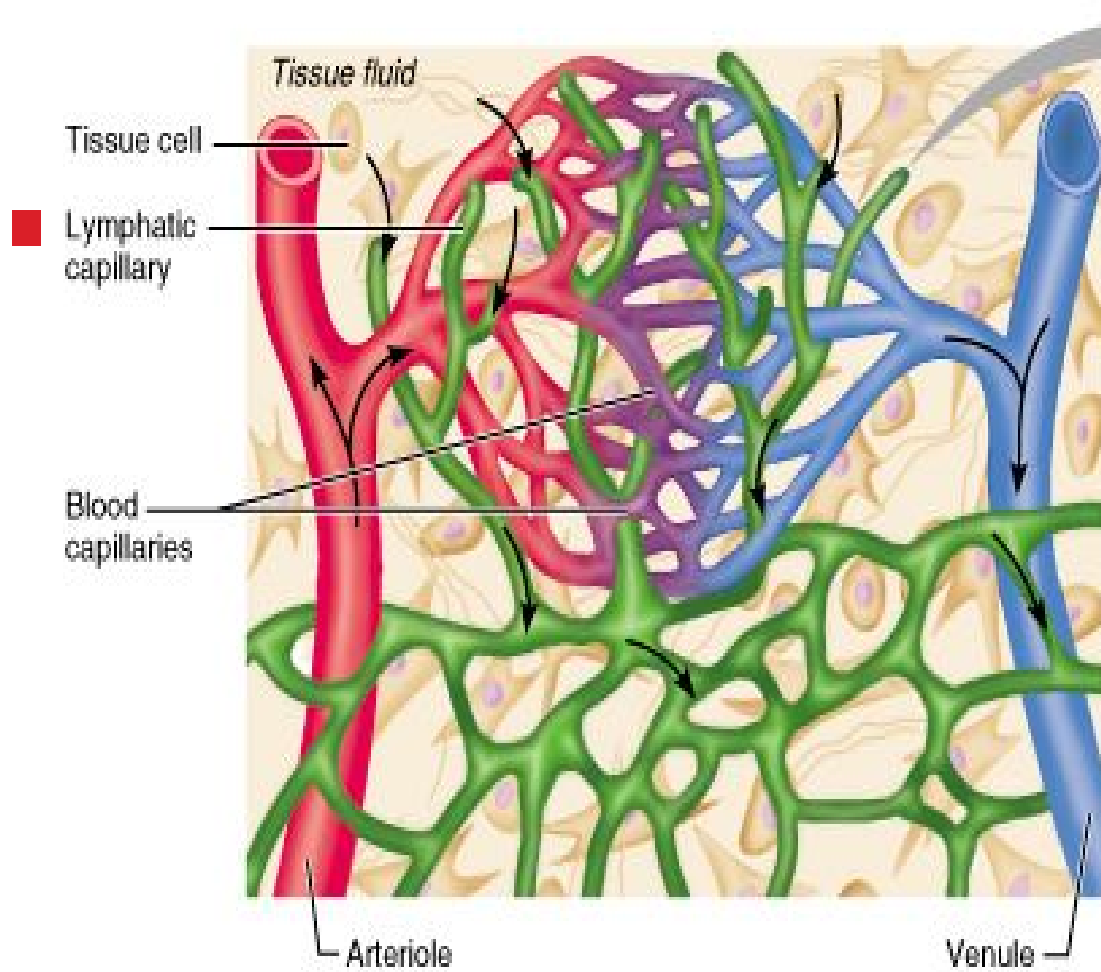
Flaplike  
minivalve

Fibroblast in loose  
connective tissue

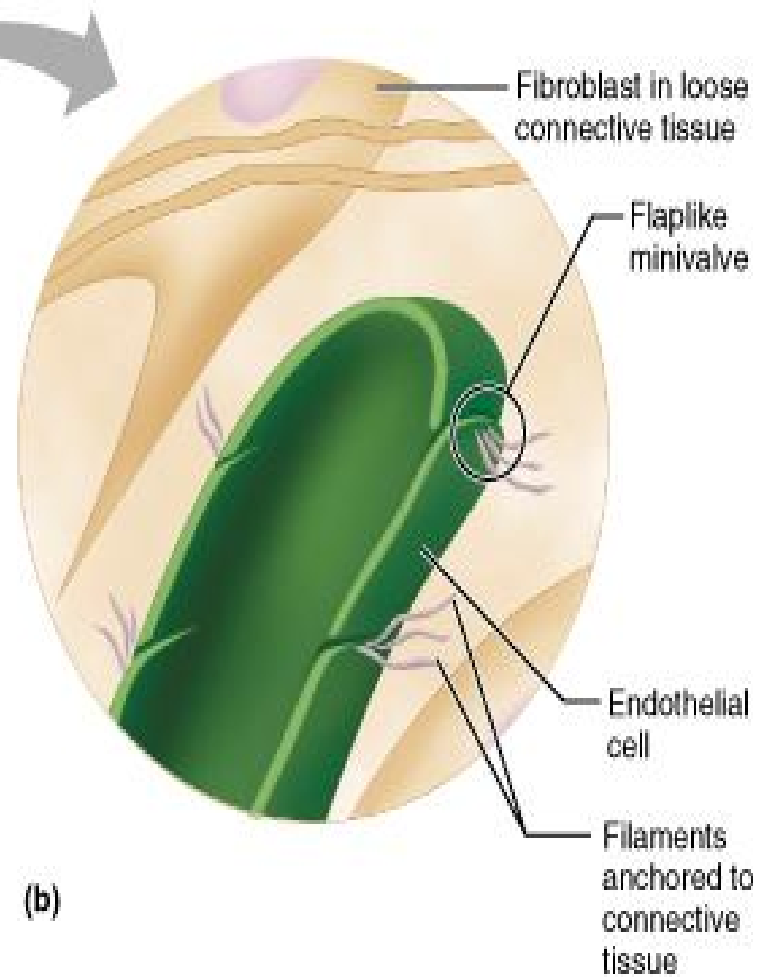


(b)



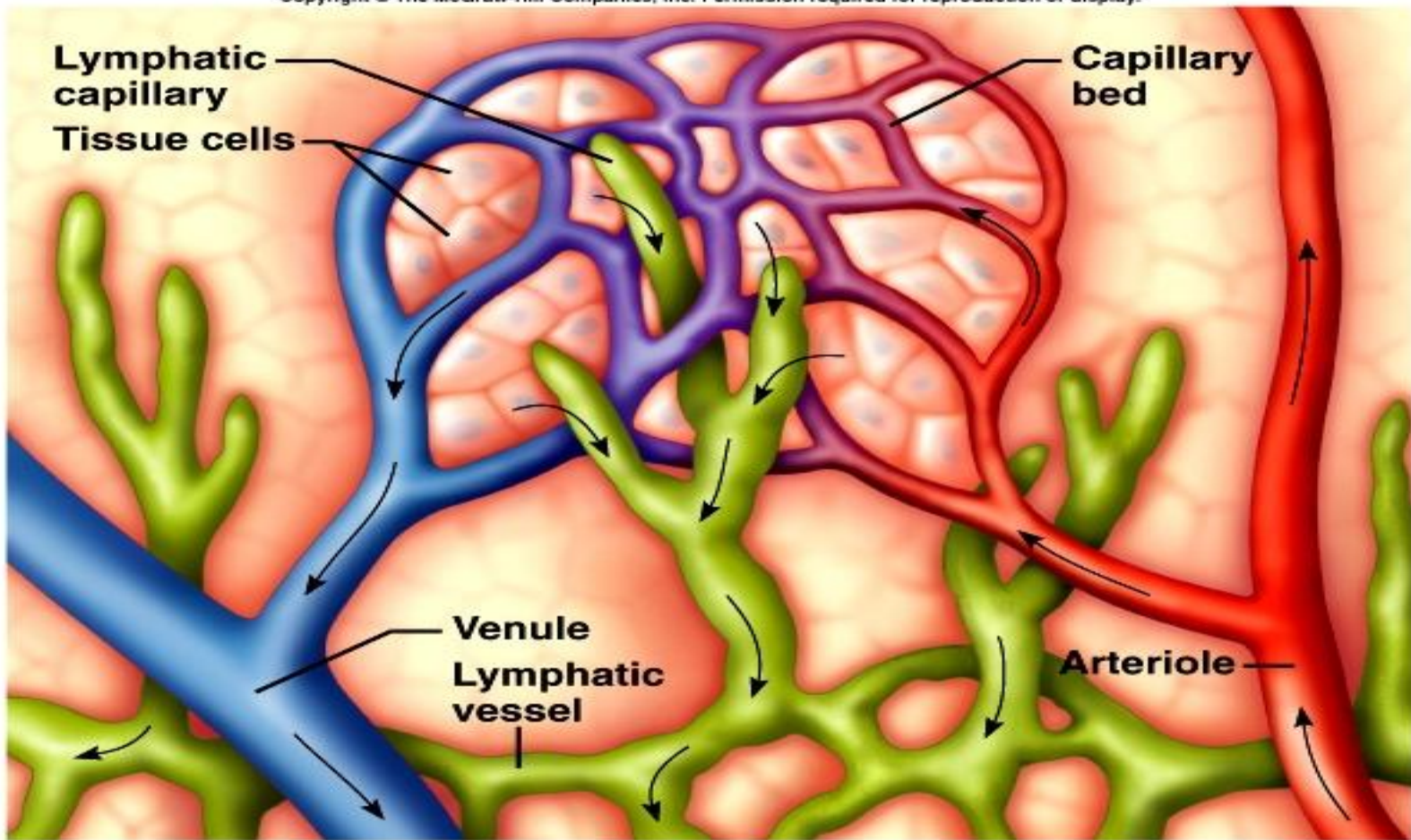


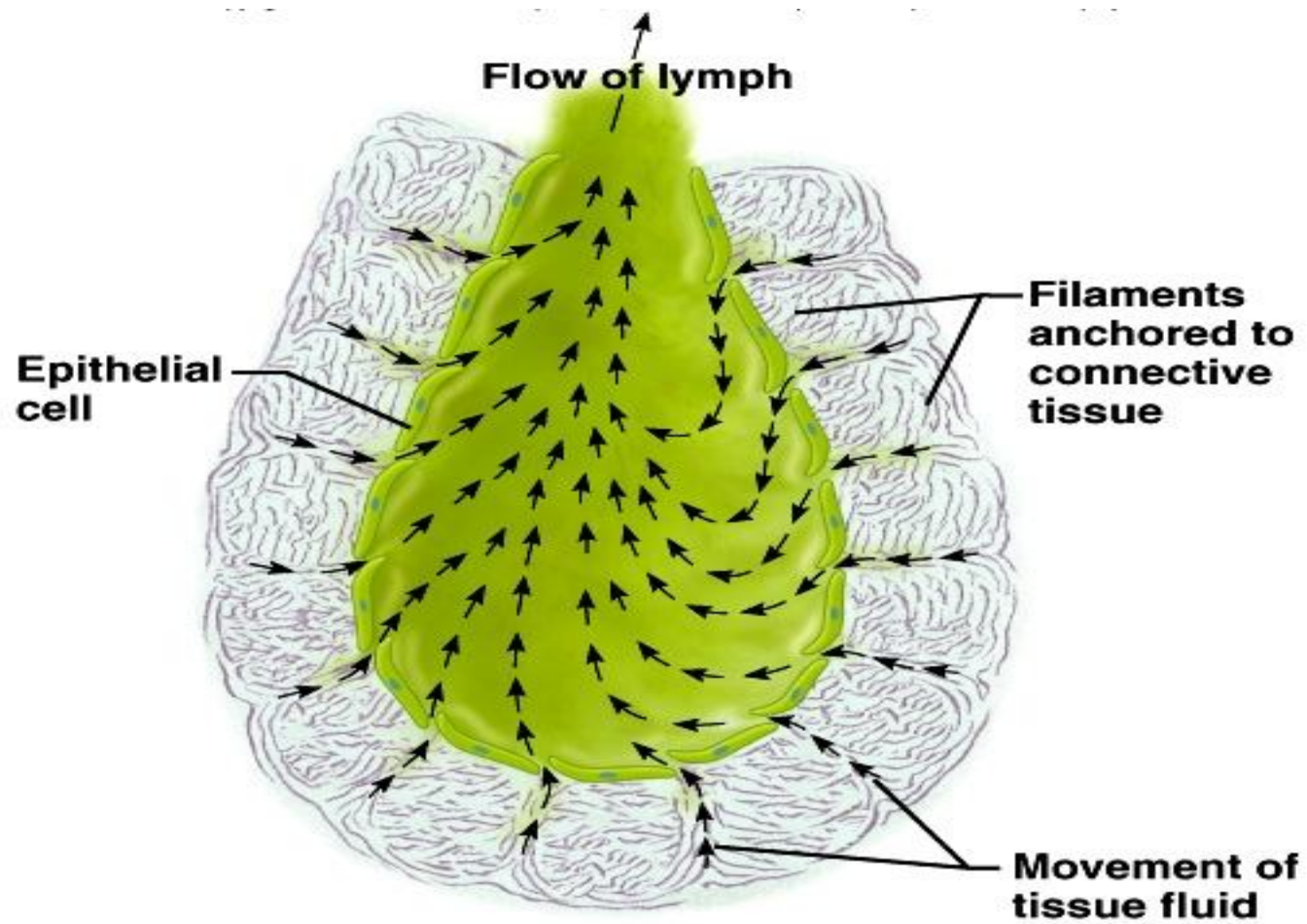
(a)



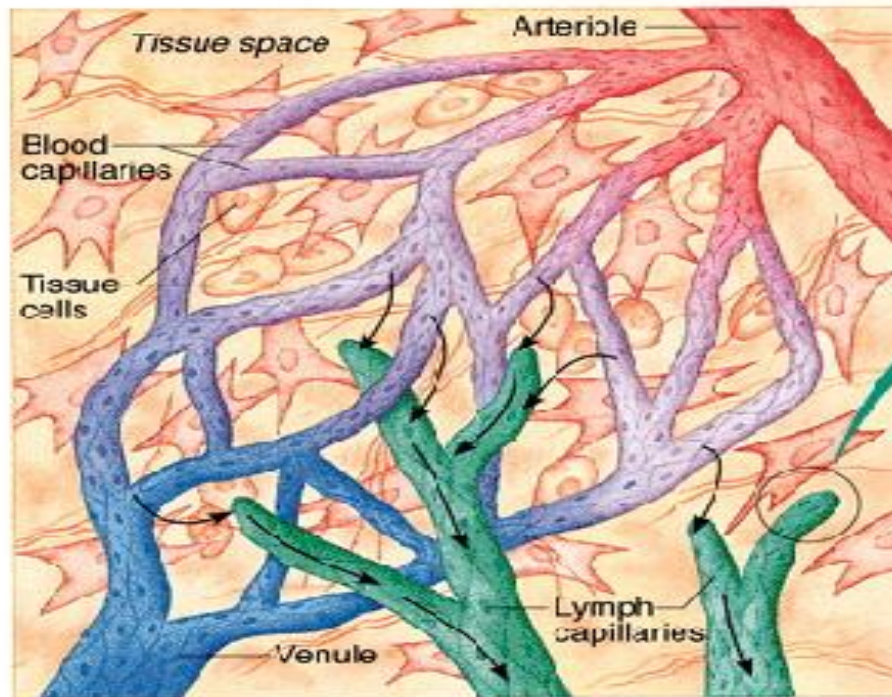
(b)

Copyright © The McGraw-Hill Companies, Inc. Permission required for reproduction or display.

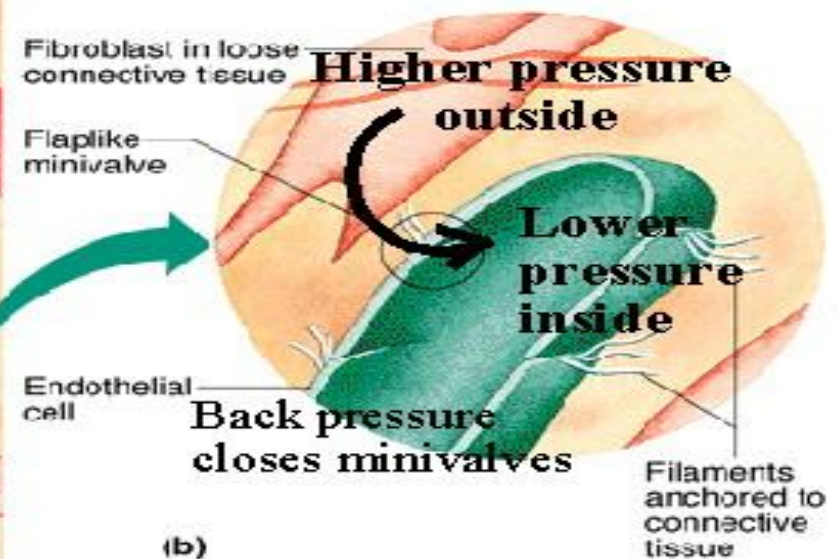






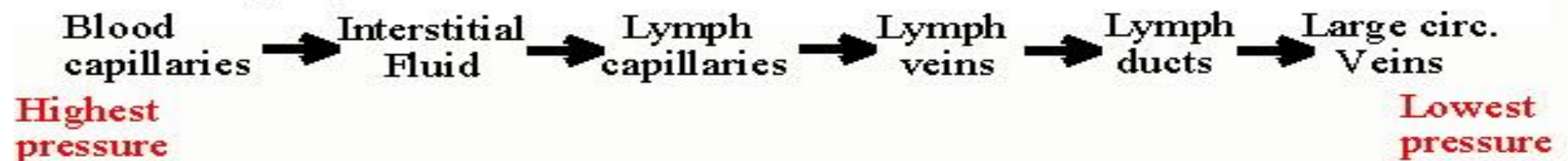


(a)



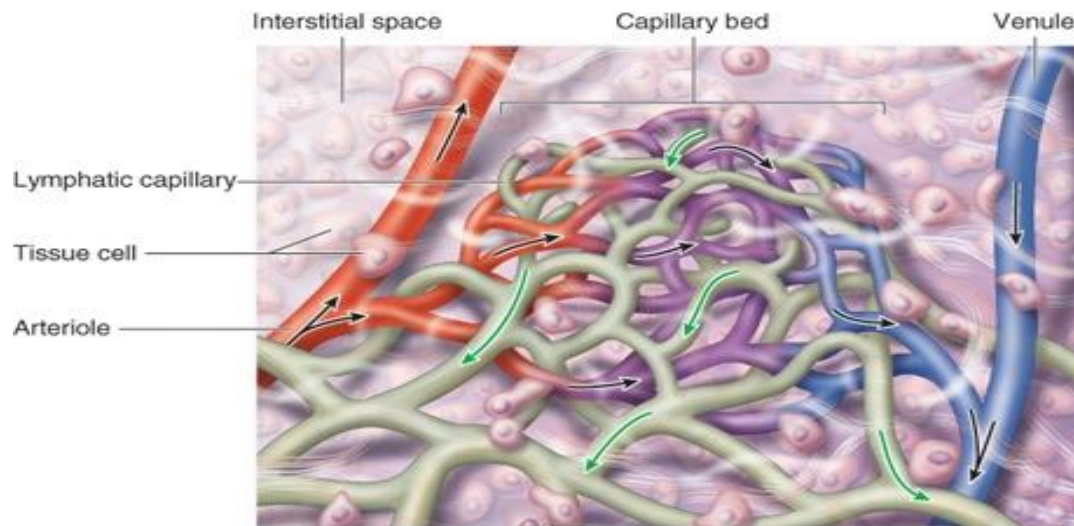
(b)

### Lymphokinetic Motion and Pressure Gradient

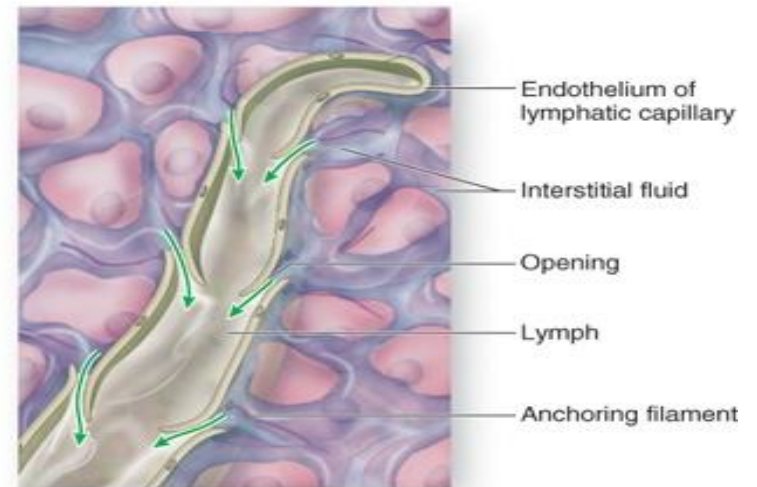


# Lymphatic Capillaries

- During inflammation, lymph capillaries can absorb:
  - ▣ Cell debris
  - ▣ Pathogens
  - ▣ Cancer cells
- Cells in the lymph nodes cleanse and “examine” this debris
- Lacteals – specialized lymph capillaries present in intestinal mucosa
  - ▣ Absorb digested fat and deliver chyle to the blood



(a)



(b)

<b>Table 24.2 Lymphatic Structures and Organs</b>			
<b>Component</b>	<b>Structure or Organ<sup>1</sup></b>	<b>Functions</b>	<b>Location</b>
Lymphatic nodules	Structure	Filter and attack antigens	Throughout body
MALT (mucosa-associated lymphatic tissue)	Structure	Filter and attack antigens in air, food, or urine	Within walls of GI, respiratory, genital, and urinary tracts
Tonsils	Structure	Protect against inhaled and ingested materials	Within pharynx
Thymus	Organ	Site of T-lymphocyte maturation and differentiation; stores maturing lymphocytes	Superior mediastinum (in adults); anterior and superior mediastinum (in children)
Lymph nodes	Organ	Filter lymph; mount immune response (if necessary)	Throughout body; frequently in clusters in the axillary, inguinal, and cervical regions
Spleen	Organ	Filters blood and recycles aged erythrocytes and platelets; serves as a blood reservoir; houses lymphocytes; mounts immune response to foreign antigens in the blood	In left upper quadrant of abdomen, near 9th–11th ribs and inferior to diaphragm

<sup>1</sup>A lymphatic structure is unencapsulated or has an incomplete connective tissue capsule, while a lymphatic organ has a complete connective tissue capsule encircling it.

# Lymphatic Capillaries

---

- Similar to blood capillaries, with modifications:
  - ▣ *Very permeable*
  - ▣ *Loosely joined endothelial minivalves*
  - ▣ *Withstand interstitial pressure and remain open*
- **The minivalves function as one-way gates that:**
  - ▣ *Allow interstitial fluid to enter lymph capillaries*
  - ▣ *Do not allow lymph to escape from the capillaries*



# Lymphatic Collecting Vessels

---

- ❑ Have the same three tunics as veins
- ❑ Have thinner walls, with more internal valves
- ❑ Anastomose more frequently
- ❑ Collecting vessels in the skin travel with superficial veins
- ❑ Deep vessels travel with arteries
- ❑ Nutrients are supplied from branching vasa vasorum

# Lymph Transport

---

- ❑ The lymphatic system lacks a pumping organ
- ❑ Vessels are low-pressure conduits
- ❑ Uses the same methods as veins to propel lymph:
  - ▣ Pulsations of nearby arteries
  - ▣ Contractions of smooth muscle in the walls of the lymphatics

# Lymphoid Cells

---

- Lymphocytes are the main cells involved in the immune response
- Two main varieties:
  - ▣ T cells
  - ▣ B cells

# Other Lymphoid Cells

---

- ❑ Macrophages – phagocytize foreign substances and help activate T cells
- ❑ Dendritic cells – spiny-looking cells with functions similar to macrophages
- ❑ Reticular cells – fibroblast-like cells that produce a stroma, or network, that supports other cell types in lymphoid organs



# Lymph Nodes

- ❑ Principal lymphoid organs of the body
- ❑ Embedded in connective tissue and clustered along lymphatic vessels
- ❑ Aggregations of these nodes are found on the surface in inguinal, axillary, and cervical regions of the body

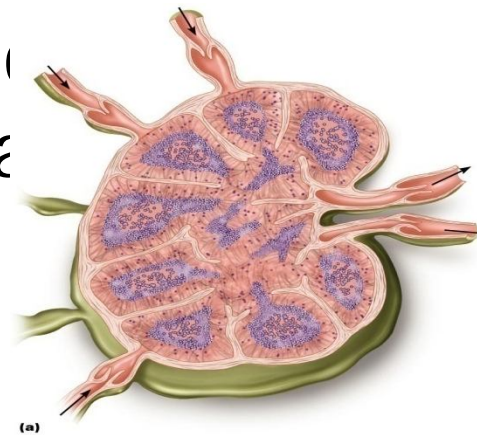
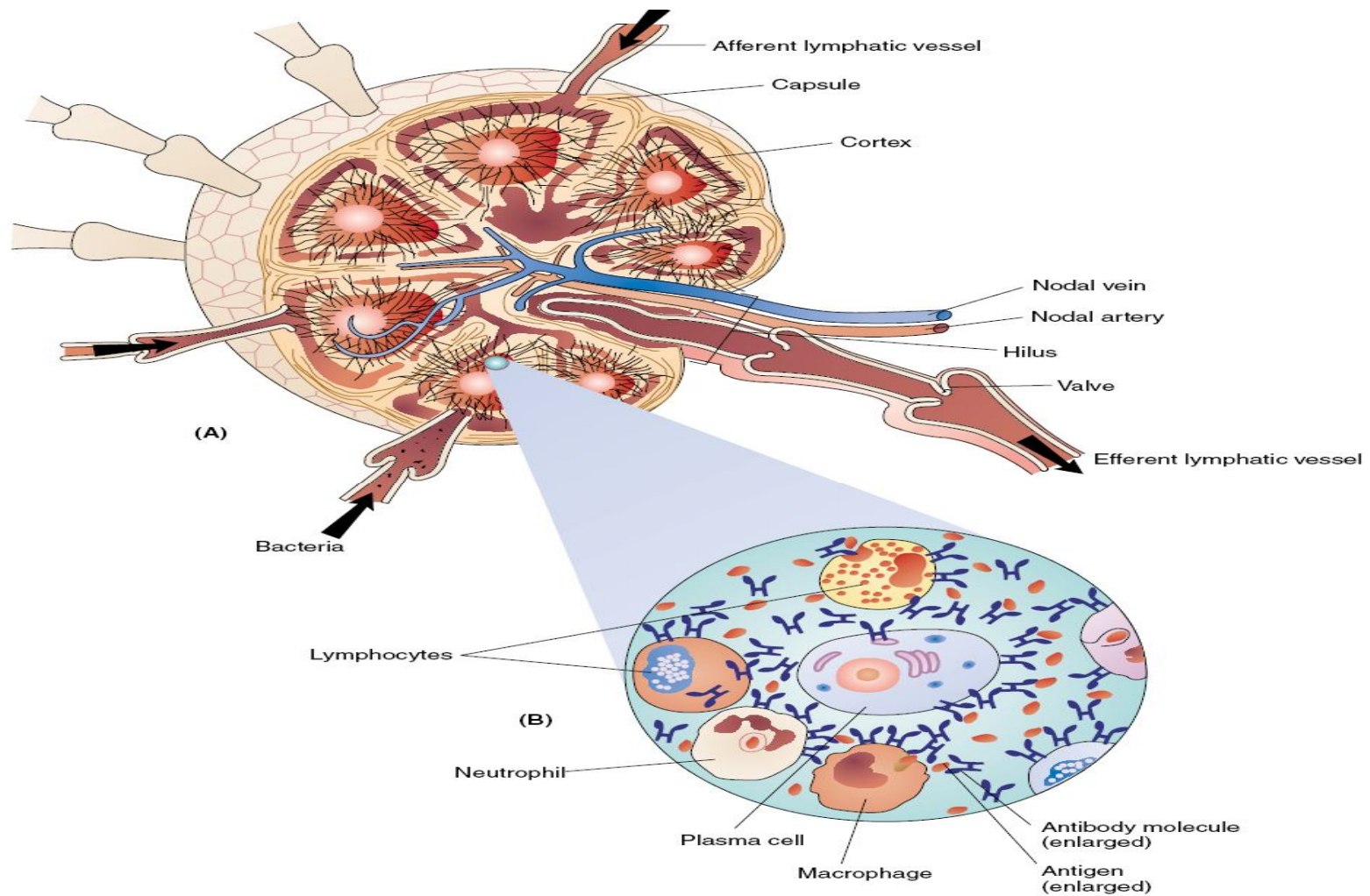


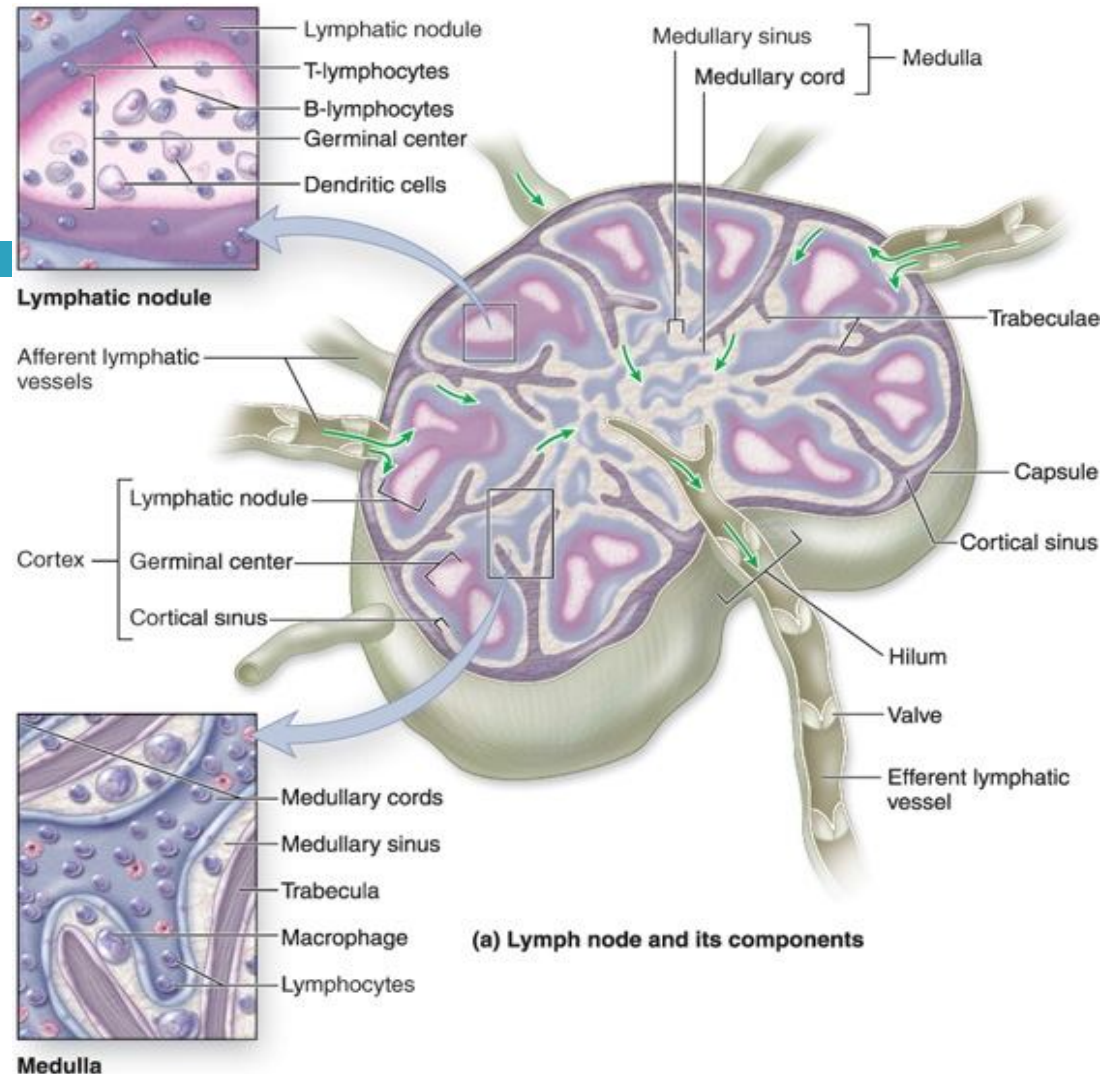
Figure 20.4a



**FIGURE 15-4.** Lymph node. (A) Section through a lymph node, showing the flow of lymph. (B) Microscopic detail of bacteria being destroyed within the lymph node.

# Lymph Nodes

- Two basic functions:
  - ▣ Filtration – macrophages destroy microorganisms and debris
  - ▣ Immune system activation – monitor for antigens and mount an attack against them



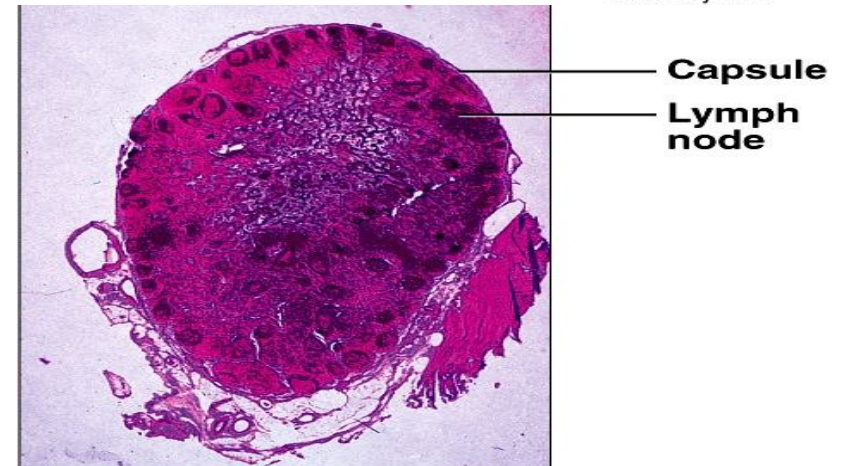
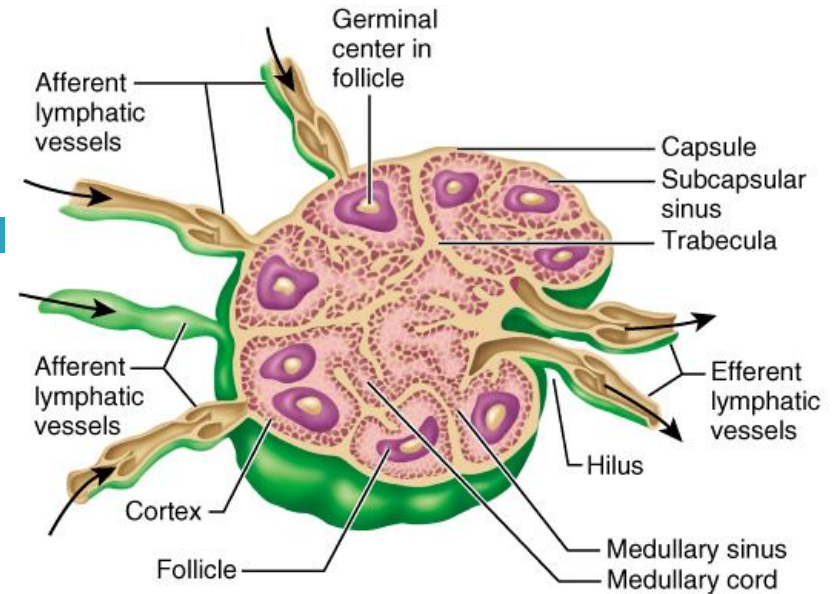
## Lymph Nodes

- oval or bean-shaped
- masses of lymphatic tissue
- aid in defense and white blood cell formation
- located along length of lymphatic vessels
- scattered throughout the body usually in clusters



# Lymph Nodes

- ❑ covered by a capsule
- ❑ contain capsular extensions called trabeculae (form partitions within node)
- ❑ internal to capsule are reticular fibers and fibroblasts
  - form framework of a lymph node
- ❑ **Two main regions of a lymph node:**
  - cortex
  - medulla



# Structure of a Lymph Node

- ❑ Nodes are bean shaped and surrounded by a fibrous capsule
- ❑ Trabeculae extended inward from the capsule and divide the node into compartments
- ❑ Nodes have two histological regions: a cortex and a medulla

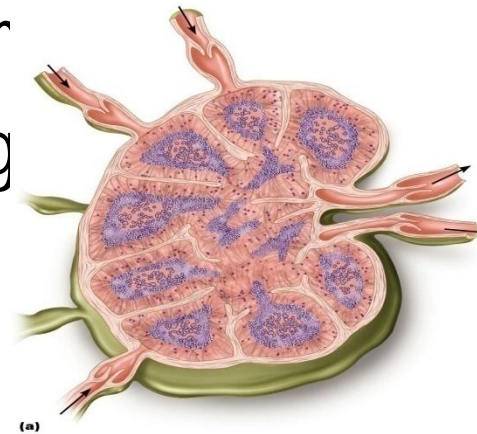


Figure 20.4a

# Structure of a Lymph Node

---

- ❑ Cortex contains follicles with germinal centers, heavy with dividing B cells
- ❑ Dendritic cells nearly encapsulate the follicles
- ❑ Deep cortex houses T cells in transit
- ❑ T cells circulate continuously among the blood, lymph nodes, and lymphatic stream

# Structure of a Lymph Node

---

- ❑ Medullary cords extend from the cortex and contain B cells, T cells, and plasma cells
- ❑ Throughout the node are lymph sinuses crisscrossed by reticular fibers
- ❑ Macrophages reside on these fibers and phagocytize foreign matter

## Structure of a Lymph Node

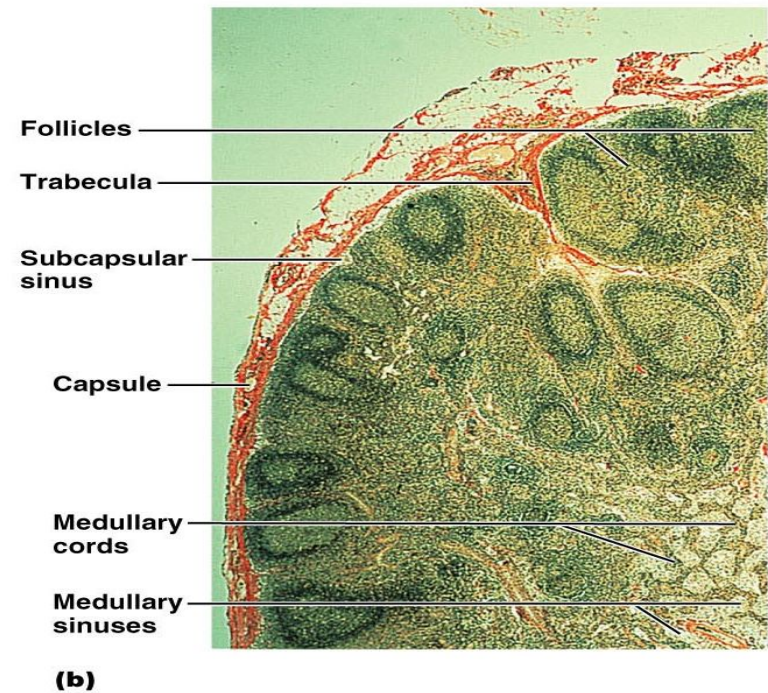
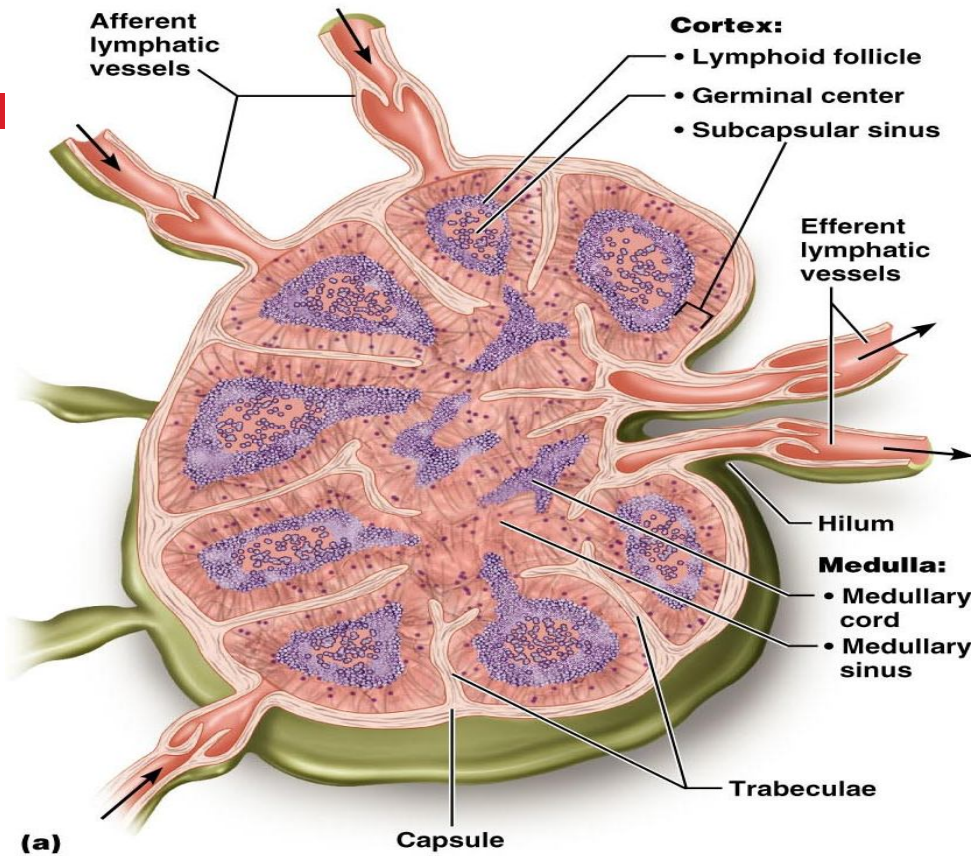


Figure 20.4a, b



# Circulation in the Lymph Nodes

---

- ❑ Lymph enters via afferent lymphatic vessels
- ❑ It then enters a large subcapsular sinus and travels into smaller sinuses
- ❑ It meanders through these sinuses and exits the node at the hilus via efferent vessels
- ❑ Because there are fewer efferent vessels, lymph stagnates somewhat in the node
- ❑ This allows lymphocytes and macrophages time to carry out protective functions

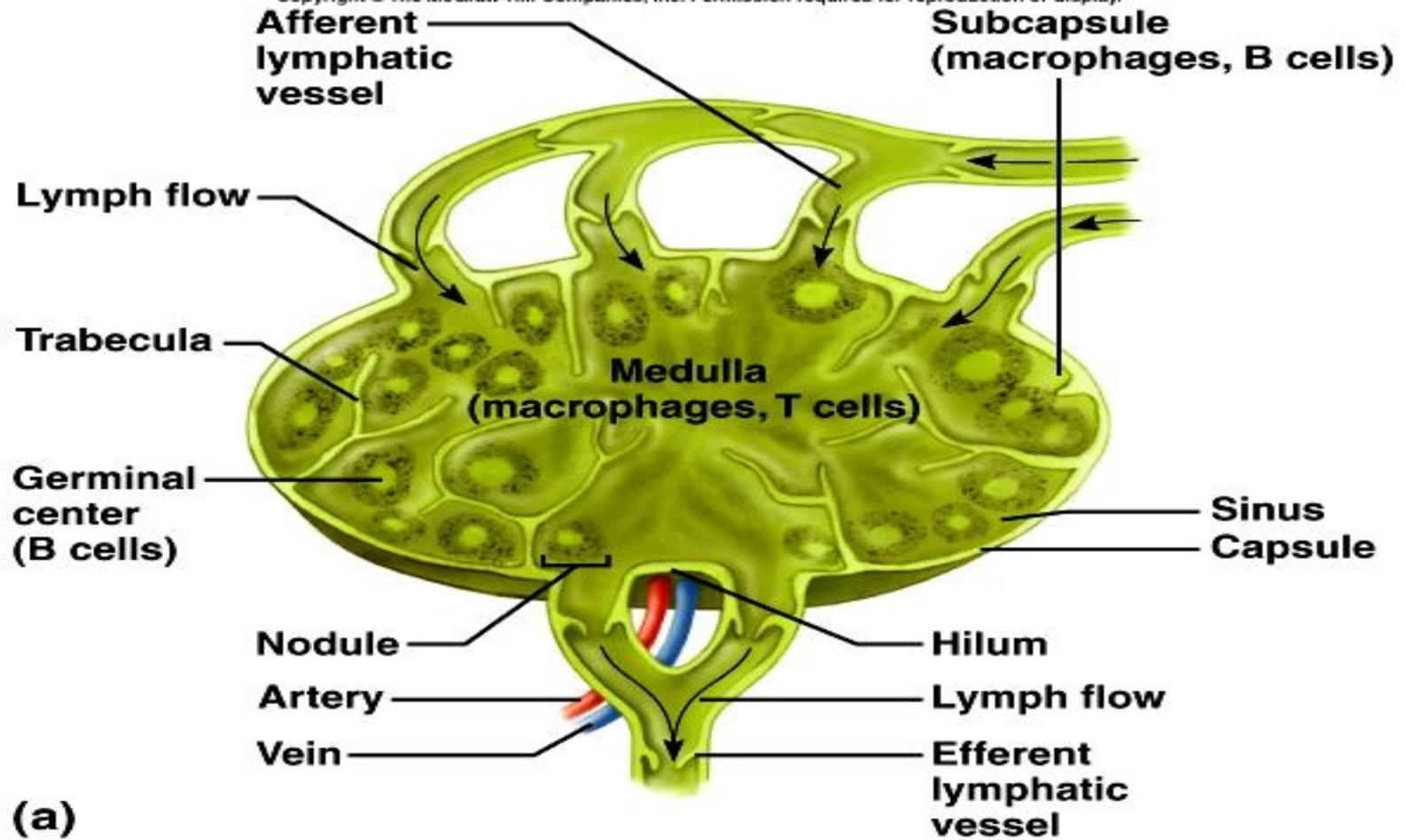
# Lymphatic nodules

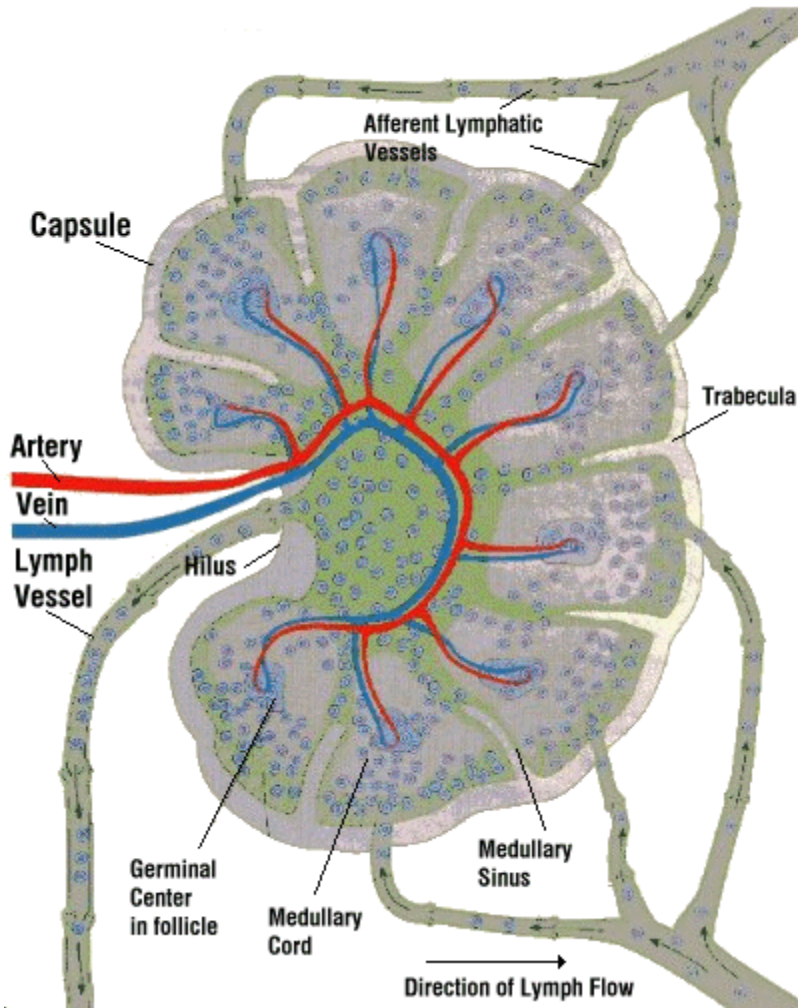
- The **germinal center** is the site of proliferation and differentiation of B-lymphocytes.

**Cell types of the germinal center include :**

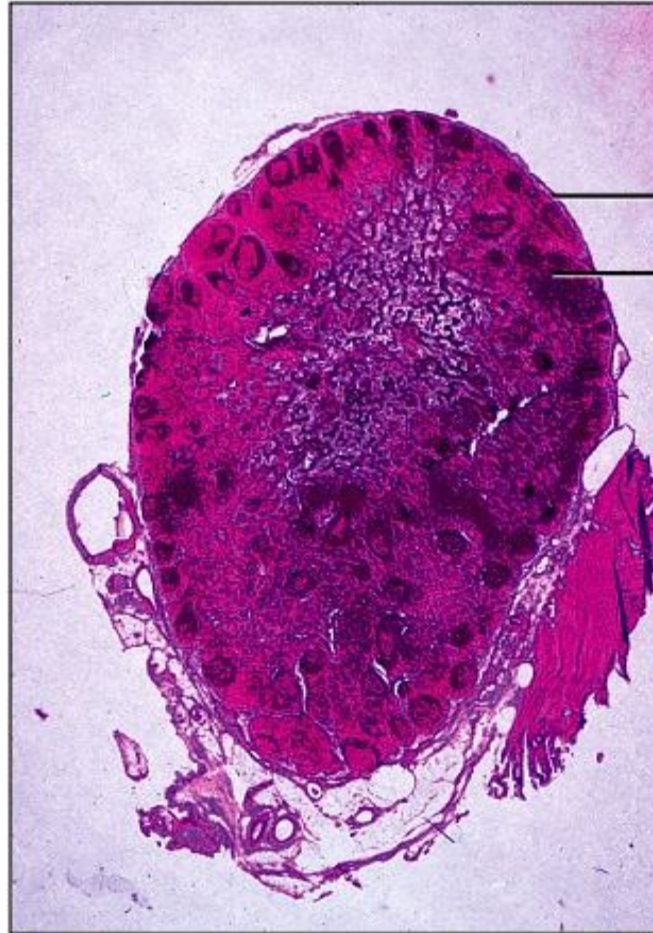- **activated B-lymphocytes (B-immunoblasts)**
- **mitotic cells**
- **plasma cells**
- **dendritic reticular cells**
- **macrophages**

Copyright © The McGraw-Hill Companies, Inc. Permission required for reproduction or display.



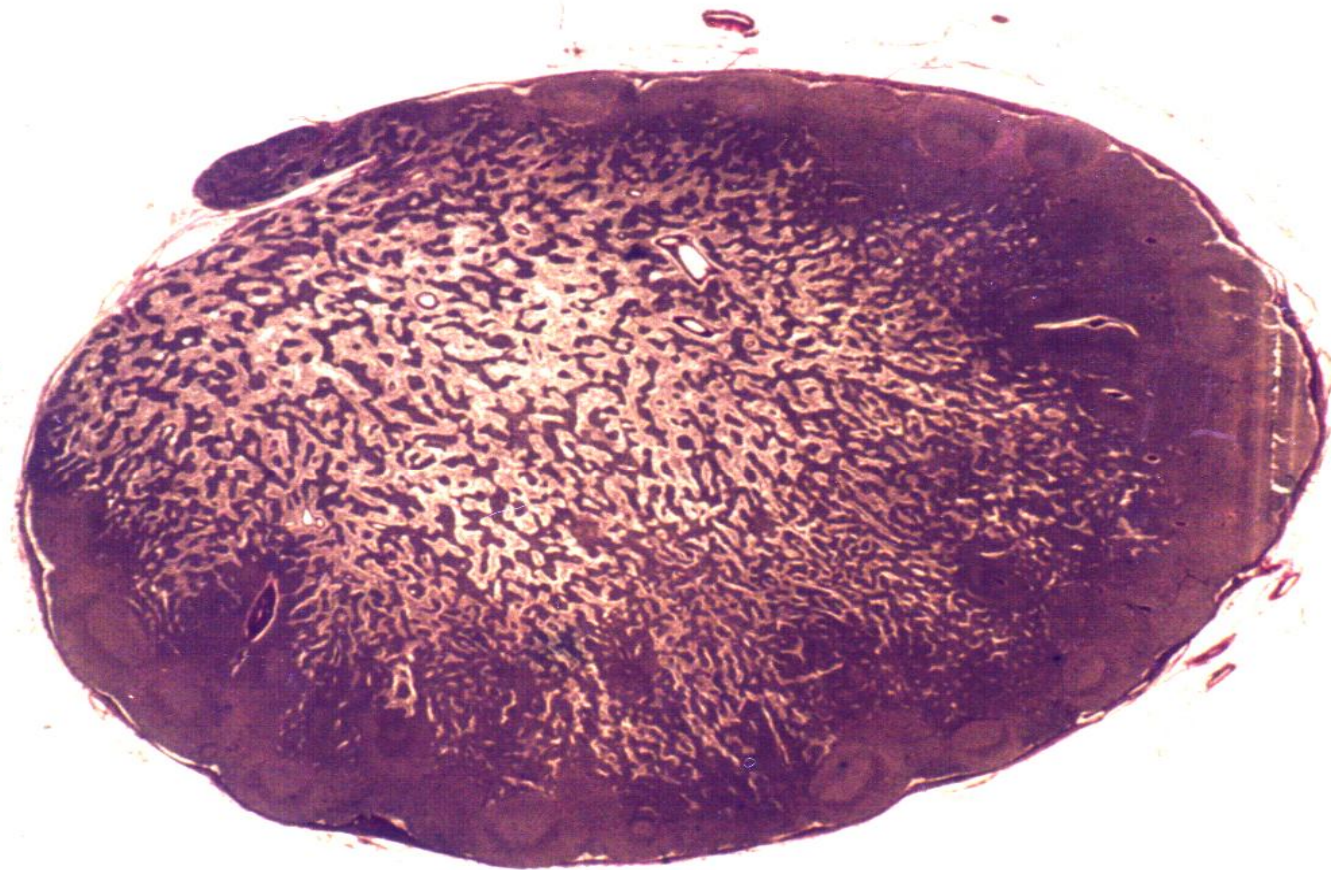


Copyright © The McGraw-Hill Companies, Inc. Permission required for reproduction or display.

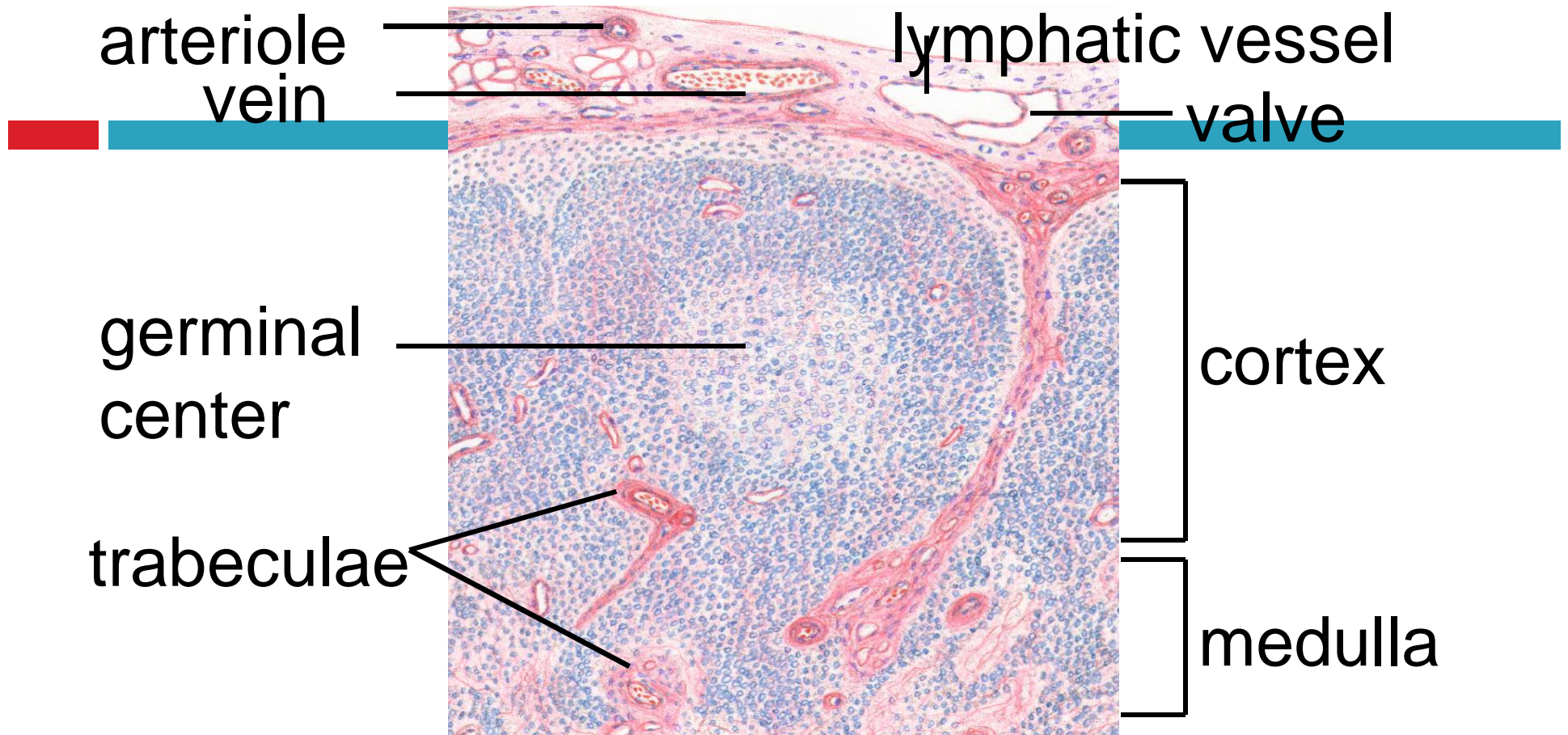


Capsule  
Lymph node

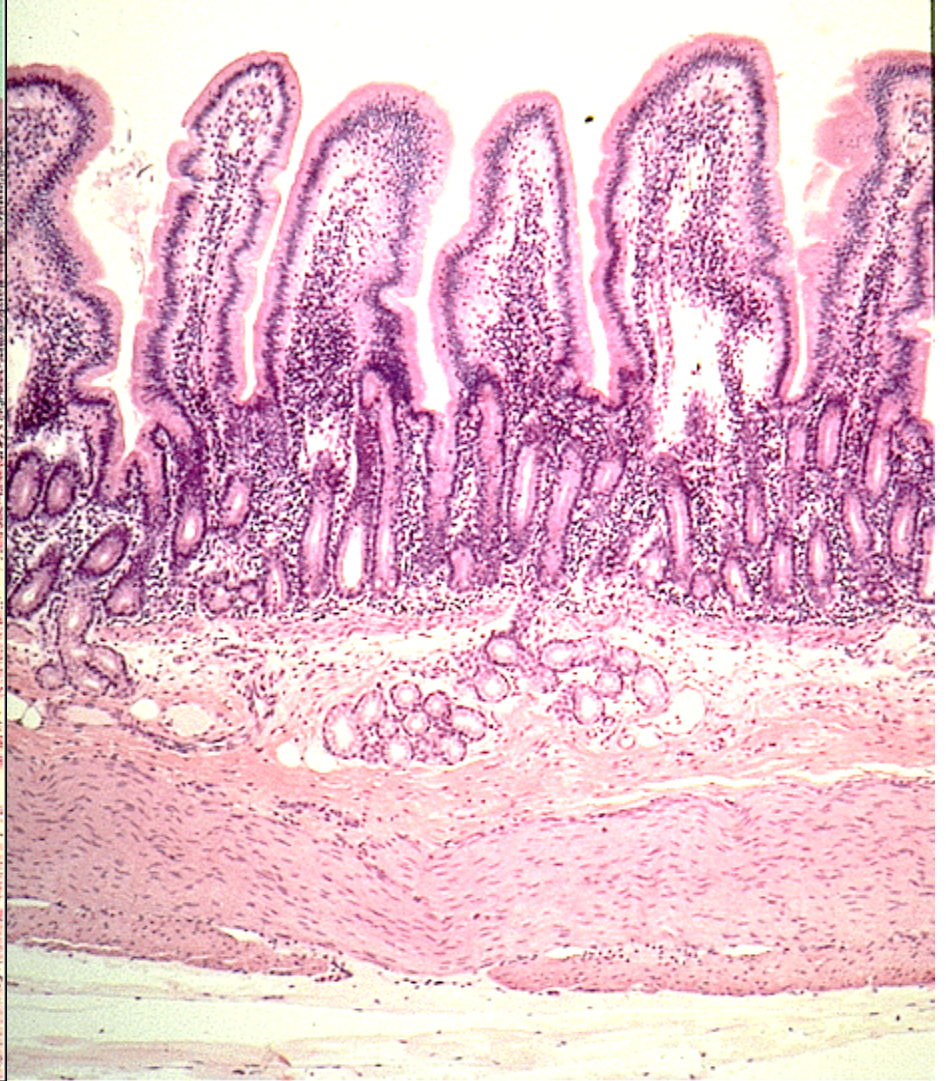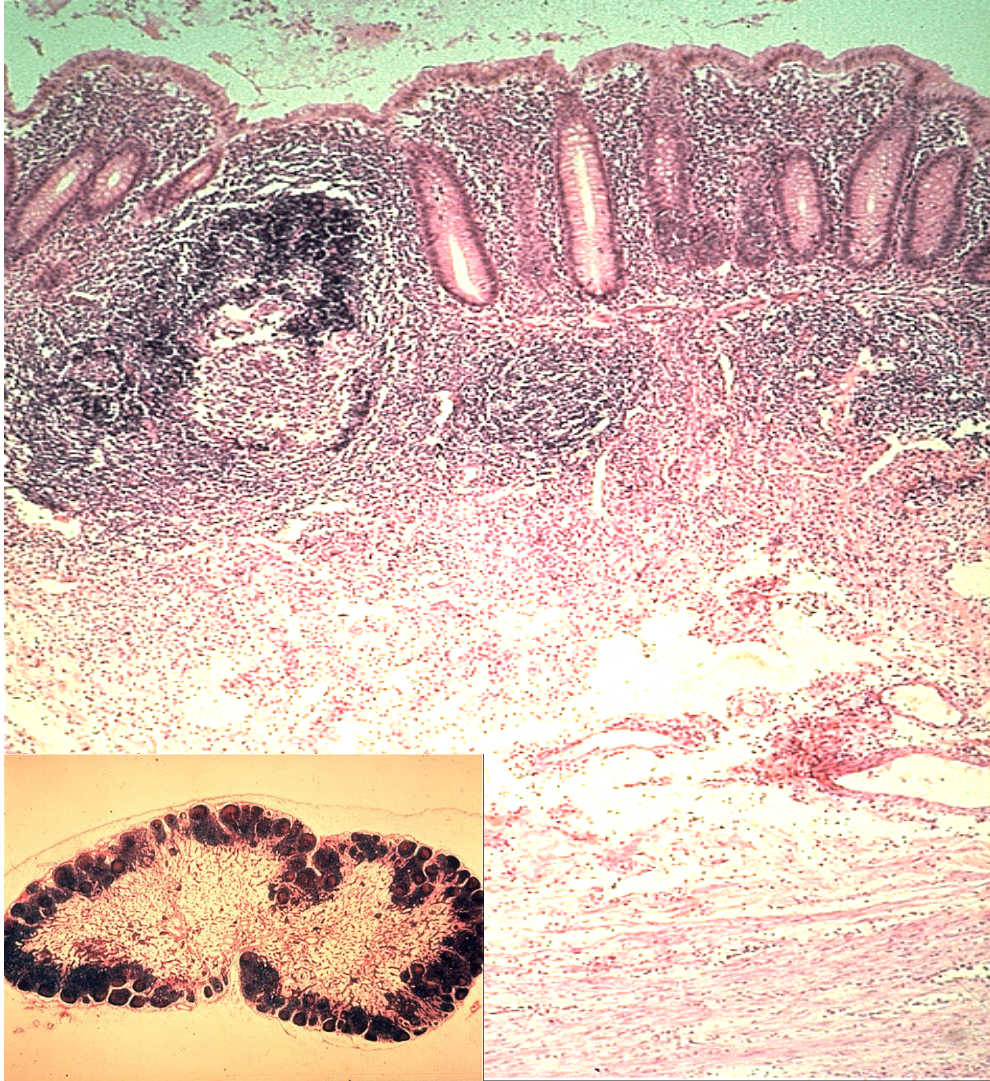




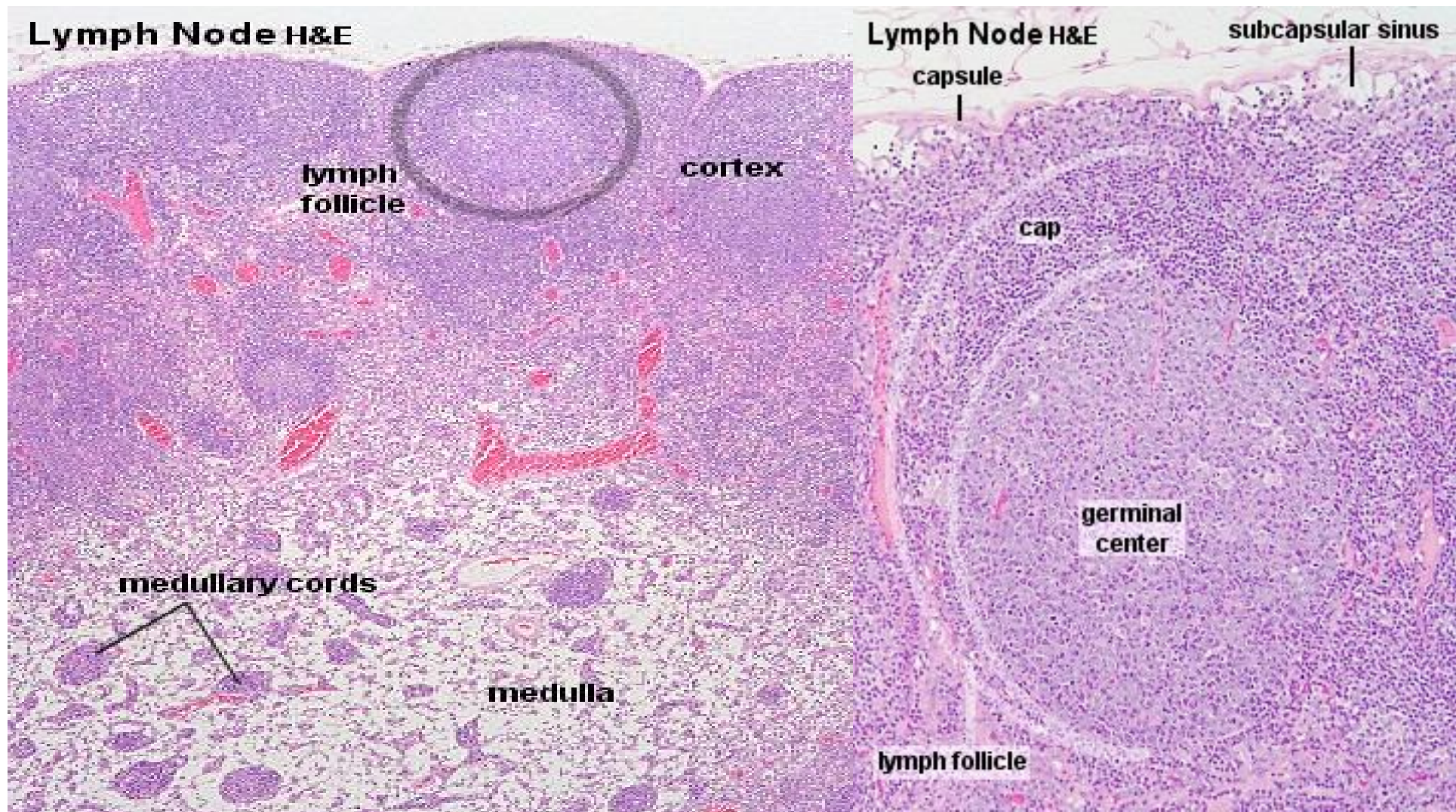




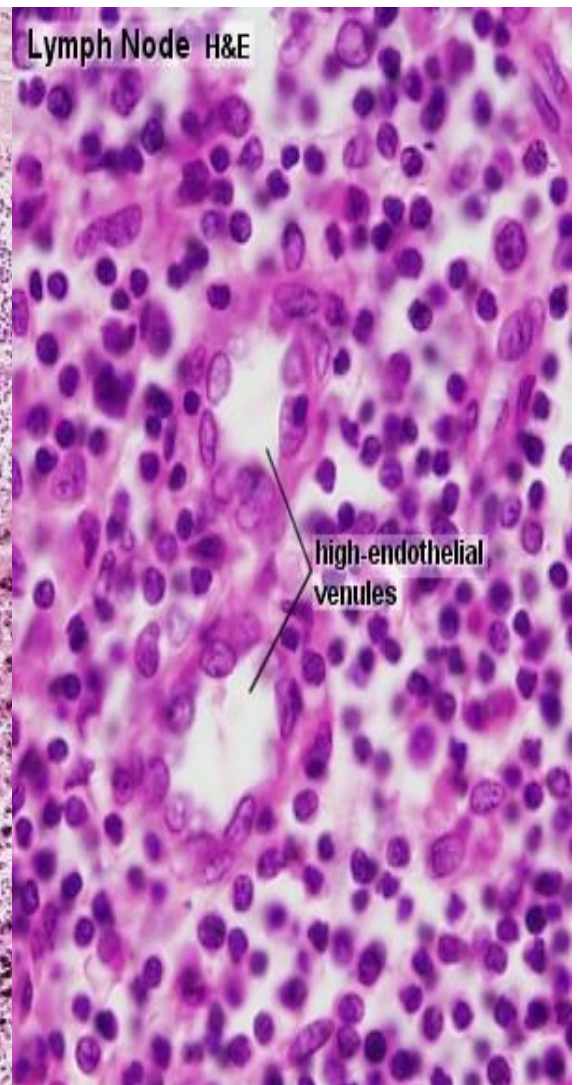
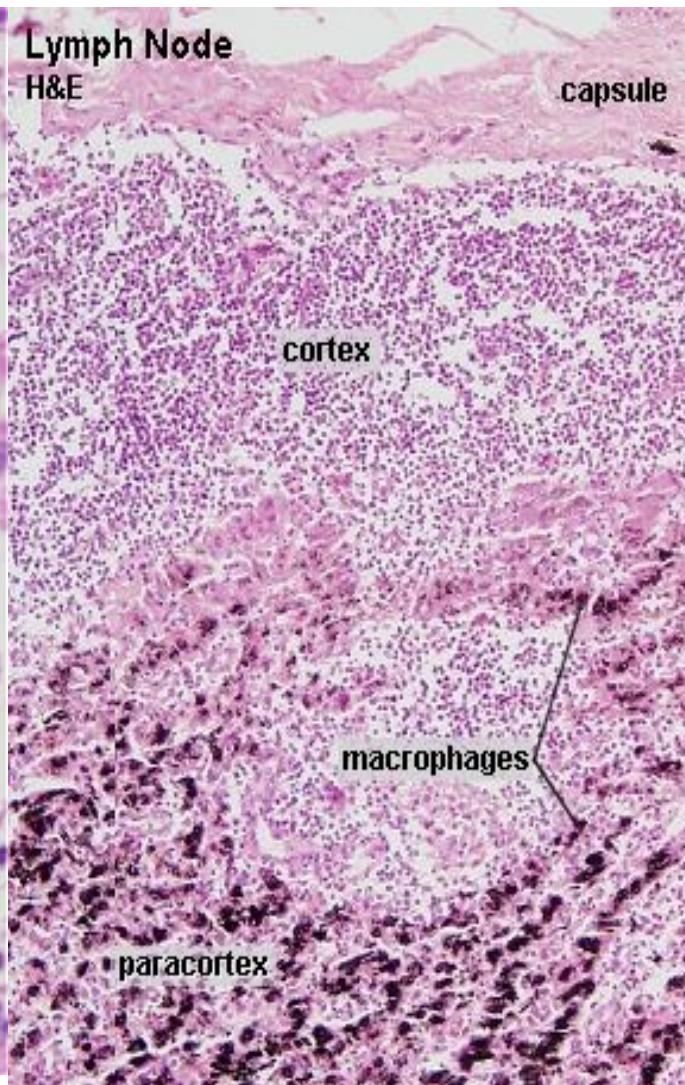
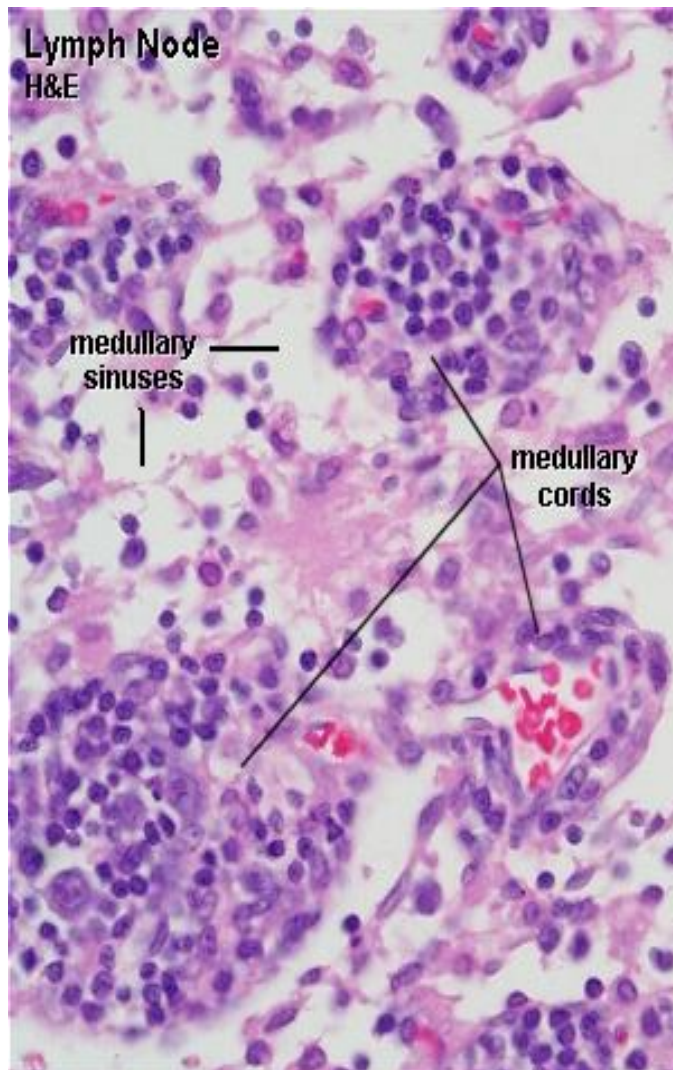




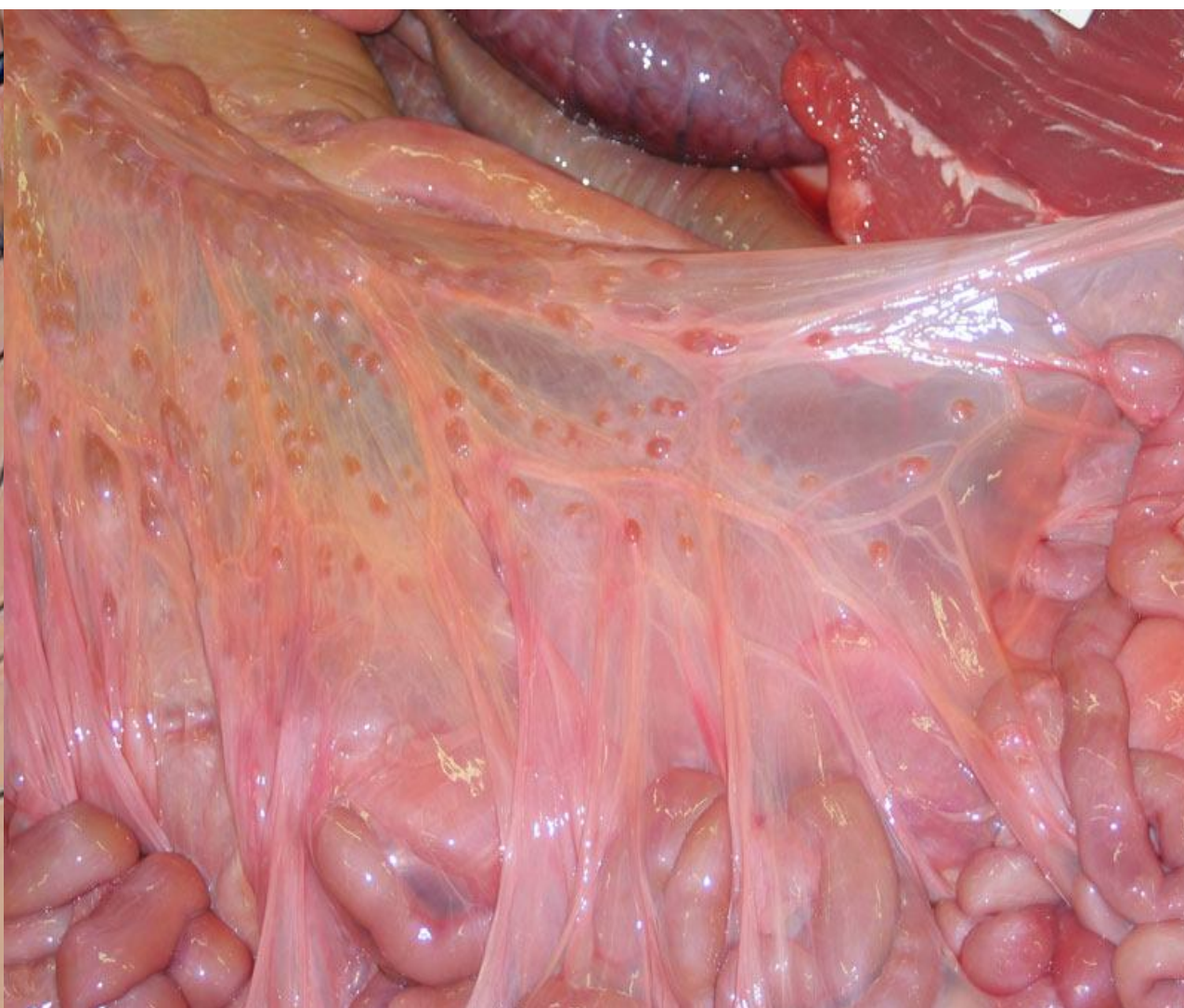
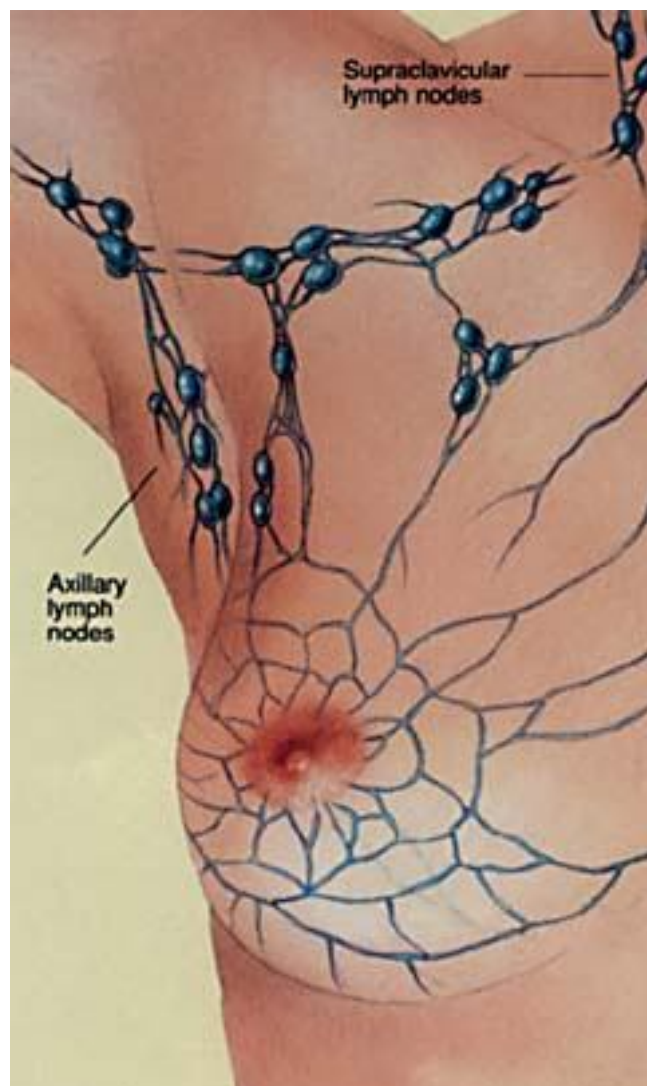





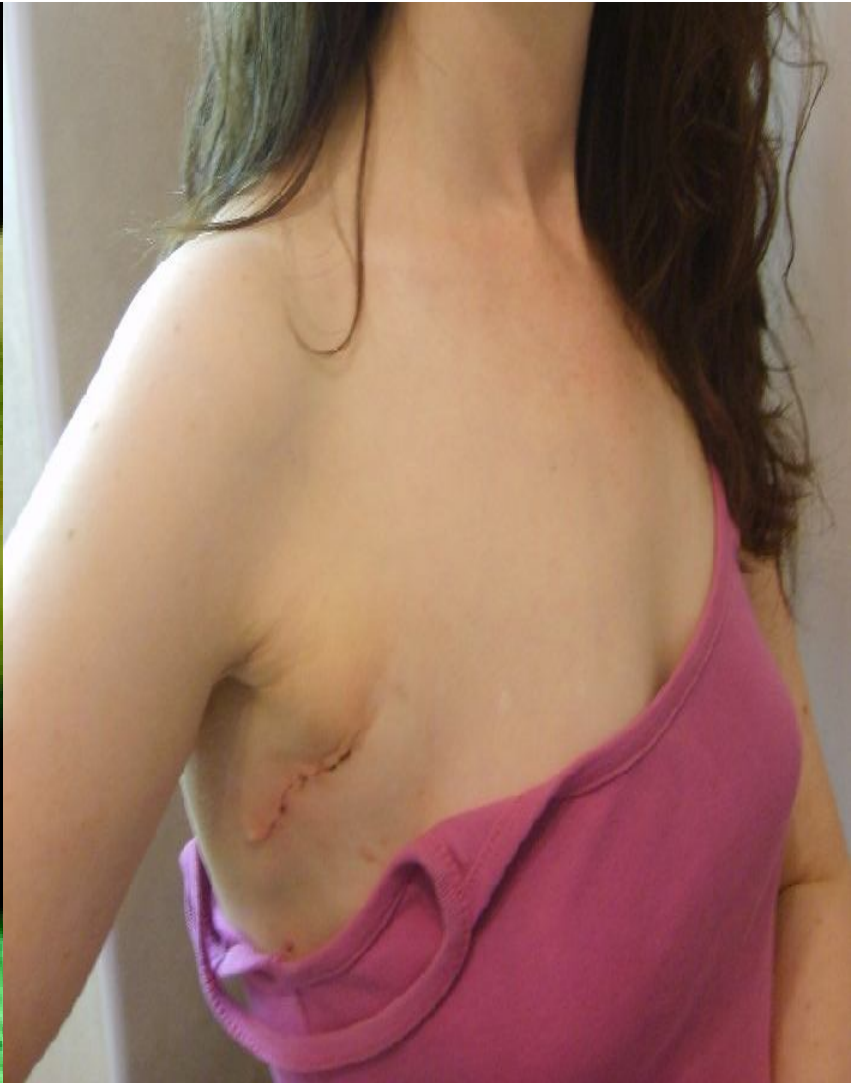
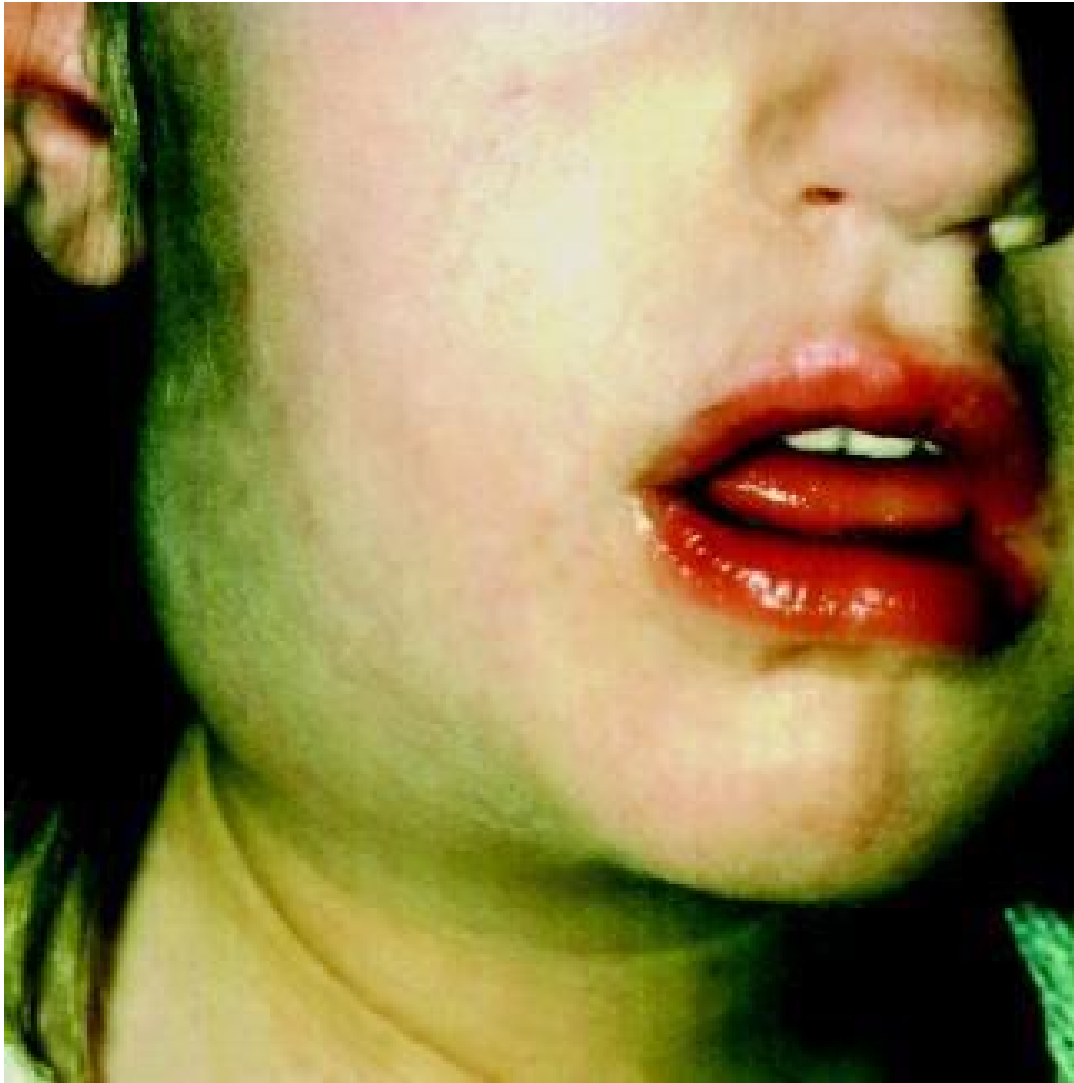


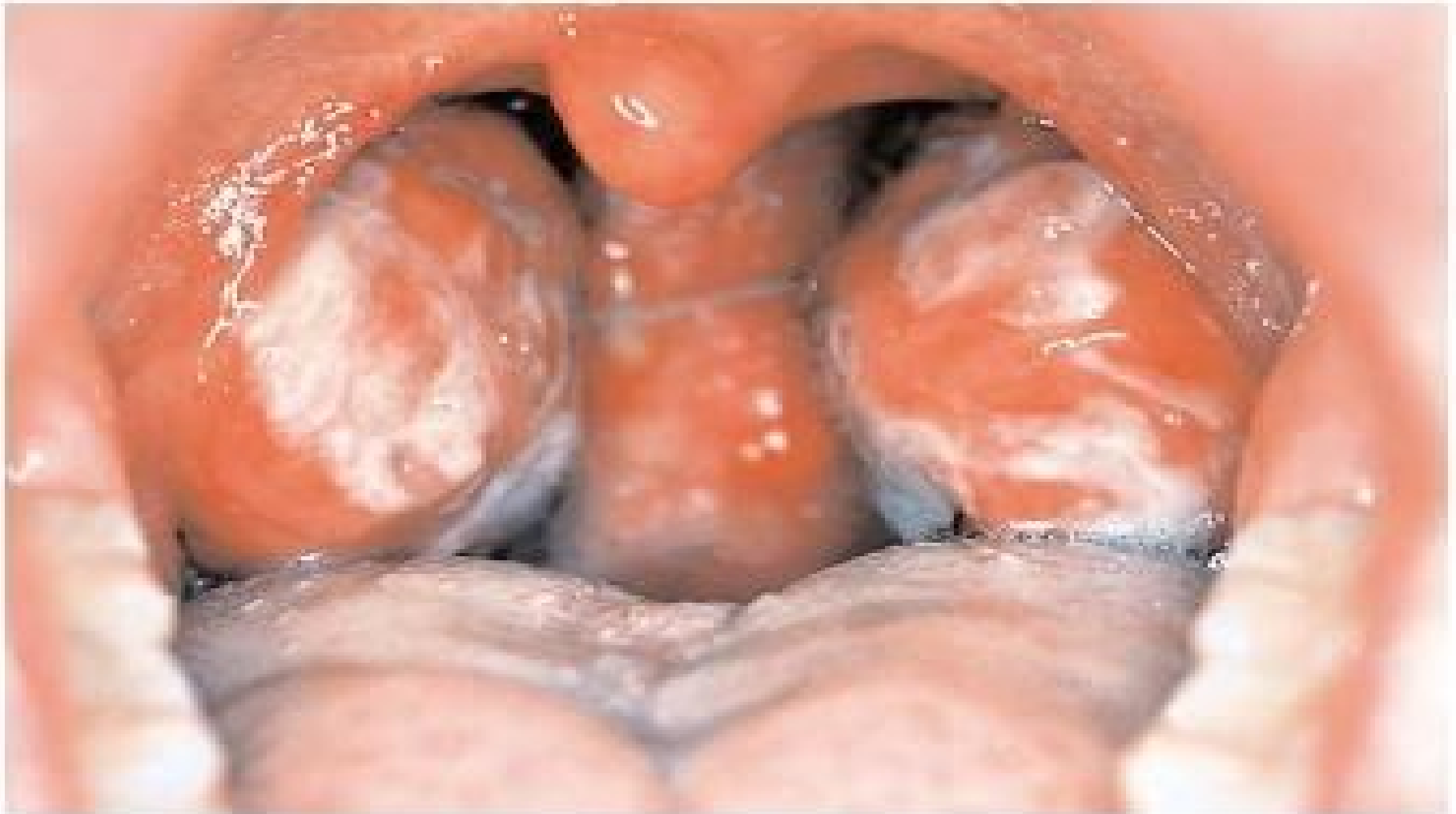


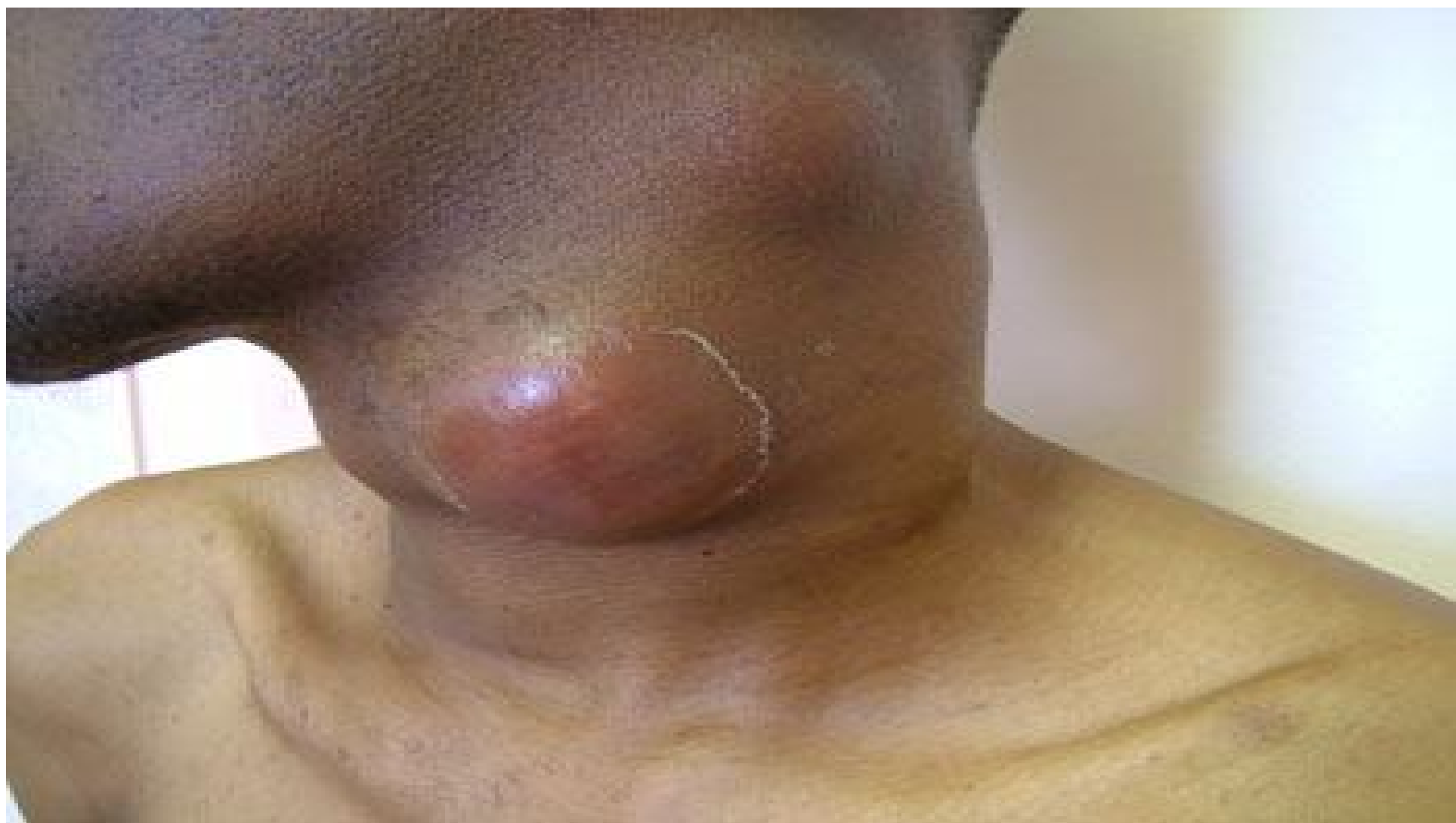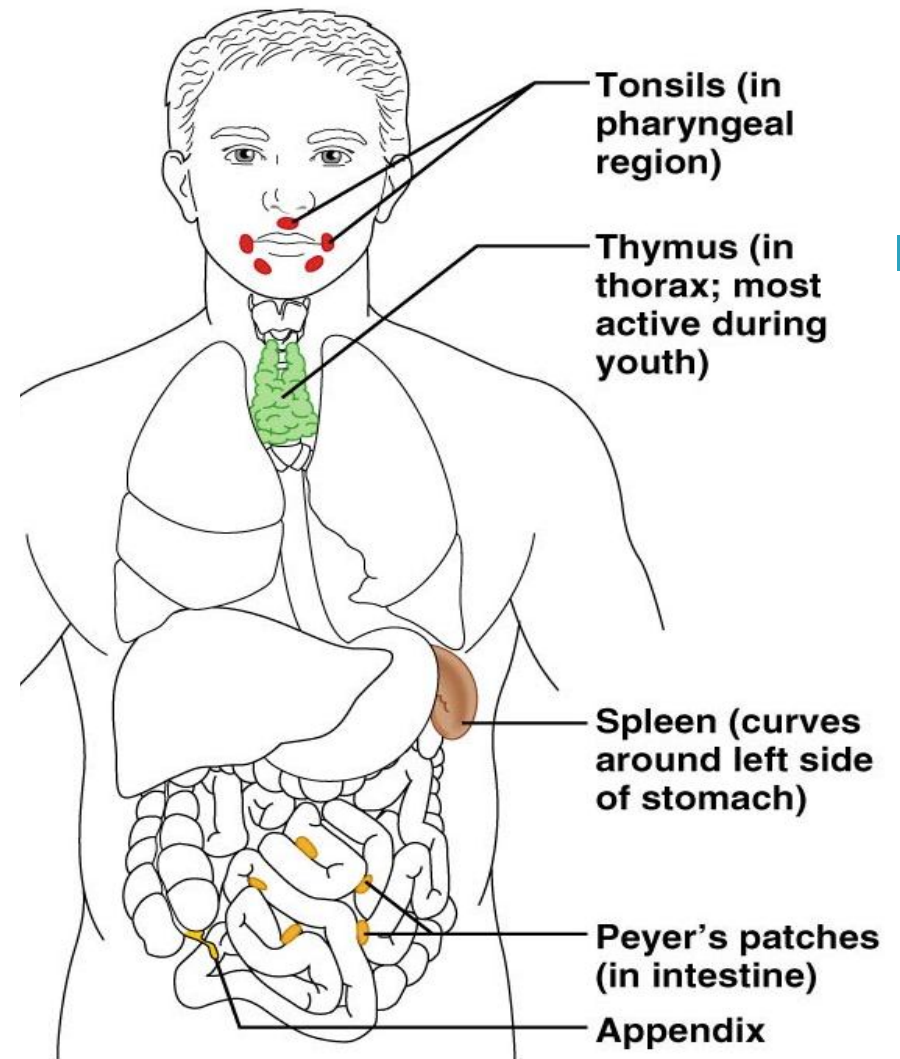
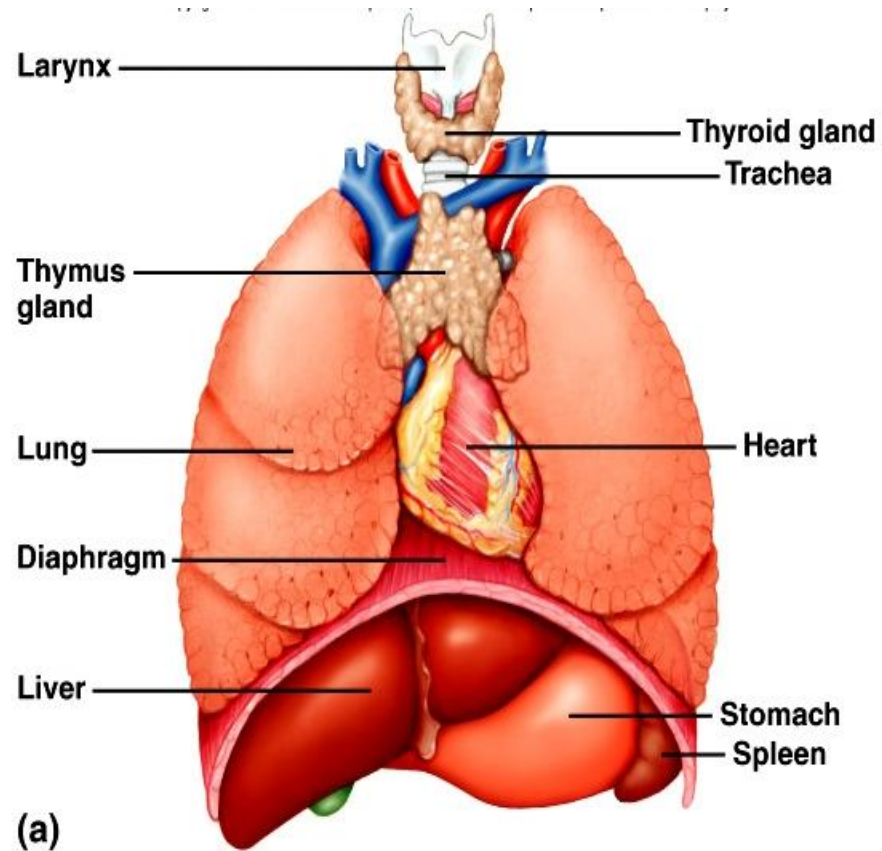


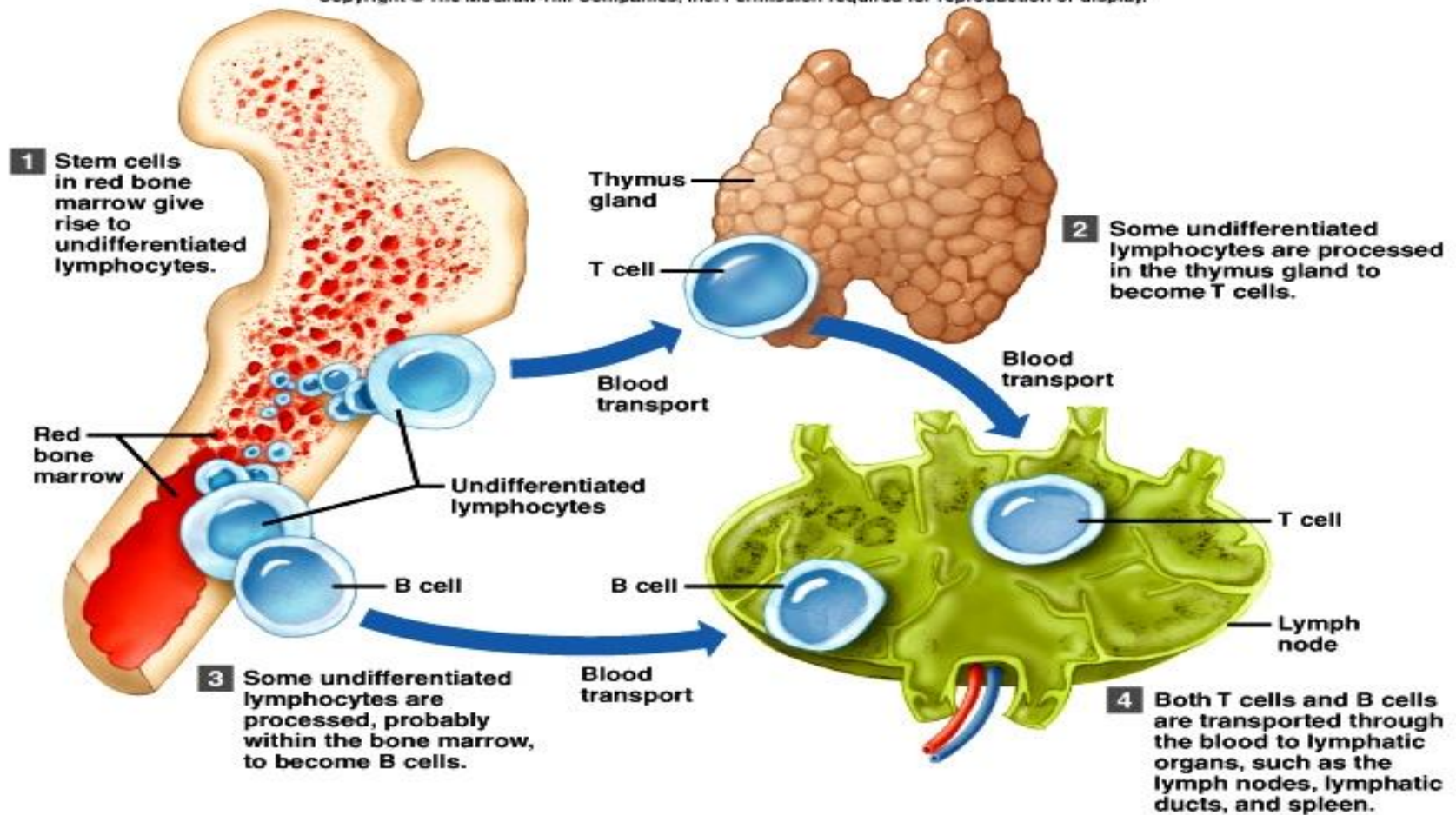




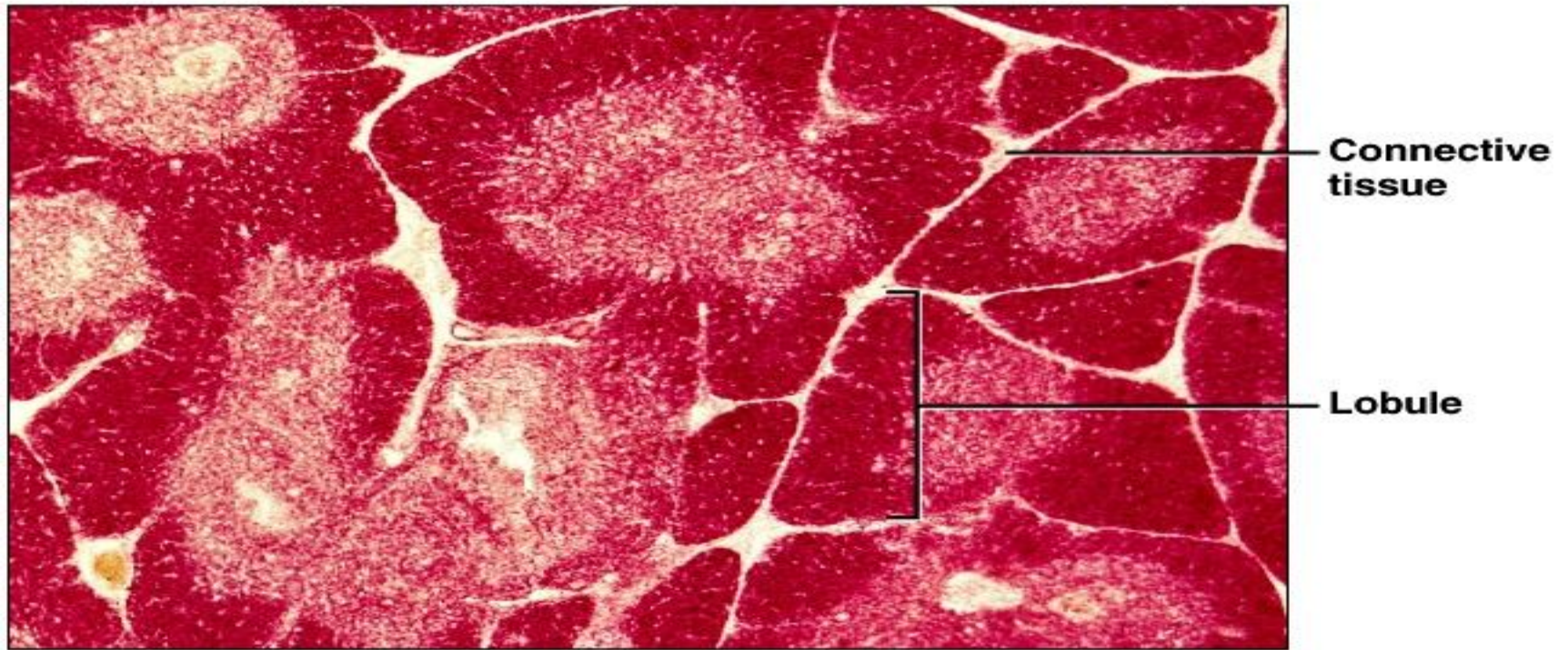


# Lymphoid Organs









**(b)**

# Lymphoid Tissue

---

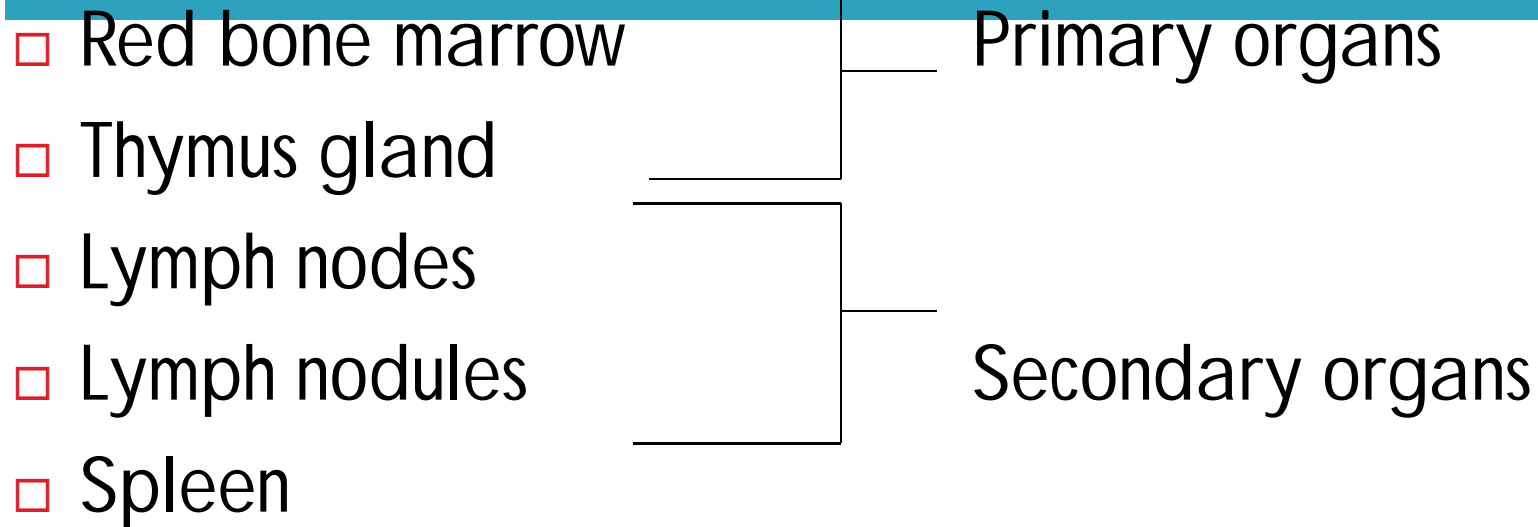
- Diffuse lymphatic tissue – scattered reticular tissue elements in every body organ
  - ▣ Larger collections appear in the lamina propria of mucous membranes and lymphoid organs
- Lymphatic follicles (nodules) – solid, spherical bodies consisting of tightly packed reticular elements and cells
  - ▣ Germinal center composed of dendritic and B cells
  - ▣ Found in isolation and as part of larger lymphoid organs

# TYPES OF LYMPHATIC TISSUE

There are three basic types of lymphatic (lymphoid) tissue:

- **Loose lymphatic tissue.** This is dominated by reticular cells and fibers and forms a loose, spongy network through which **lymph flow is slow and cells are temporarily trapped.**
- **Dense lymphatic tissue.** This tissue is dominated by large populations of **closely aggregated lymphocytes.**
- **Nodular lymphatic tissue** (lymphatic nodules). Lymphatic nodules are found in all the lymphatic organs apart from the thymus.

# Lymphatic Organs





## Lymphoid organs

- **Primary lymphoid organs**
  - Bone marrow and thymus
- **Secondary lymphoid organs**
  - Tonsils, spleen

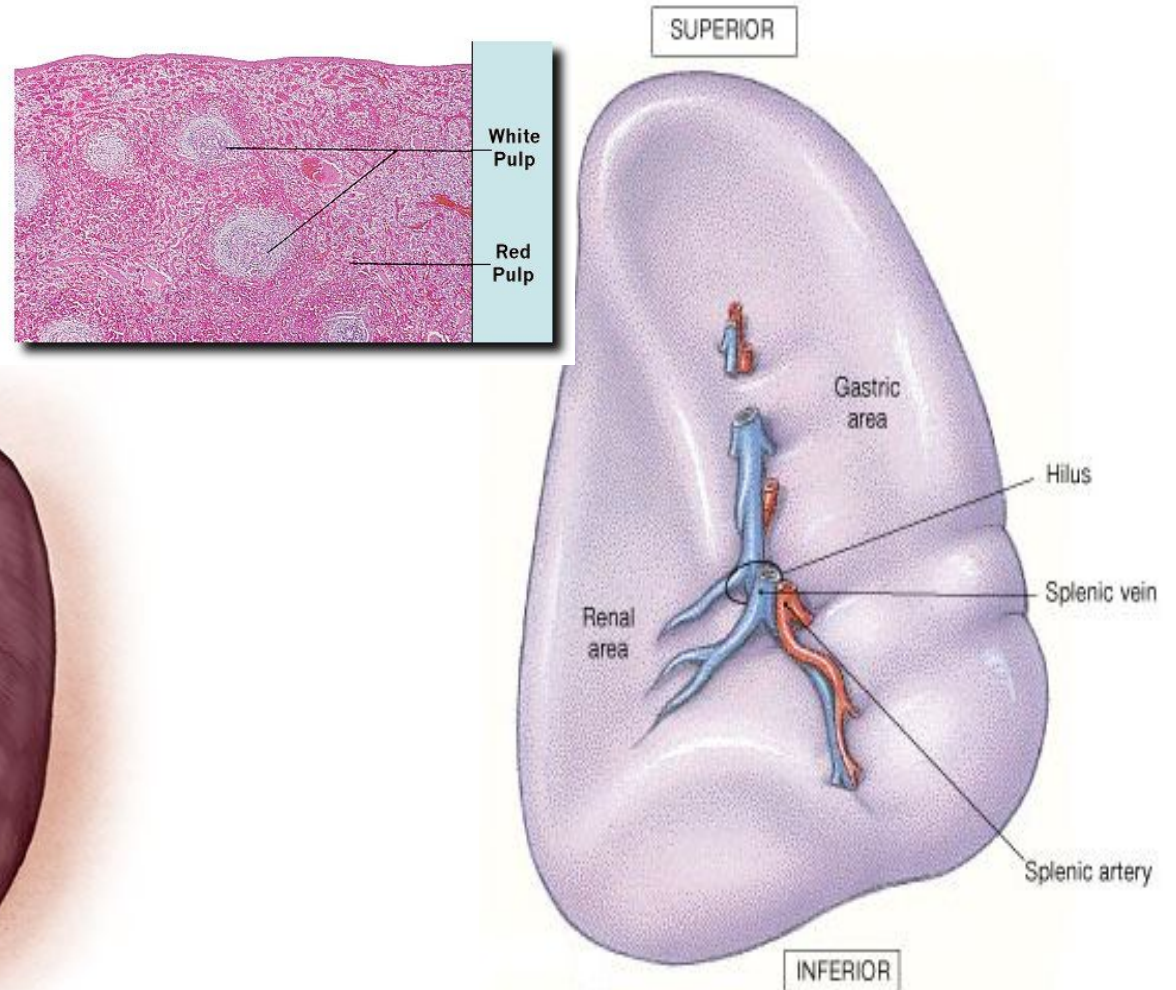
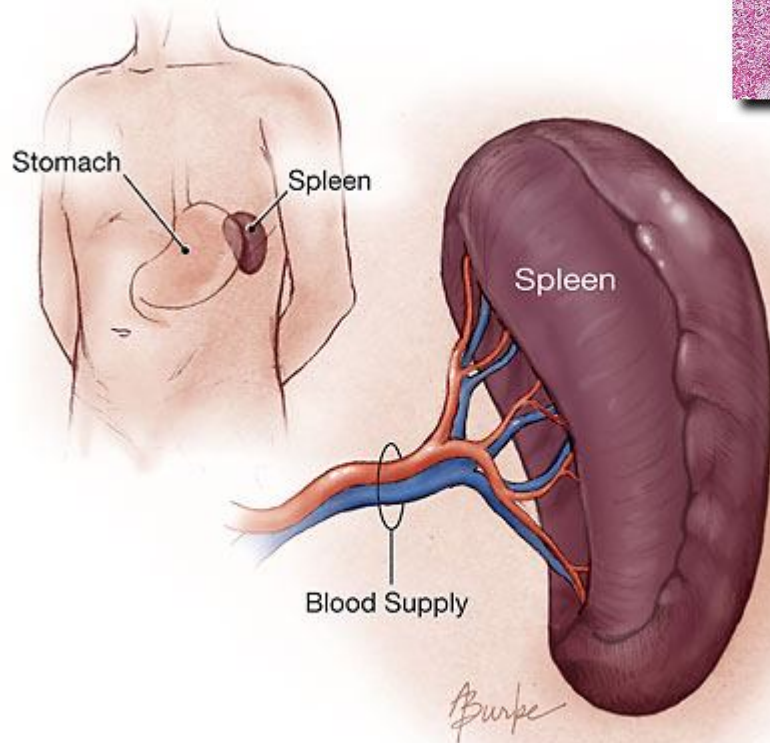


# Other Lymphoid Organs

---

- ❑ The spleen, thymus gland, and tonsils
- ❑ Peyer's patches and bits of lymphatic tissue scattered in connective tissue
- ❑ All are composed of reticular connective tissue
- ❑ All help protect the body
- ❑ Only lymph nodes filter lymph

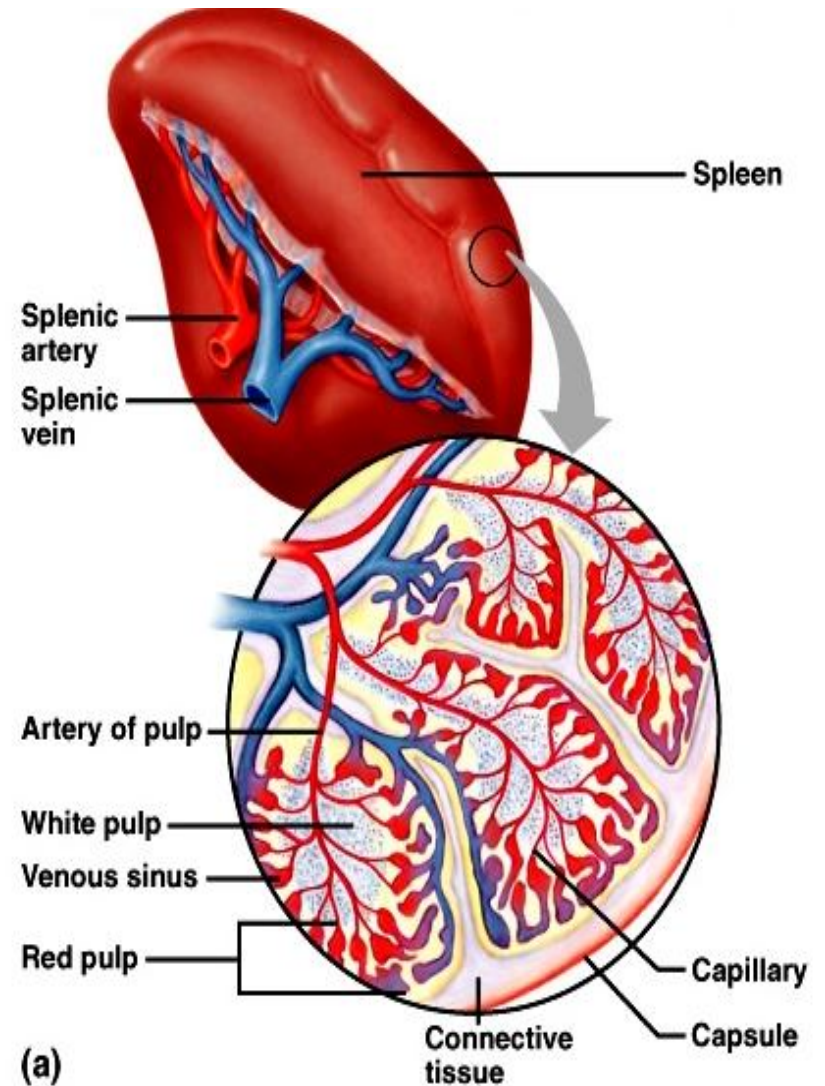
# Spleen



(b) Visceral surface of spleen

# Spleen

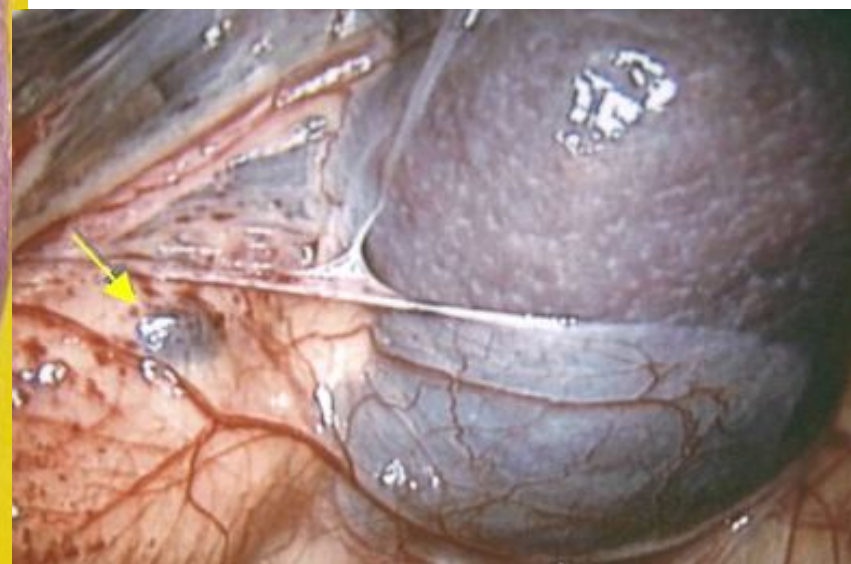
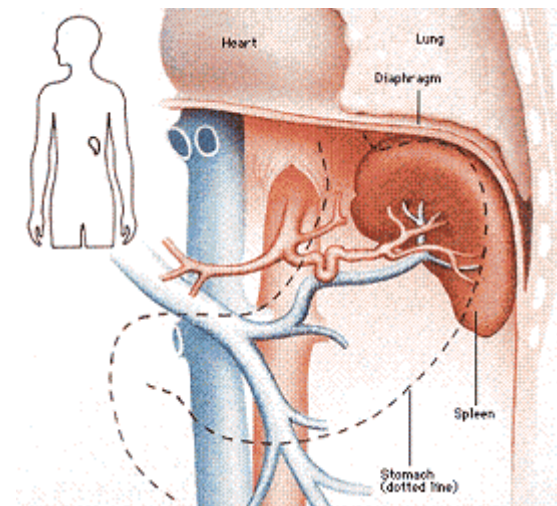
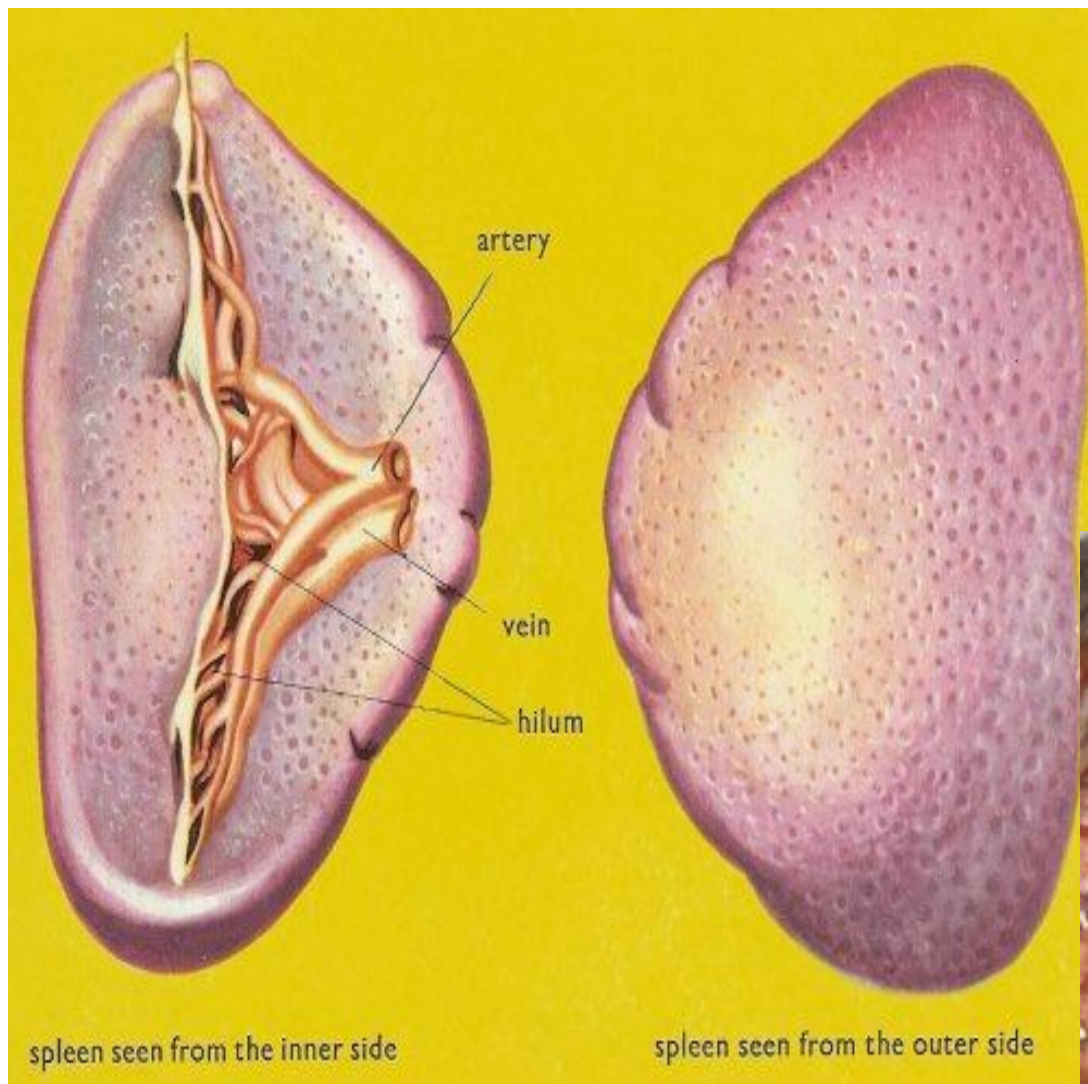
- Largest lymphoid organ, located on the left side of the abdominal cavity beneath the diaphragm
- It is served by the splenic artery and vein, which enter and exit at the hilus
- **Functions:**
  - ▣ Site of lymphocyte proliferation
  - ▣ Immune surveillance and response
  - ▣ Cleanses the blood



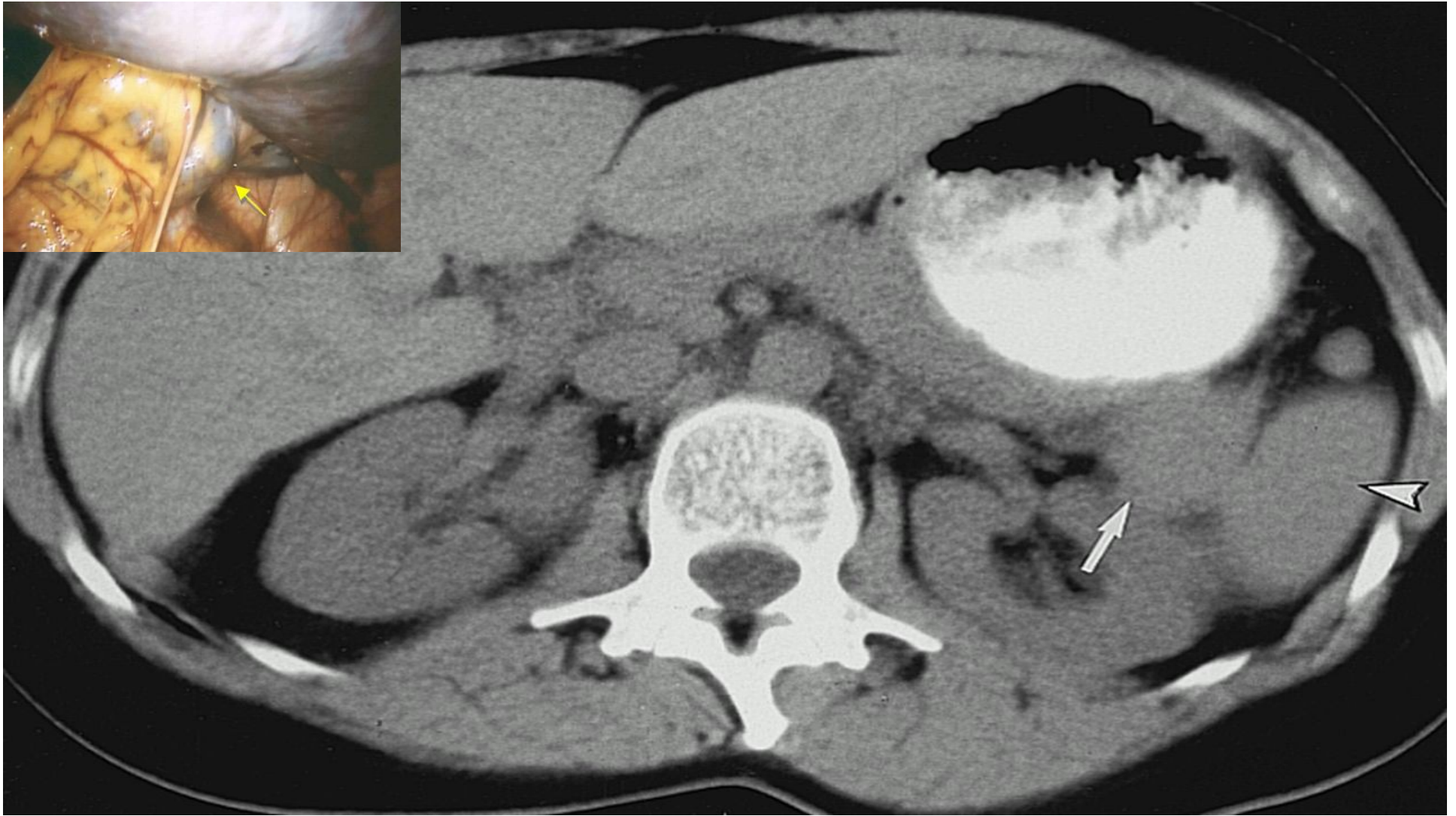
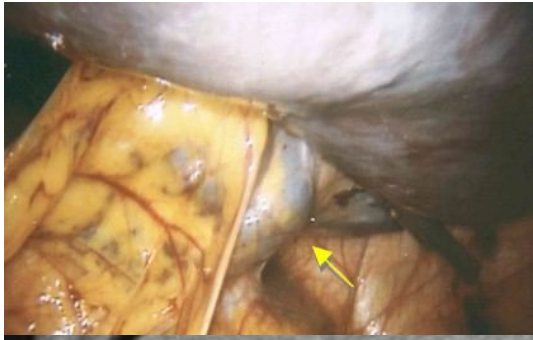
# Functions of the Spleen

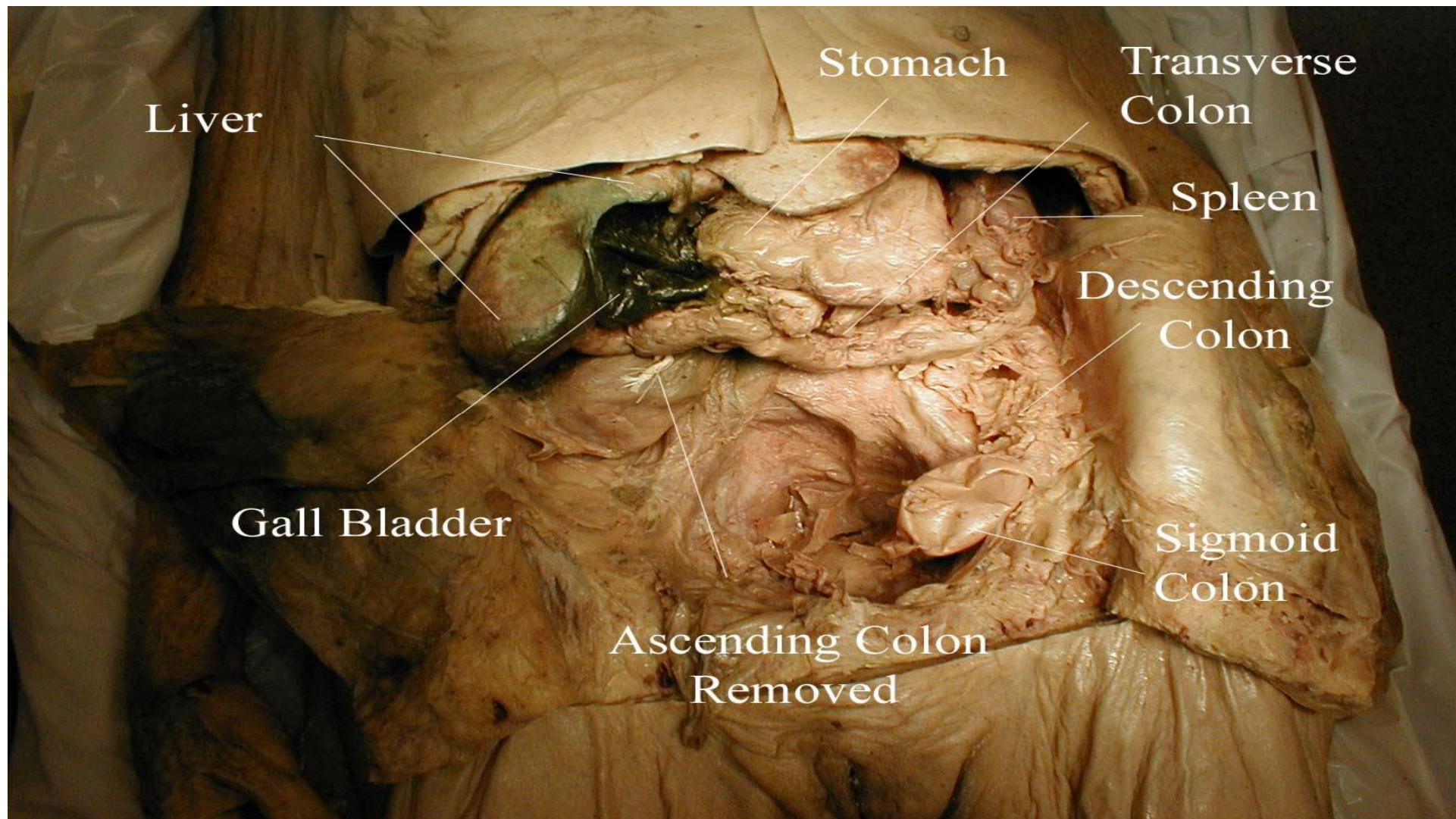
- Defense As blood passes through the sinusoids, reticuloendothelial cell (macrophages) lining these venous spaces remove microorganisms from the blood and destroy them by phagocytosis.
- **Hematopoiesis**
  - Monocytes and lymphocytes complete their development to become activated in the spleen.
  - Before birth, red blood cells are also formed in the spleen.
- **Red blood cell and platelet destruction**. Macrophages lining the spleen's sinusoids remove worn-out red blood cells and imperfect platelets from the blood and destroy them by phagocytosis.
- **Also break apart the hemoglobin molecules** from the destroyed red blood cells and salvage their iron and globin content by returning them to the blood stream for storage in bone marrow and liver.
- **Blood reservoir** Pulp of the spleen and its venous sinuses store considerable blood which can be released during hemorrhage.



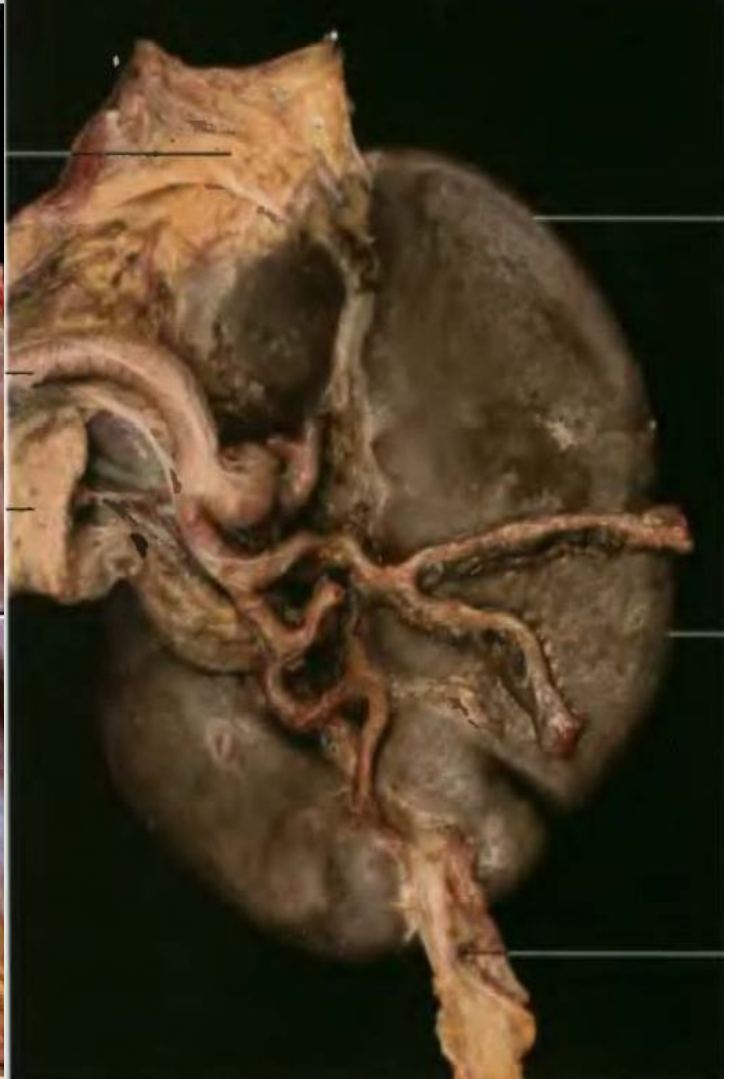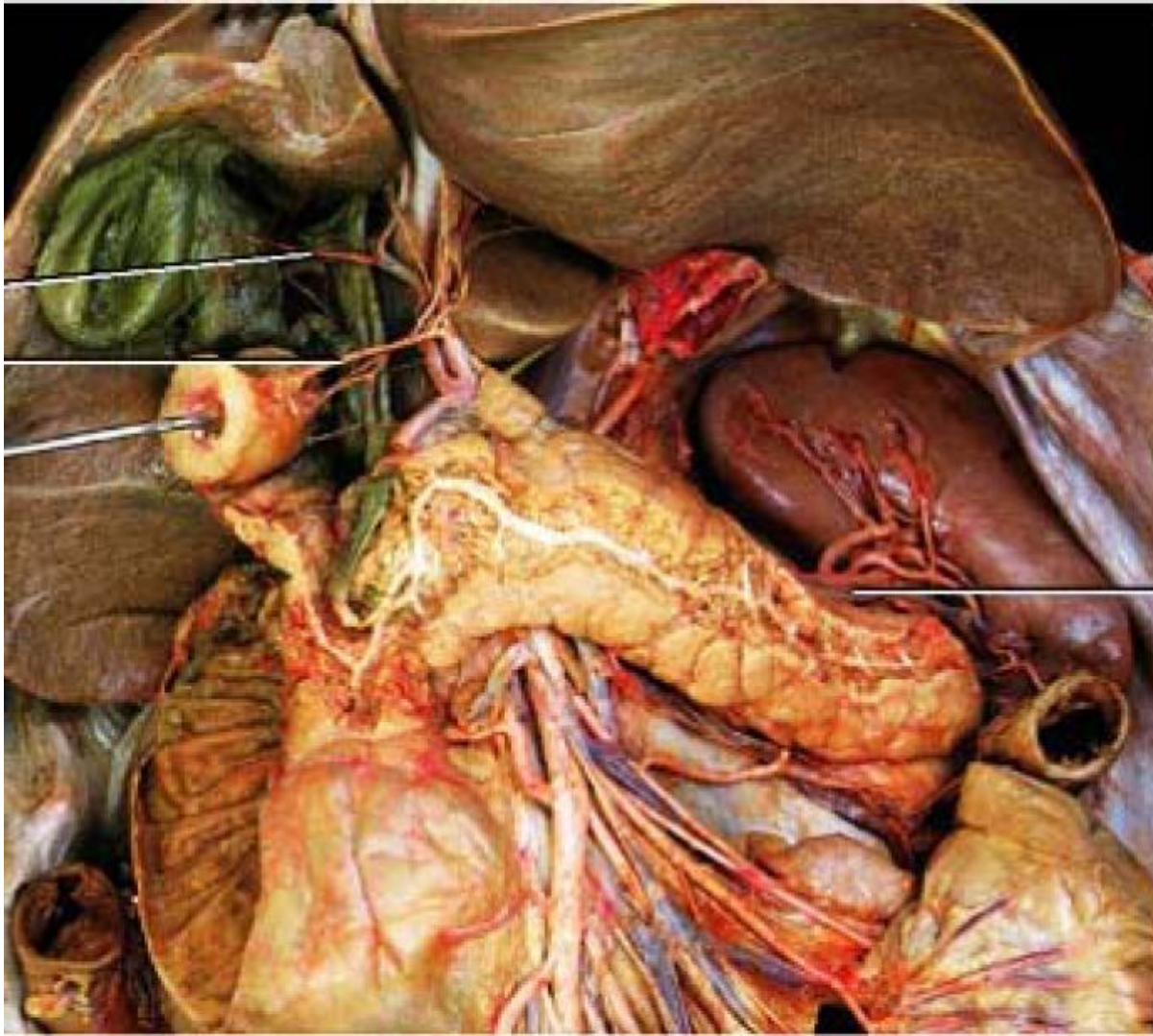


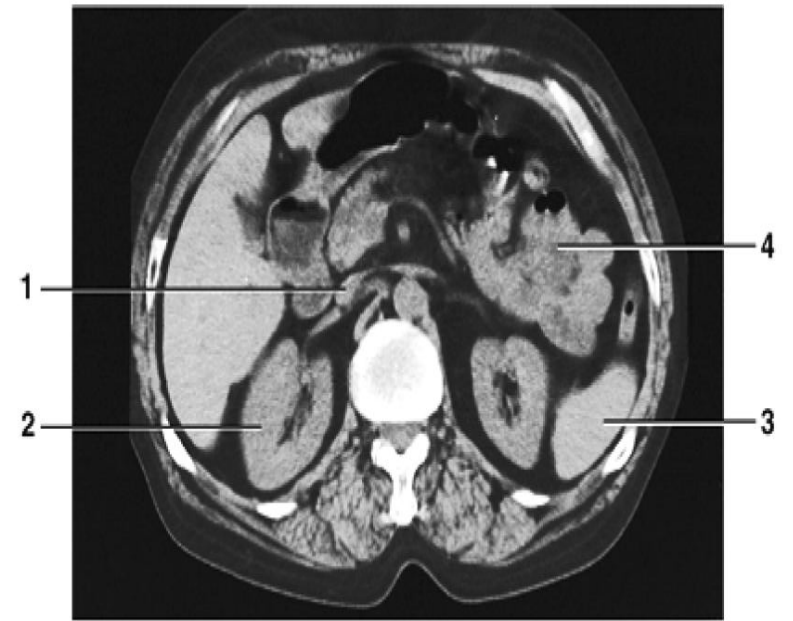

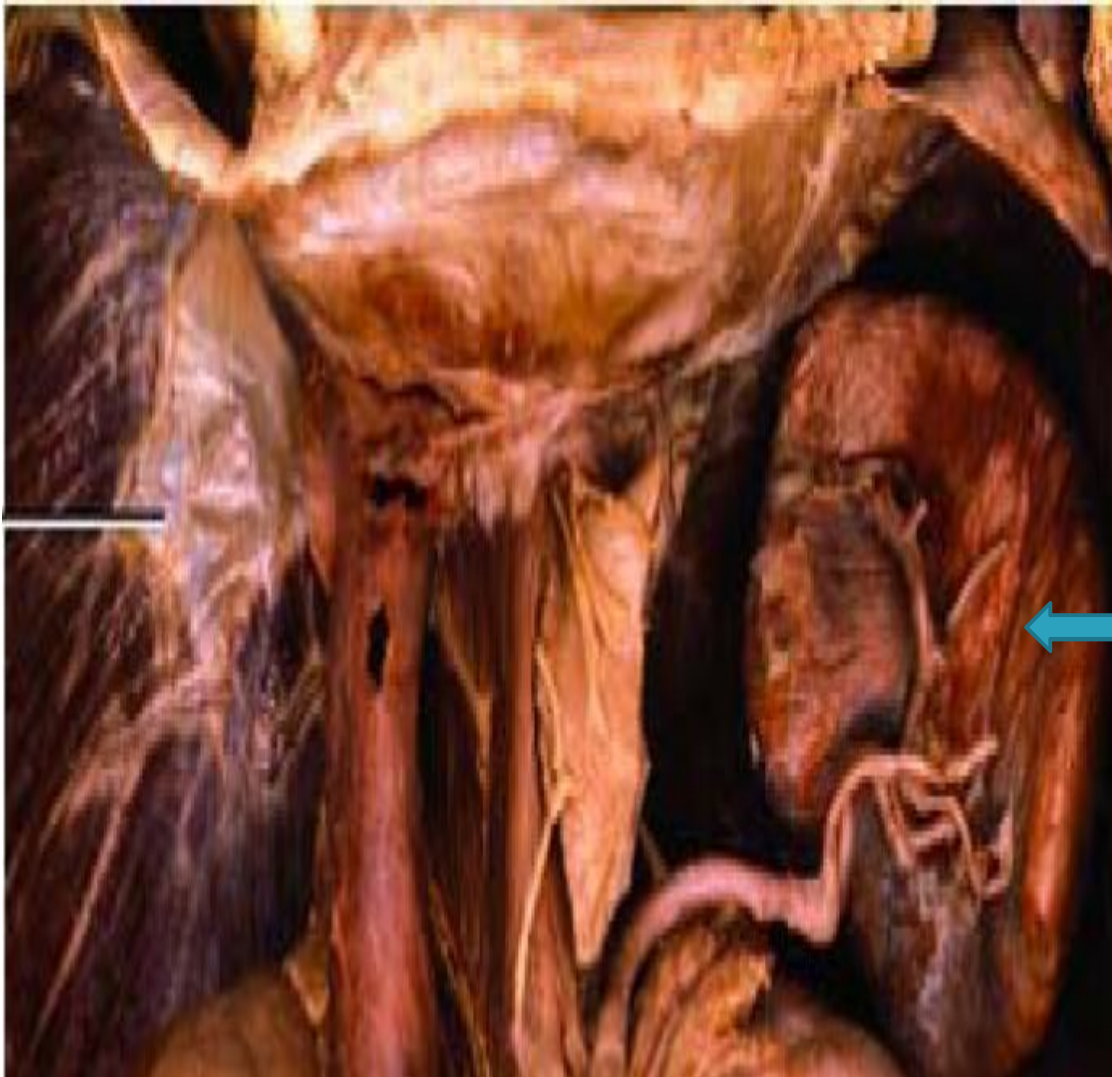










## 2.20

1. inferior vena cava
2. right kidney
3. spleen
4. small bowel



# Additional Spleen Functions

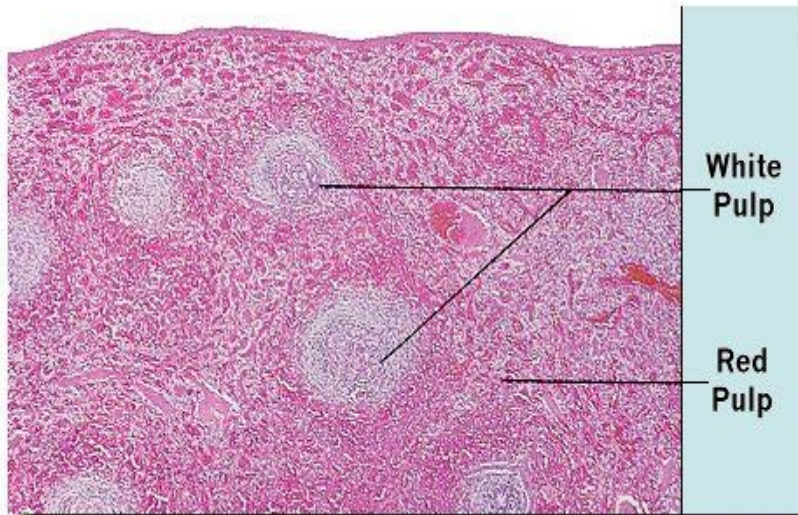
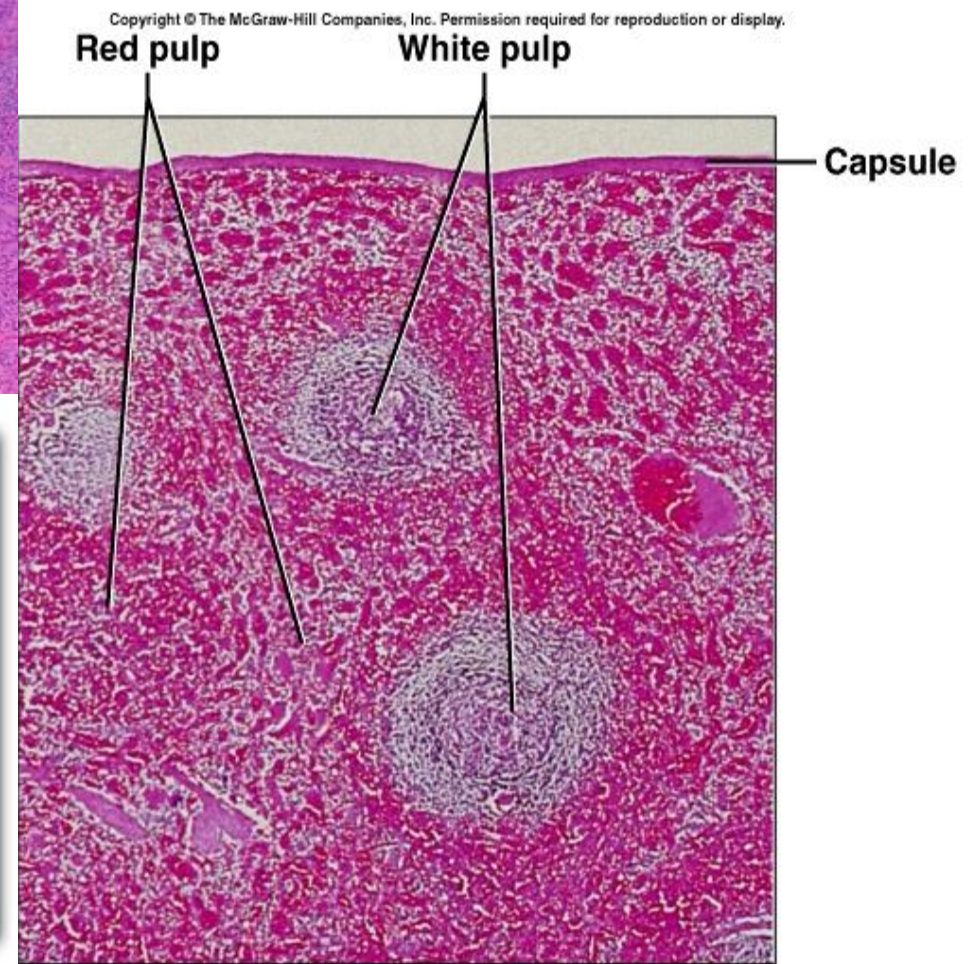
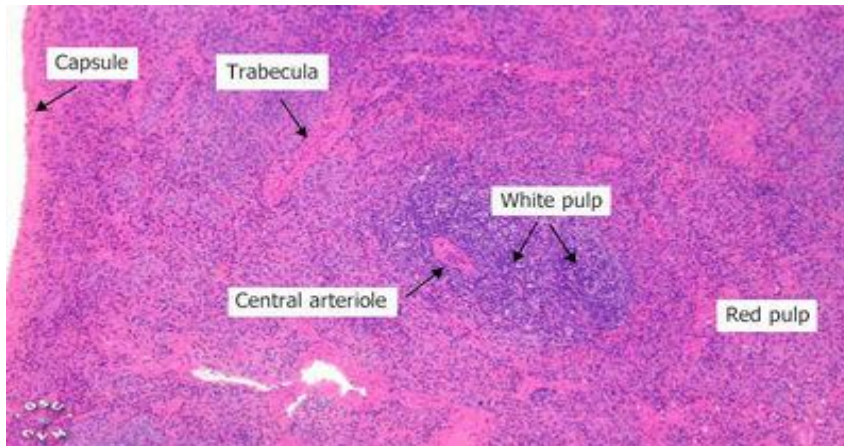
---

- ❑ Stores breakdown products of RBCs for later reuse
  - ▣ Spleen macrophages salvage and store iron for later use by bone marrow
- ❑ Site of fetal erythrocyte production (normally ceases after birth)
- ❑ Stores blood platelets

# Structure of the Spleen

---

- ❑ Surrounded by a fibrous capsule, it has trabeculae that extend inward and contains lymphocytes, macrophages, and huge numbers of erythrocytes
- ❑ Two distinct areas:
  - White pulp – containing mostly lymphocytes suspended on reticular fibers and involved in immune functions
  - Red pulp – remaining splenic tissue concerned with disposing of worn-out RBCs and bloodborne pathogens





# Structure of the Spleen

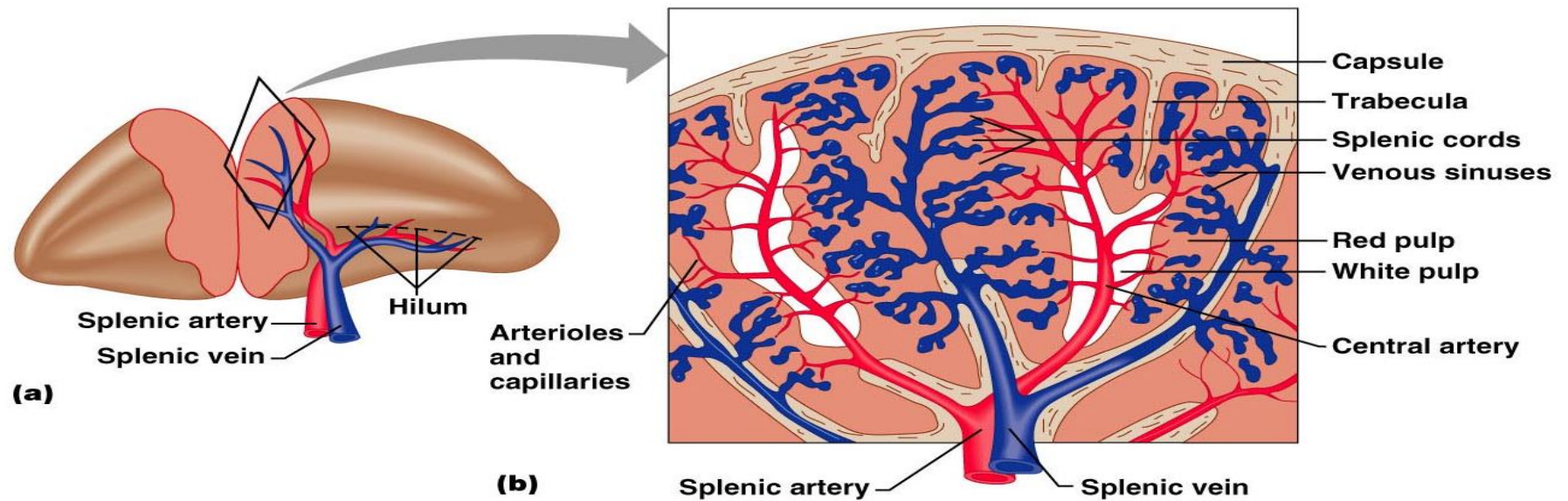
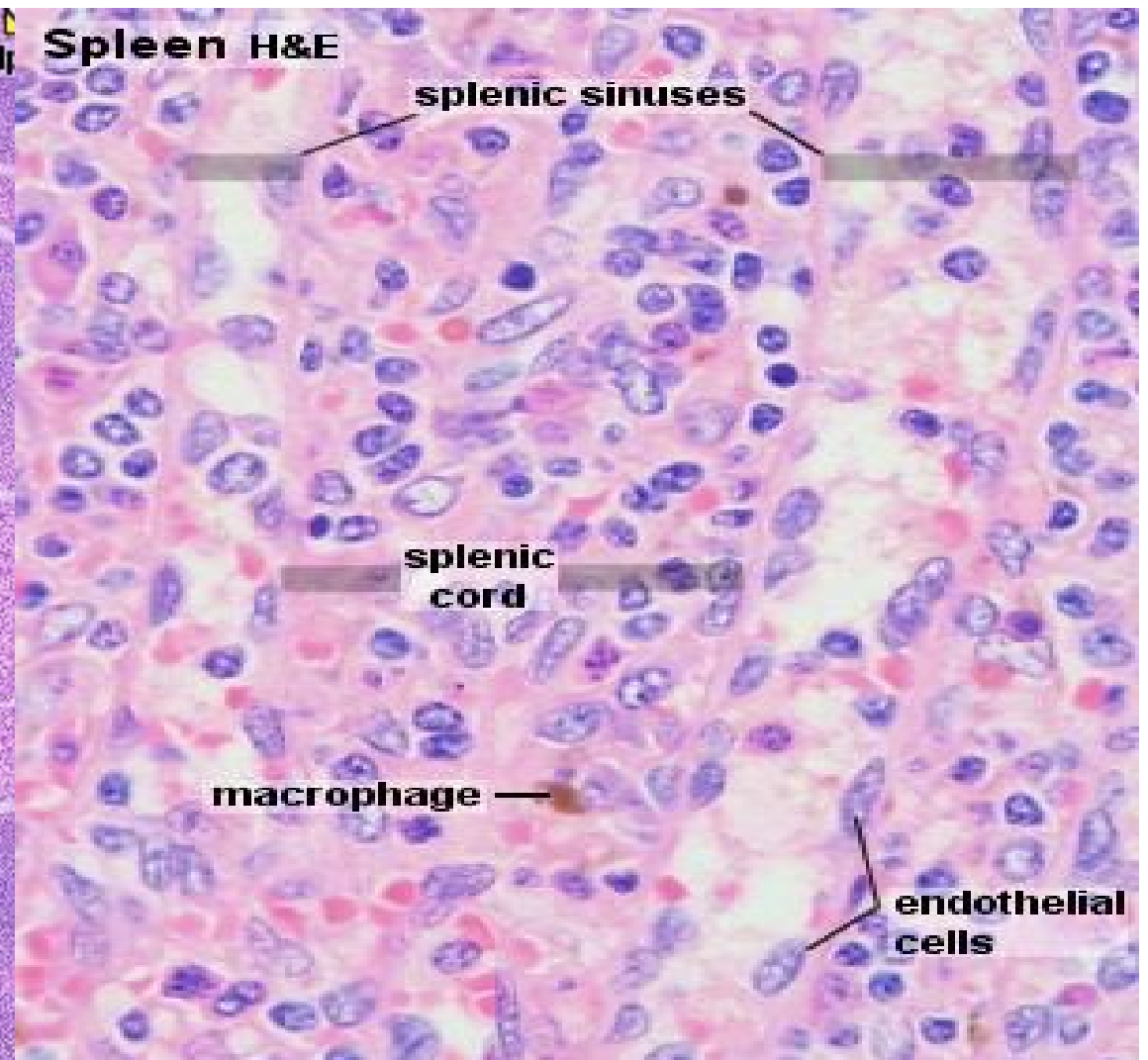
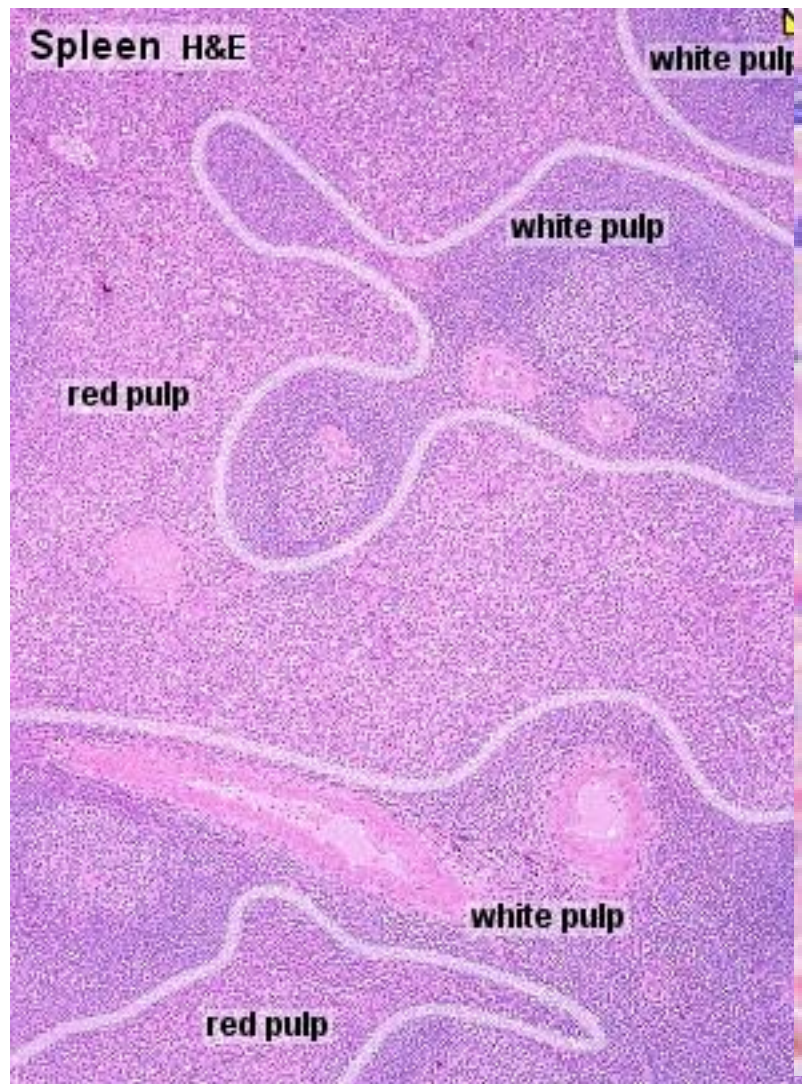
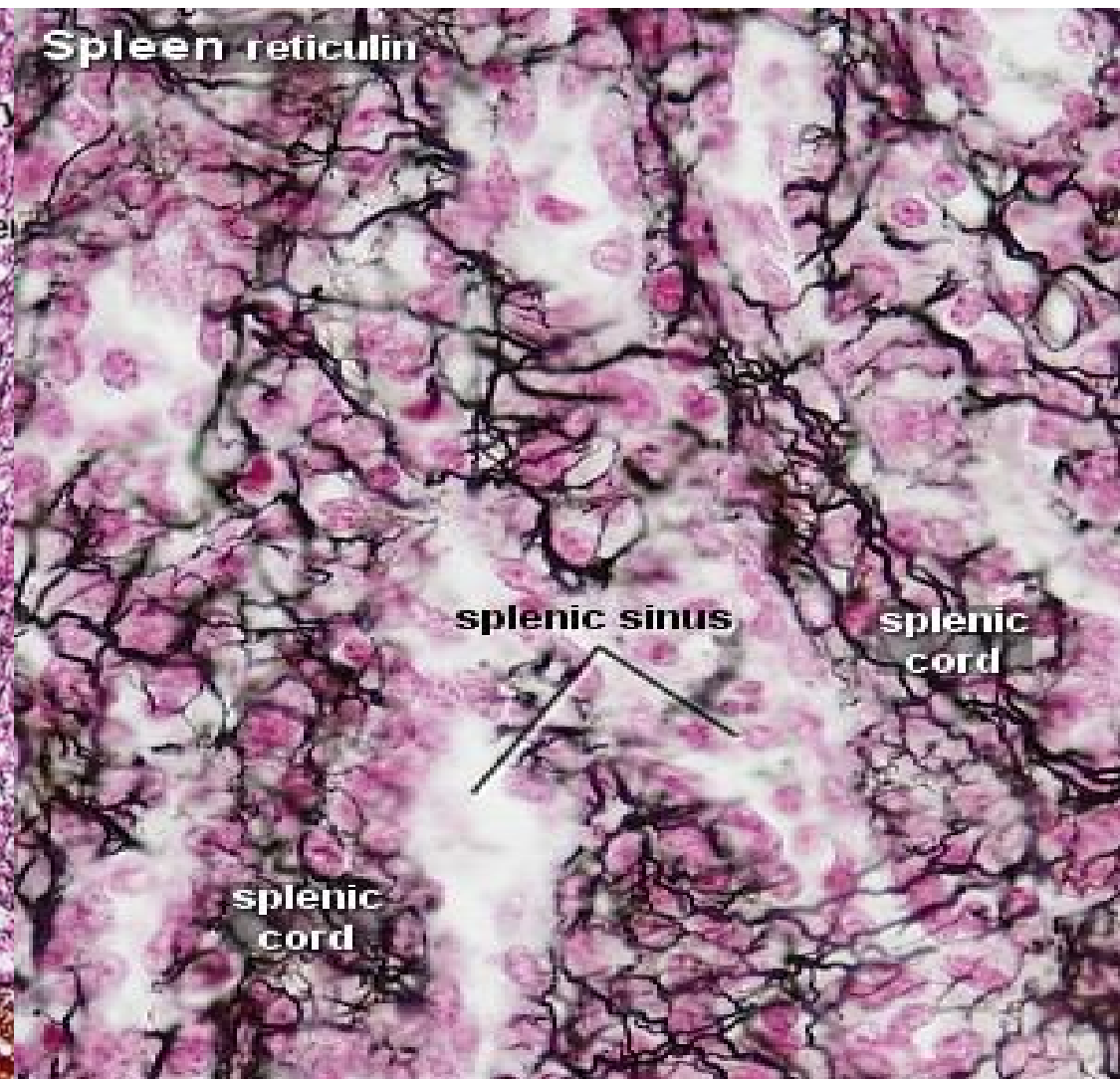
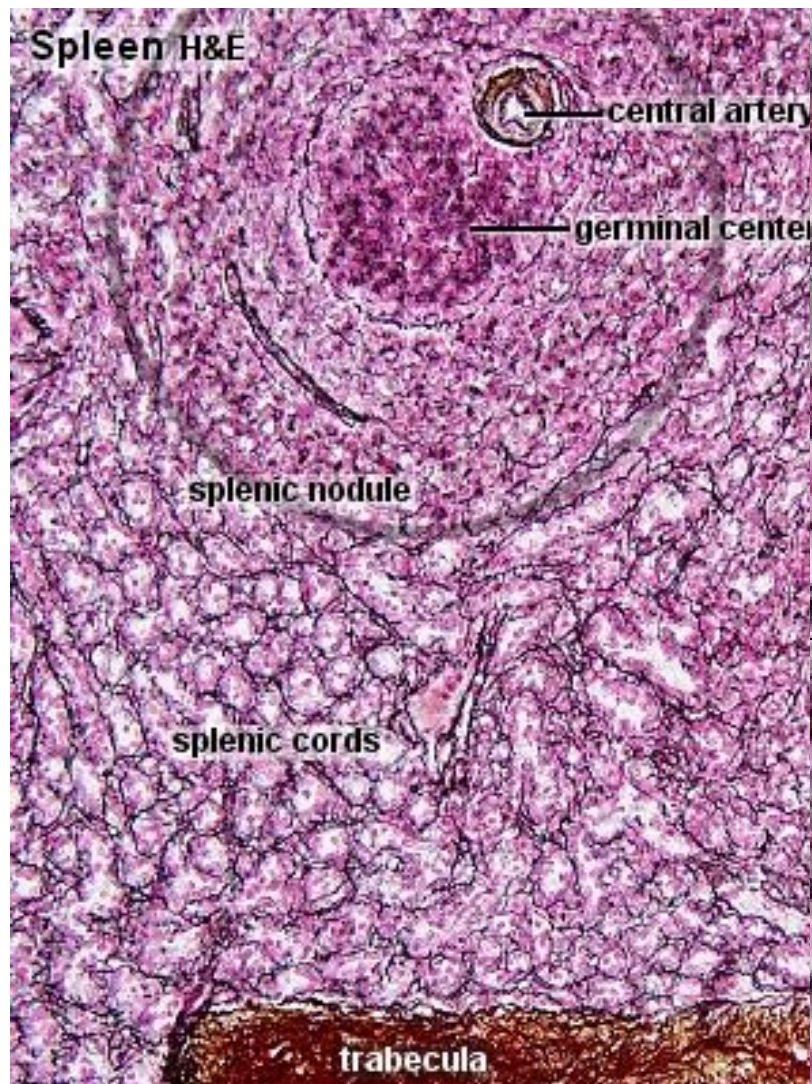


Figure 20.6a, b

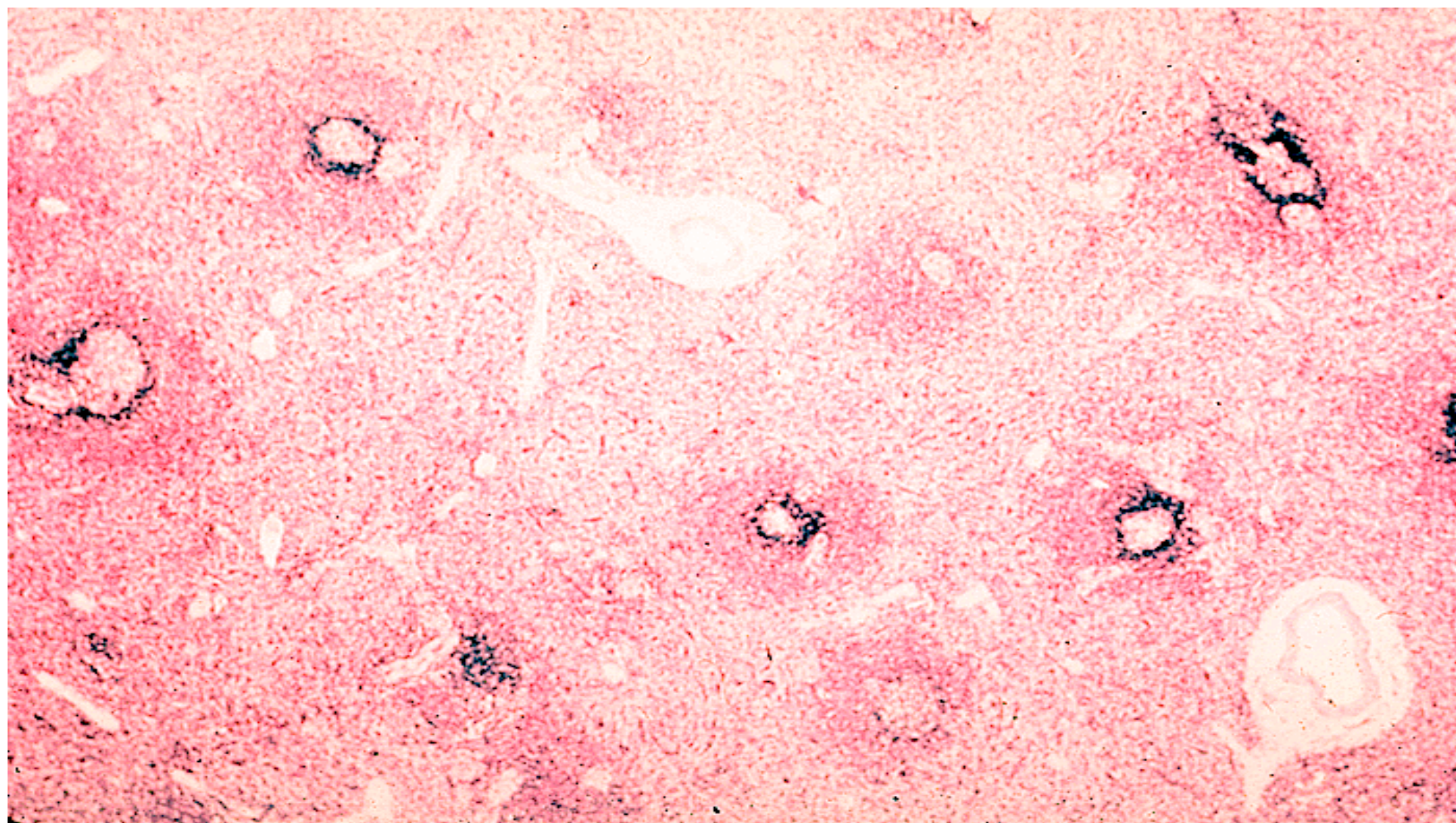




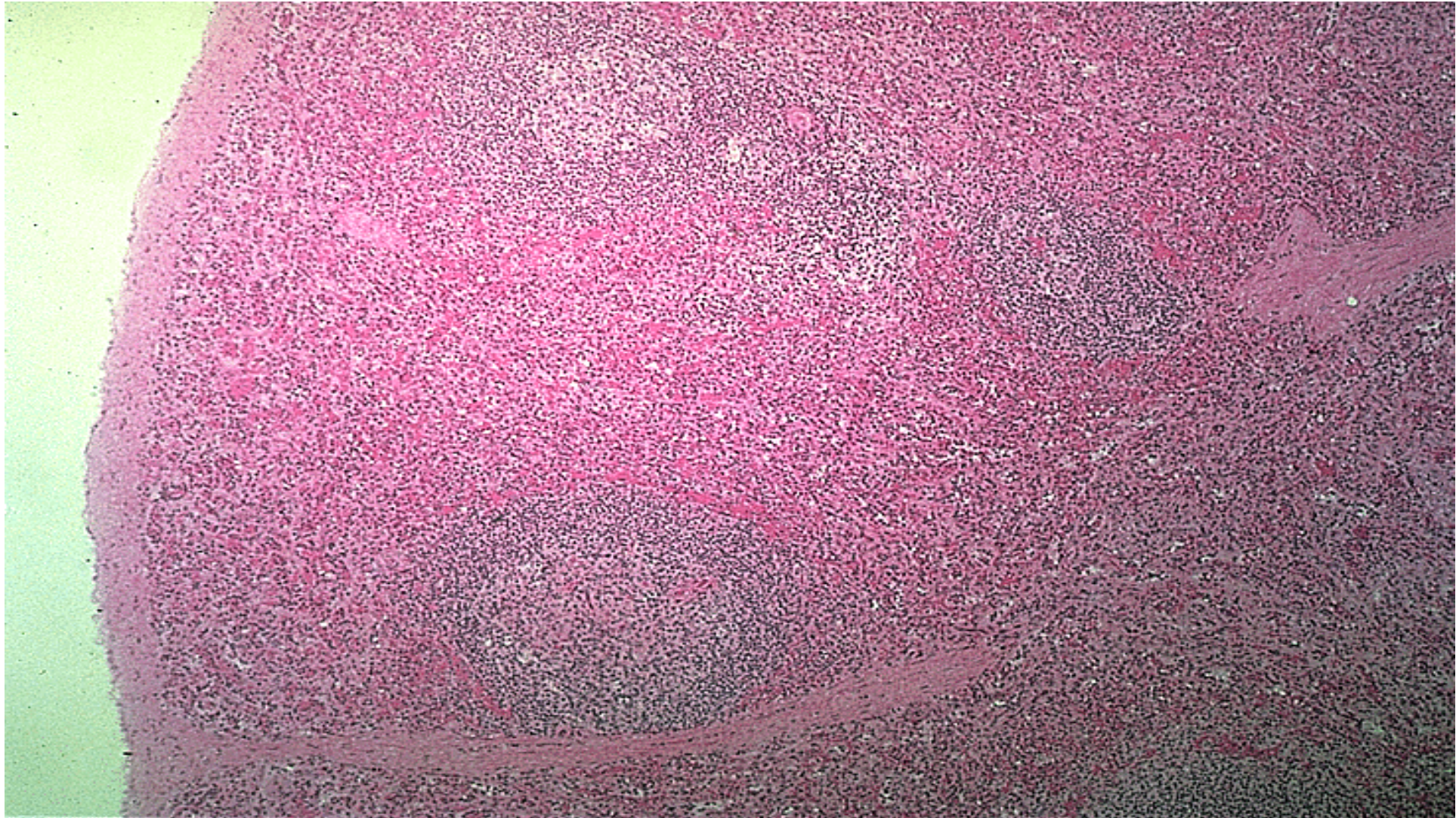






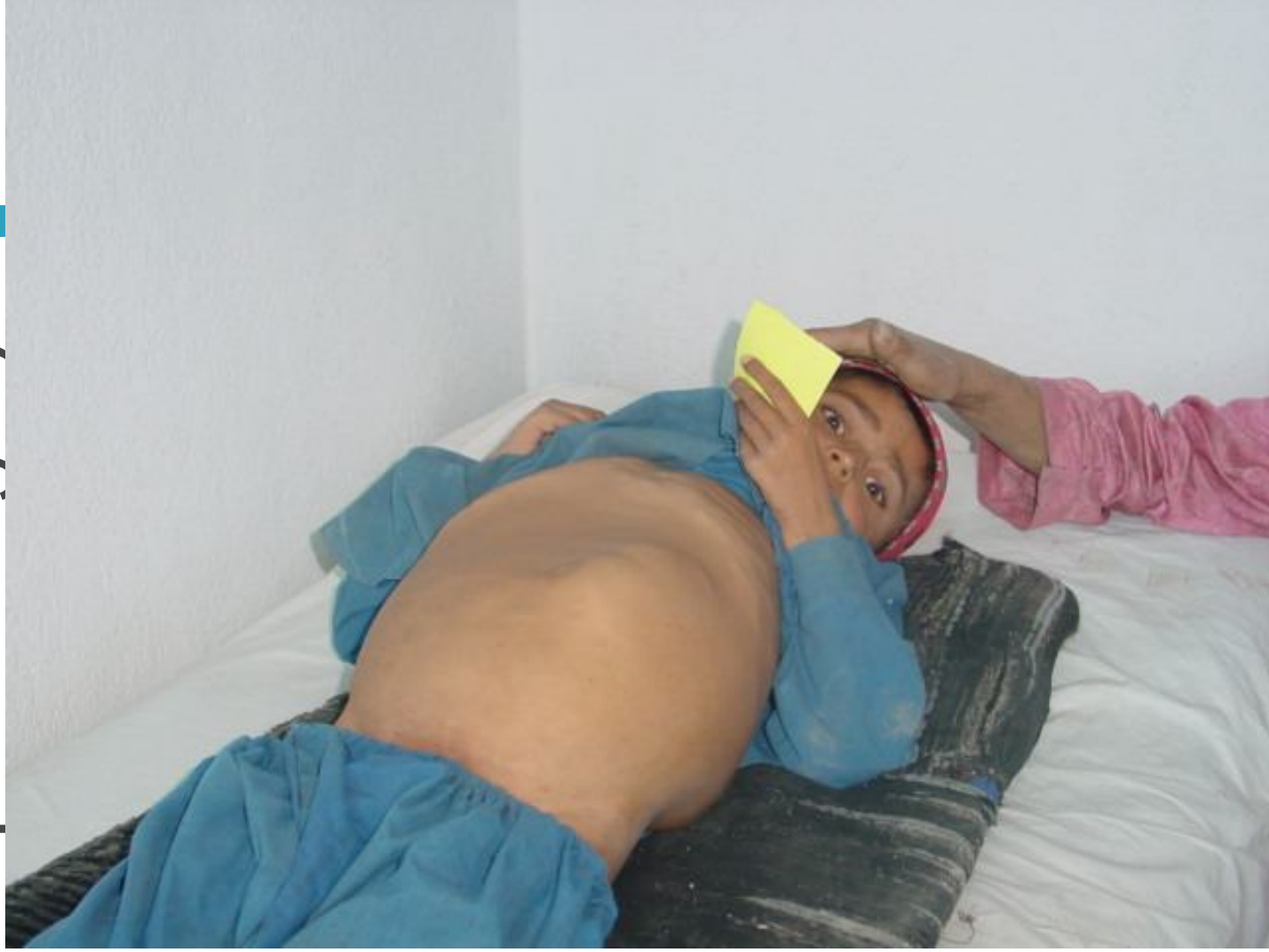





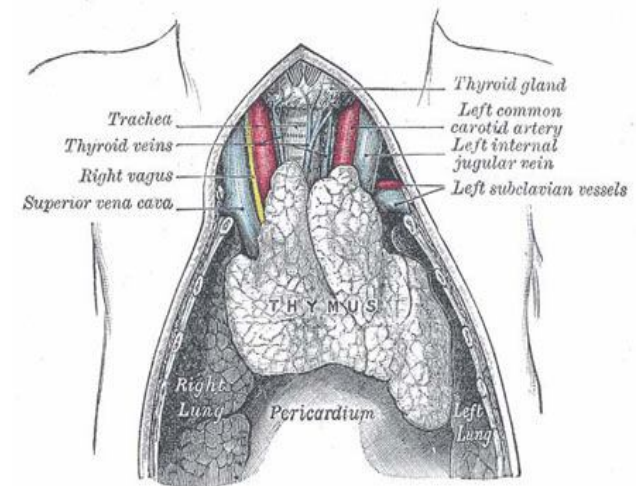
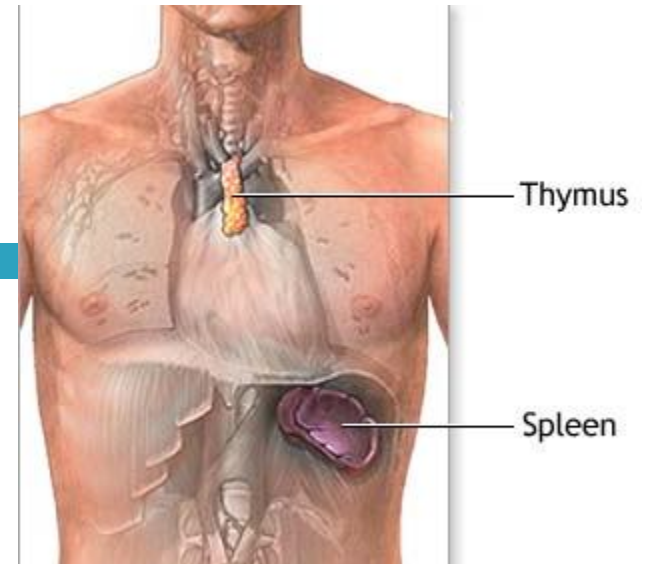


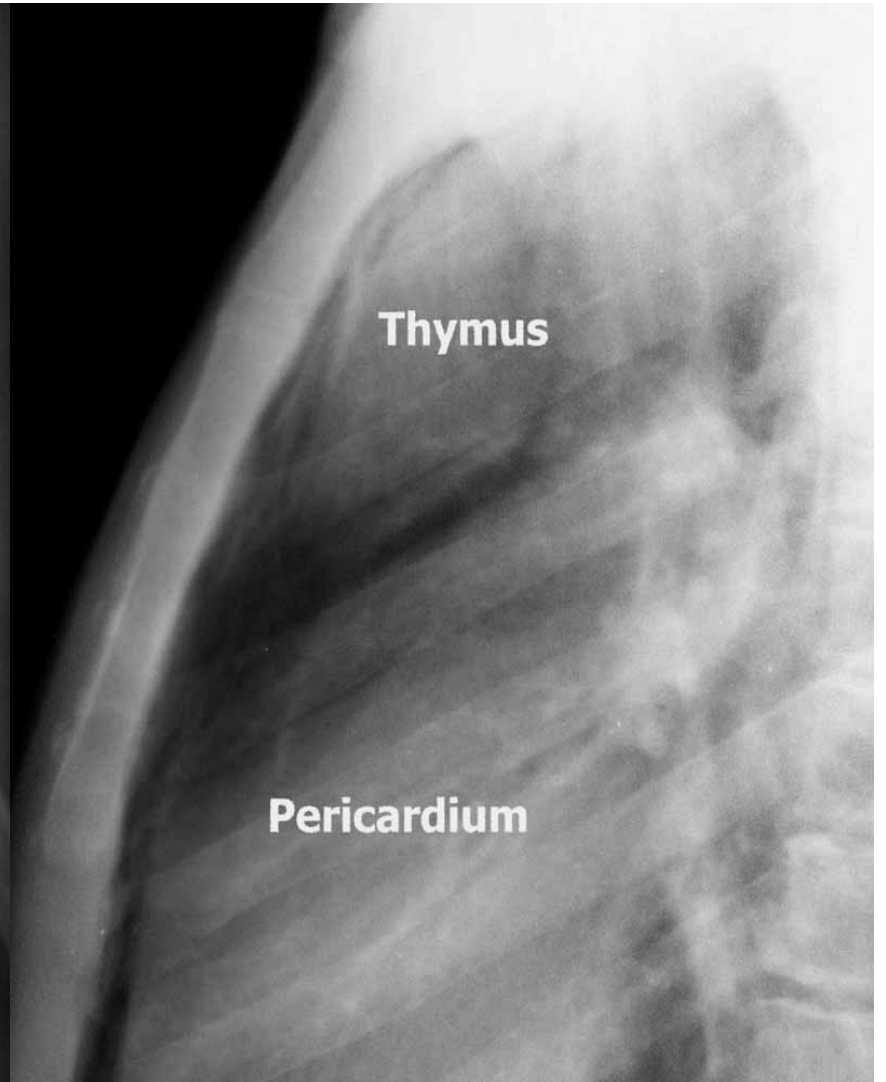
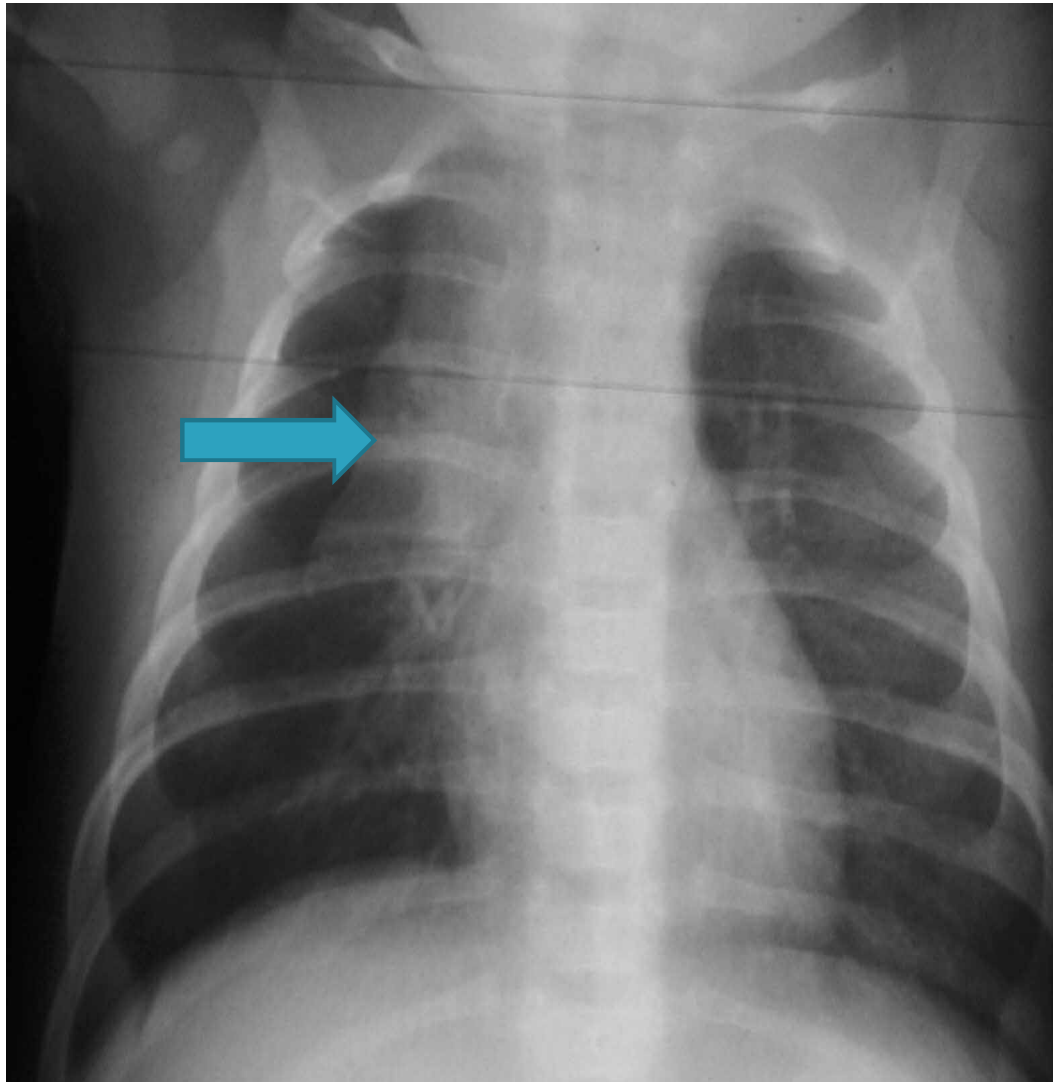
splenomegaly



# Thymus

- ❑ A bilobed organ that secretes hormones (thymosin and thymopoietin) that cause T lymphocytes to become immunocompetent
- ❑ Size of the thymus varies with age:
  - ▣ In infants, it is found in the inferior neck and extends into the mediastinum where it partially overlies the heart
  - ▣ It increases in size and is most active during childhood
  - ▣ It stops growing during adolescence and then gradually atrophies





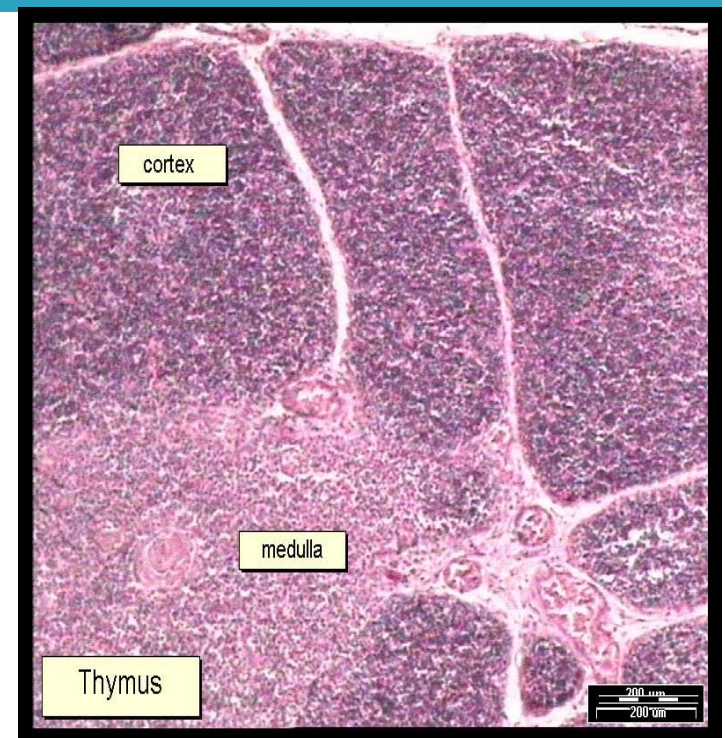
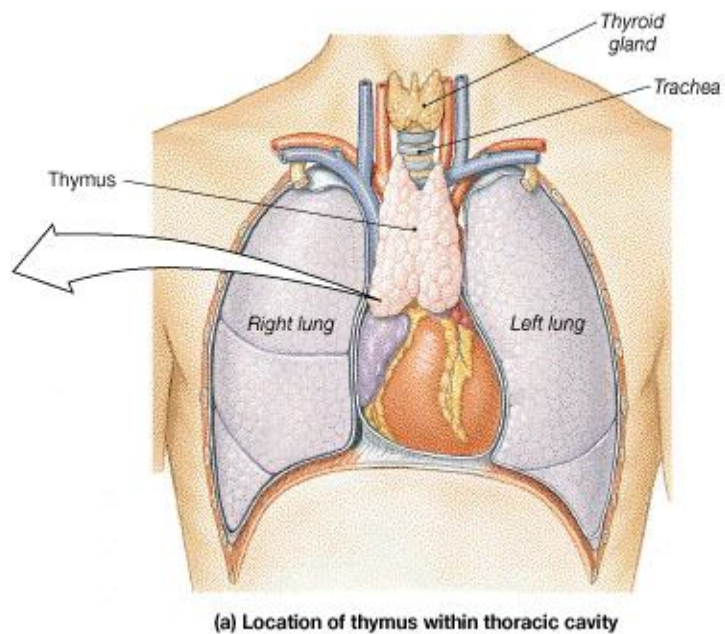
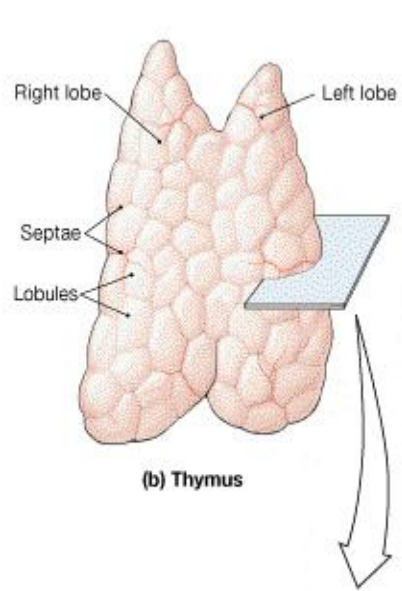
# Thymus Gland

---

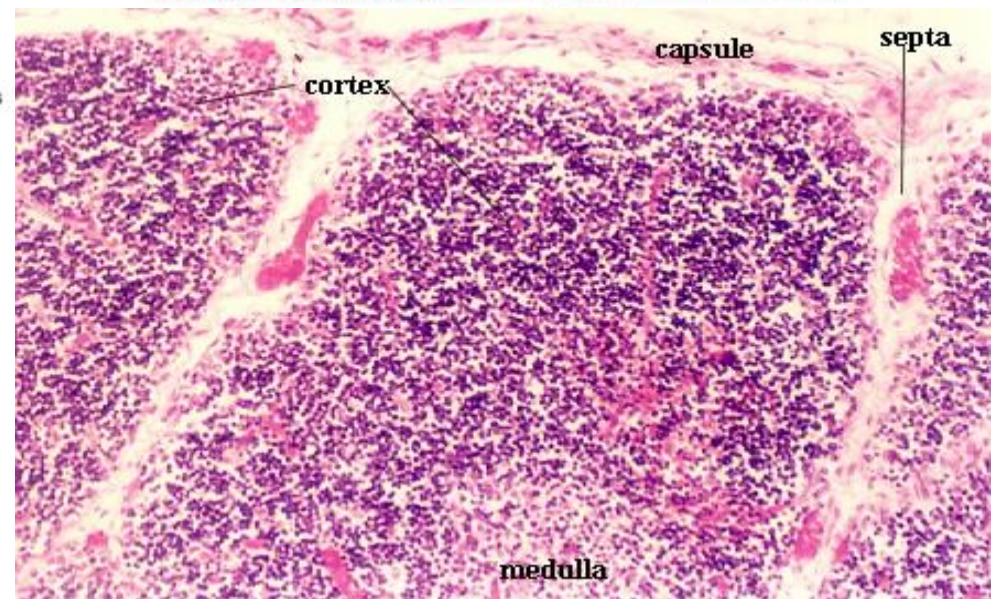
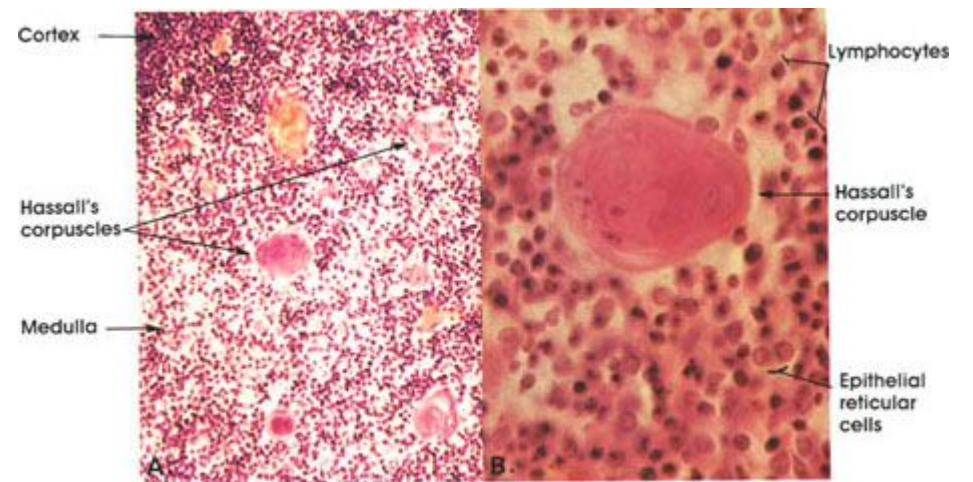
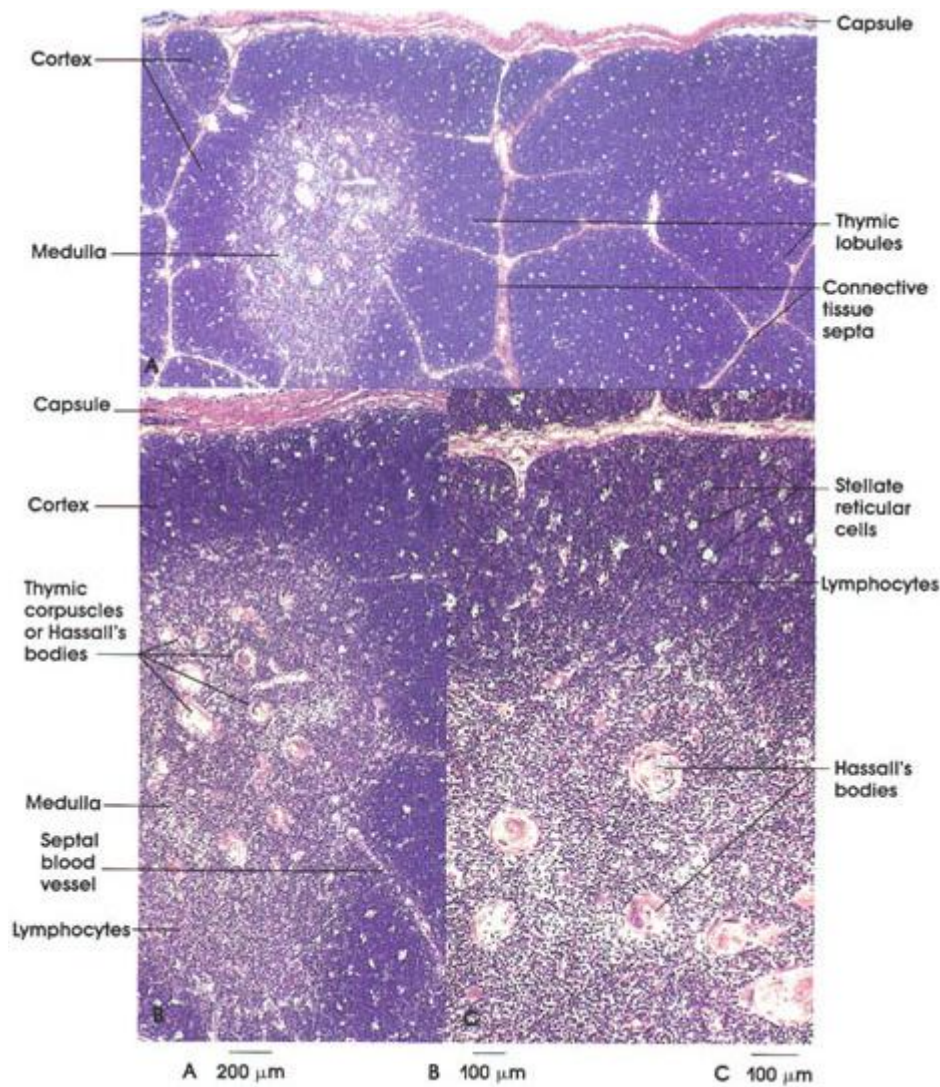
- ▣ Location – behind the sternum in the mediastinum
- ▣ The capsule divides it into 2 lobes
- ▣ Development
  - **Infant – conspicuous**
  - **Puberty – maximum size**
  - **Maturity – decreases in size**
- ▣ Function
  - **Differentiation and maturation of T cells**



# Thymus Gland







# Internal Anatomy of the Thymus

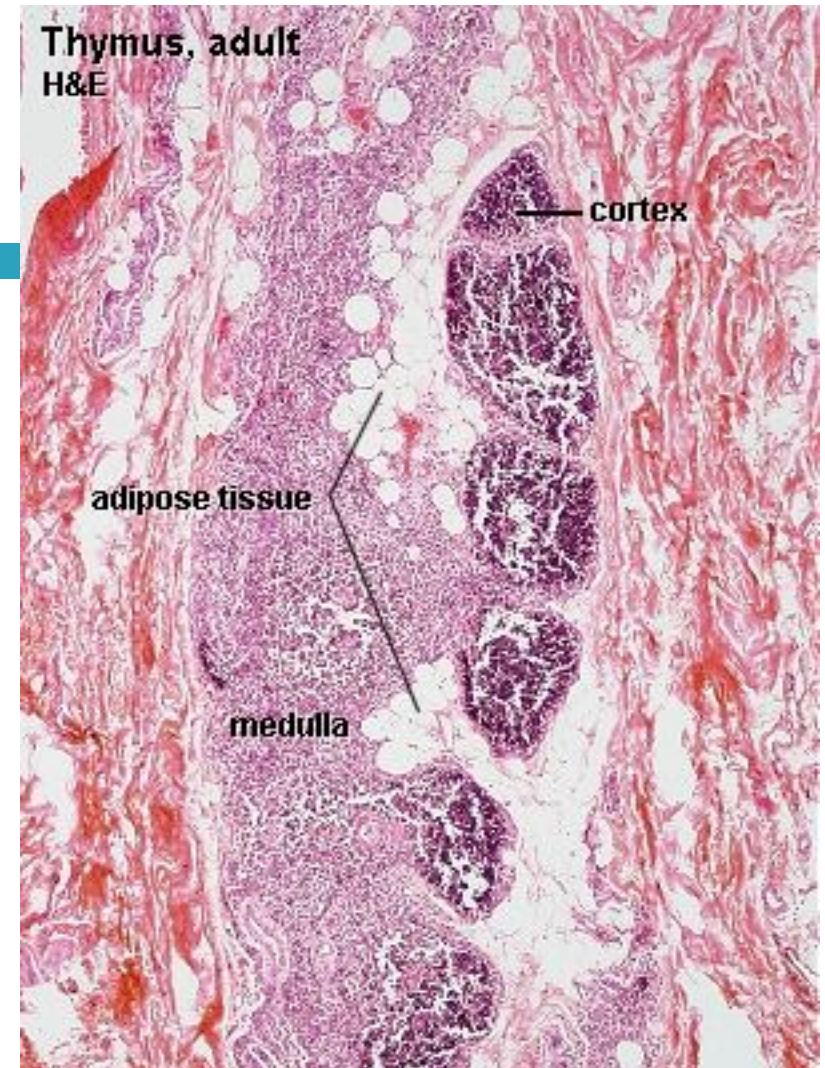
---

- ❑ Thymic lobes contain an outer cortex and inner medulla
- ❑ Cortex contains densely packed lymphocytes and scattered macrophages
- ❑ Medulla contains fewer lymphocytes and thymic (Hassall's) corpuscles



# Thymus

- The thymus differs from other lymphoid organs in important ways
  - ▣ **It functions strictly in T lymphocyte maturation**
  - ▣ **It does not directly fight antigens**
- The stroma of the thymus consists of star-shaped epithelial cells (not reticular fibers)
- These **thymocytes** secrete the hormones that stimulate lymphocytes to become immunocompetent





## Geography of the thymus: Thymic epithelial cells control the maturation of thymocytes

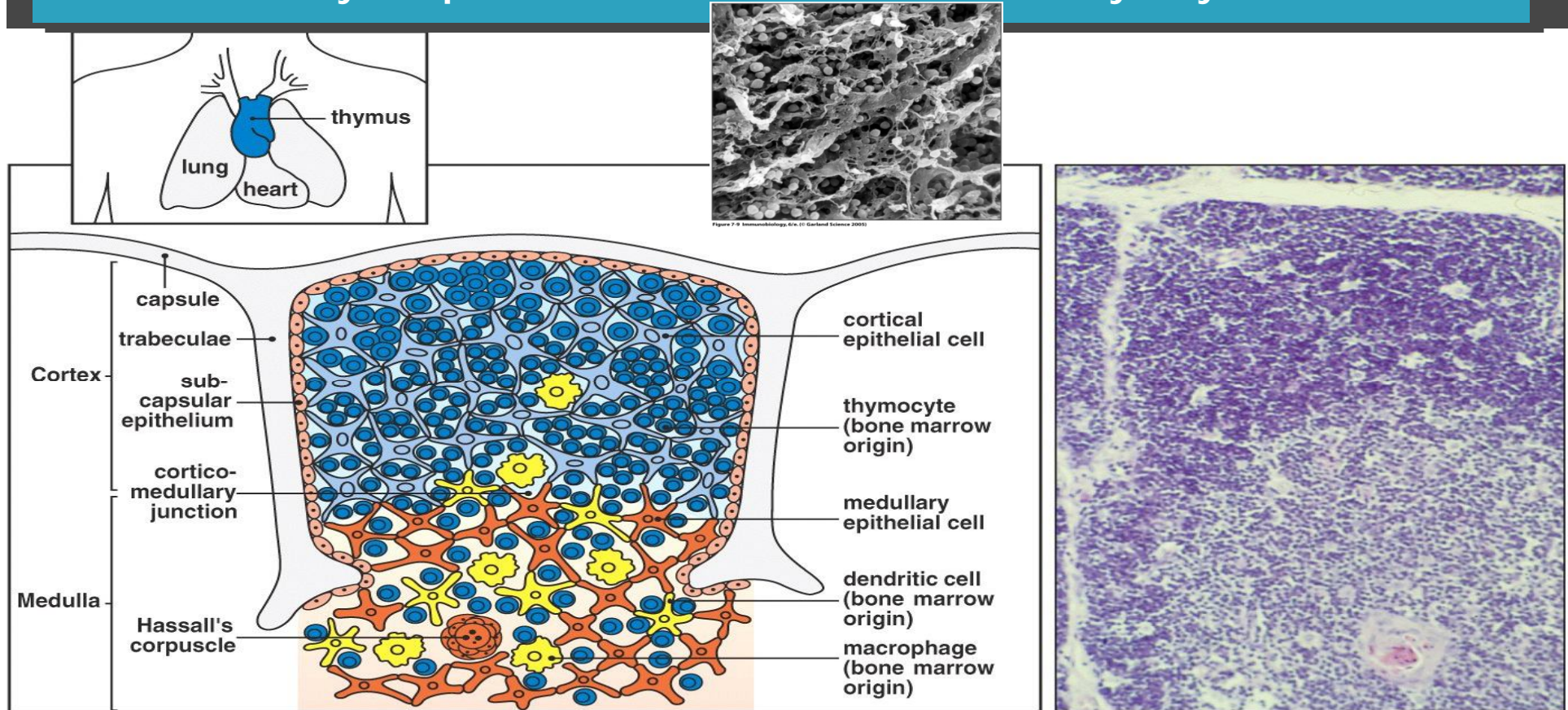
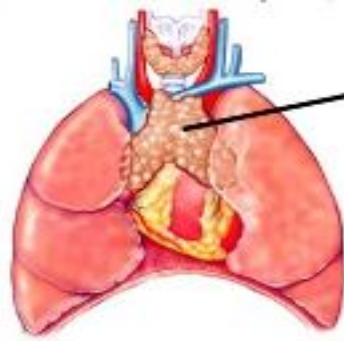

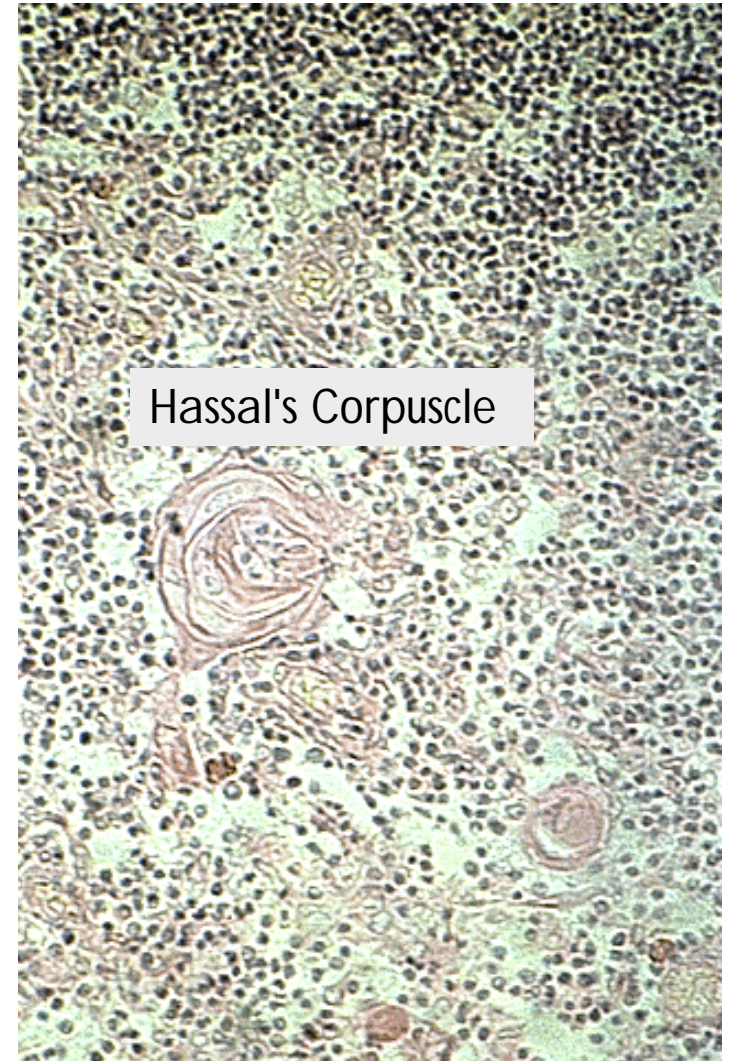
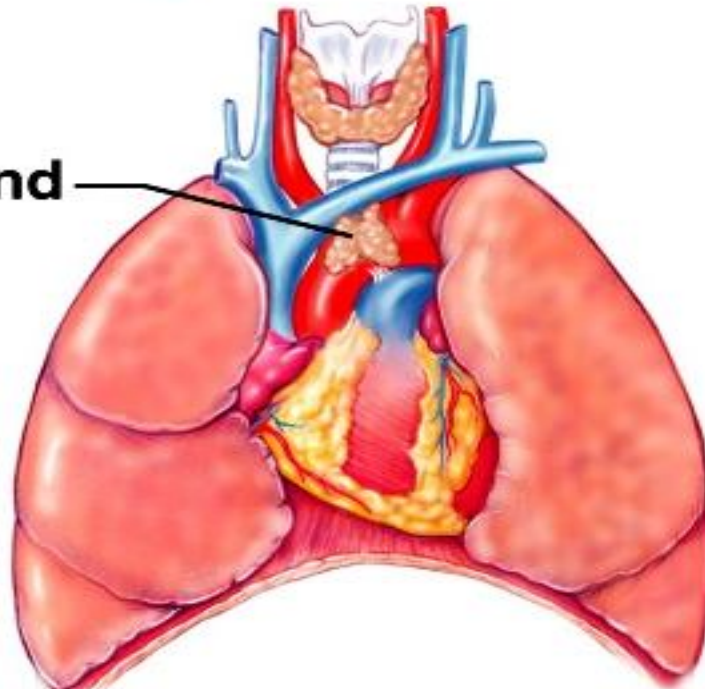
Figure 7-8 Immunobiology, 6/e. (© Garland Science 2005)





**Thymus gland  
in fetus**

**Thymus gland  
in adult**

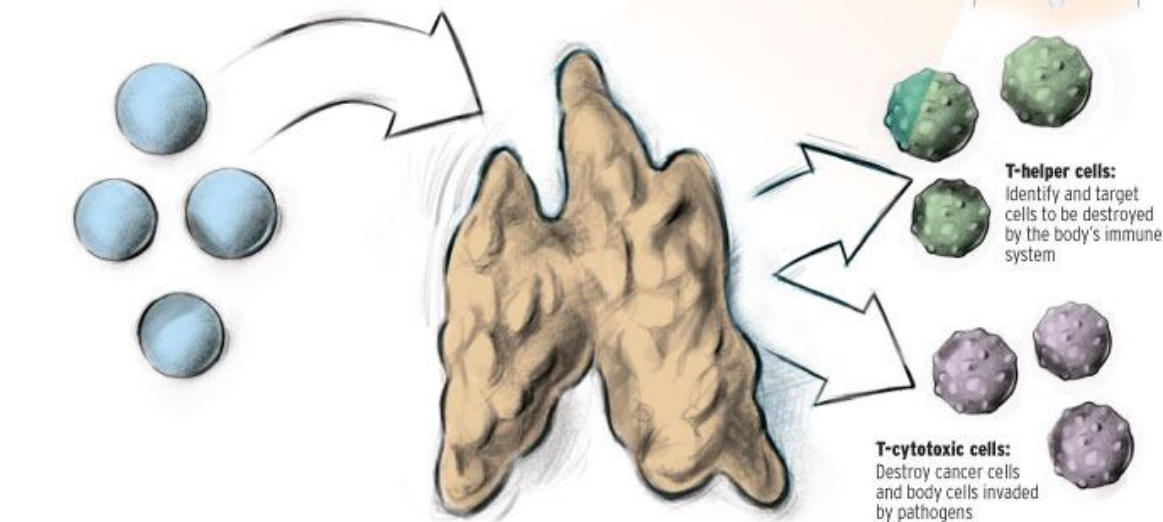


Hassal's Corpuscle



## THE THYMUS' ROLE IN T-CELL PRODUCTION

T-cells are a group of white blood cells that are "trained" in the thymus gland to find and destroy invading threats such as viruses and bacteria. T-cells identify their targets using chemical markers that protrude from their cell walls, and it's in the thymus that these markers are set. In children born without a thymus, white blood cells don't go through this process, leaving the body without a defense system. Here's how the process works.



### Precursor T-cells

T-cell precursors, which are produced in bone marrow, do not have any markers on their surface. Without these markers, they don't fight disease. These immature cells find their way ...

### Thymus

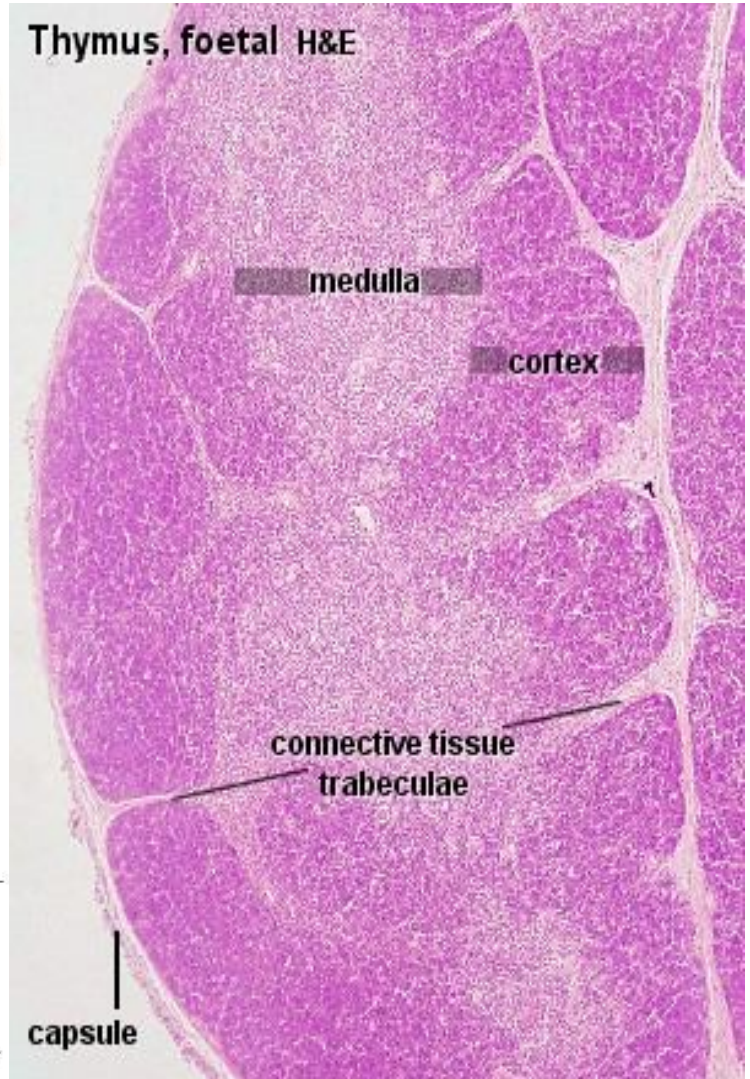
... to the thymus where they go through many generations of cell division, gradually acquiring the chemical markers that will make them active in the body.

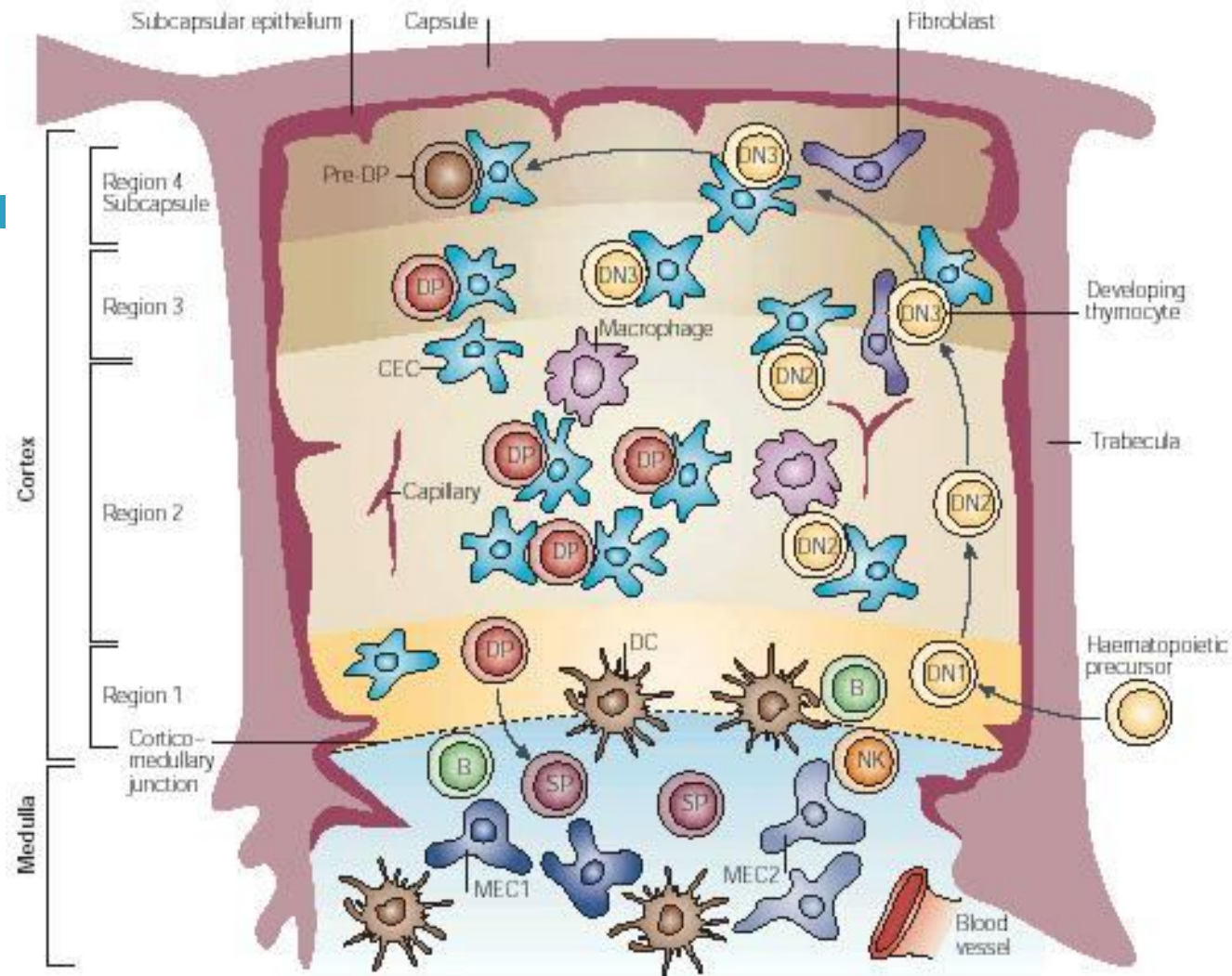
### Mature T-cells

In the end, several sub-types of T-cells are created, primarily T-helper and T-cytotoxic cells, each serving a different purpose in the immune system.

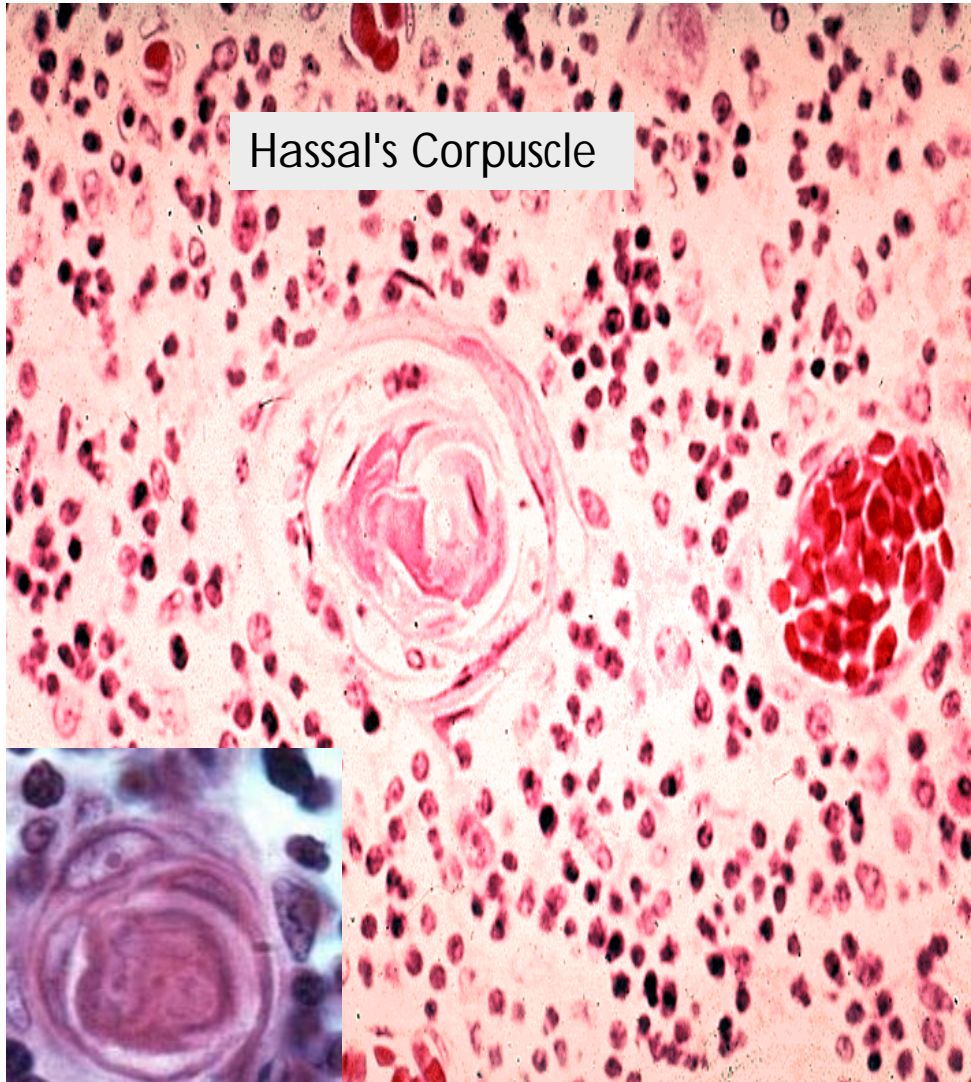Sources: britannica.com, wikipedia.org, daviddarling.info/

JUDSON DRENNAN & TIM LEE / The News & Observer









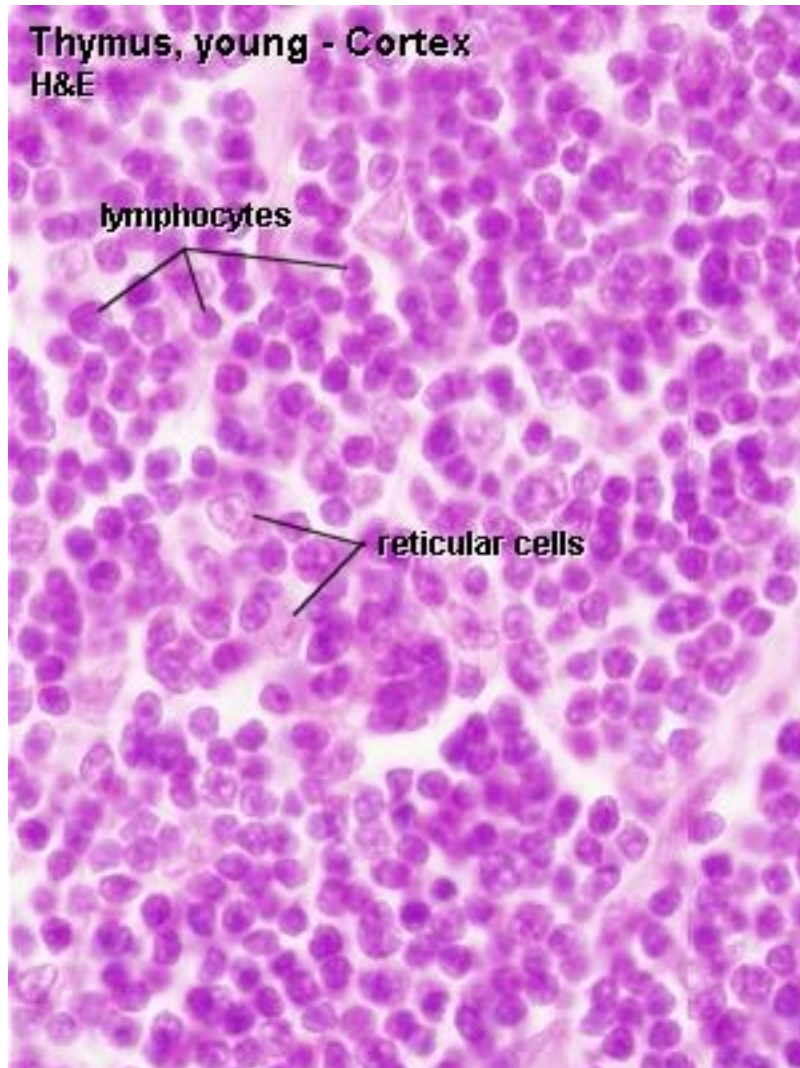
**Hassall's corpuscles** (or **thymic corpuscles**) are structures found in the medulla of the human thymus, formed from type VI epithelial reticular cells.

The function of Hassall's corpuscles is currently unclear, and the absence of this structure in the murine thymus has restricted mechanistic dissection.

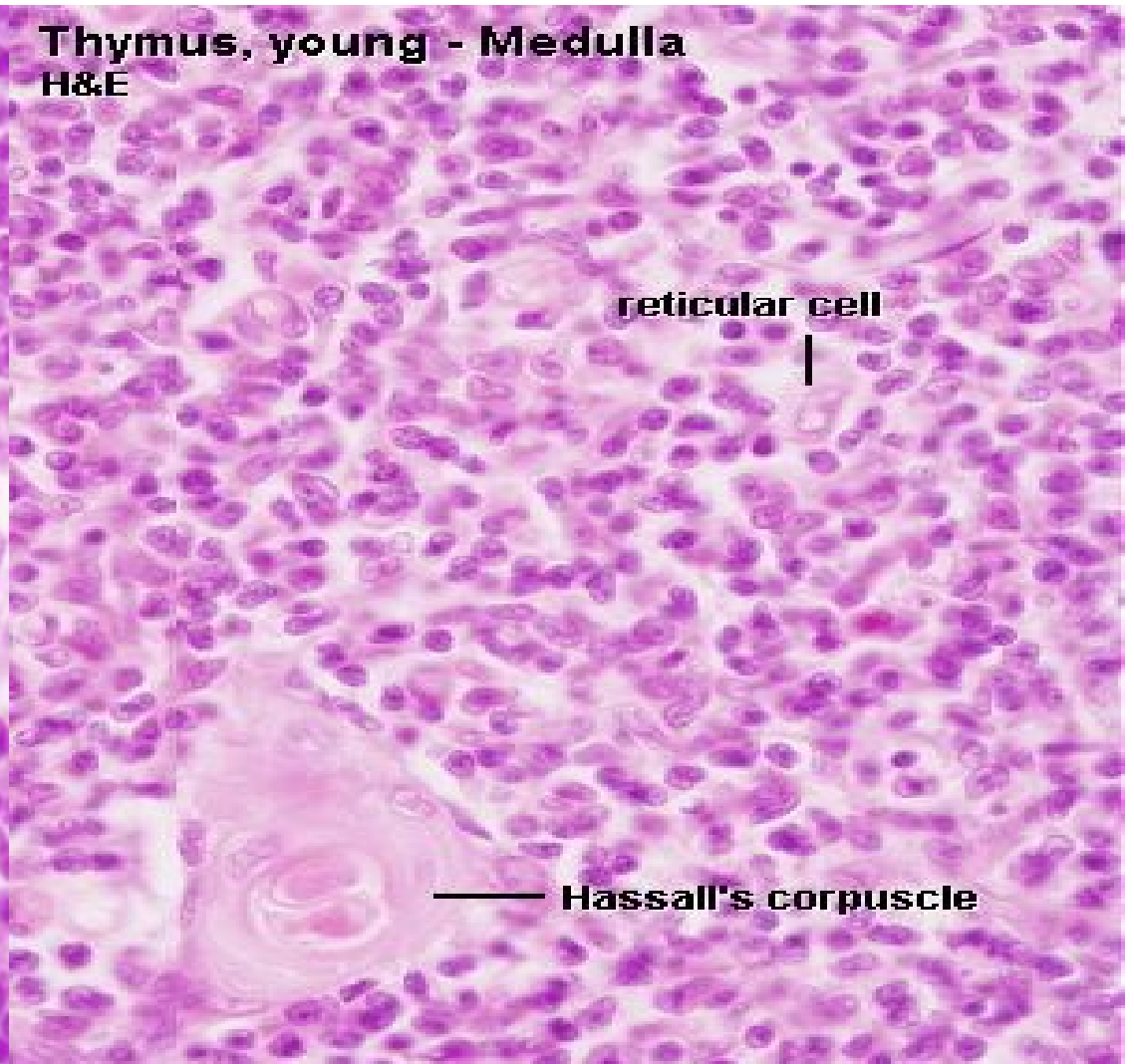
It is known that Hassall's corpuscles are a potent source of the cytokine TSLP. *In vitro*, TSLP directs the maturation of dendritic cells, and increases the ability of dendritic cells to convert naive thymocytes to a Foxp3<sup>+</sup> regulatory T cell lineage.

It is unknown if this is the physiological function of Hassall's corpuscles *in vivo*.

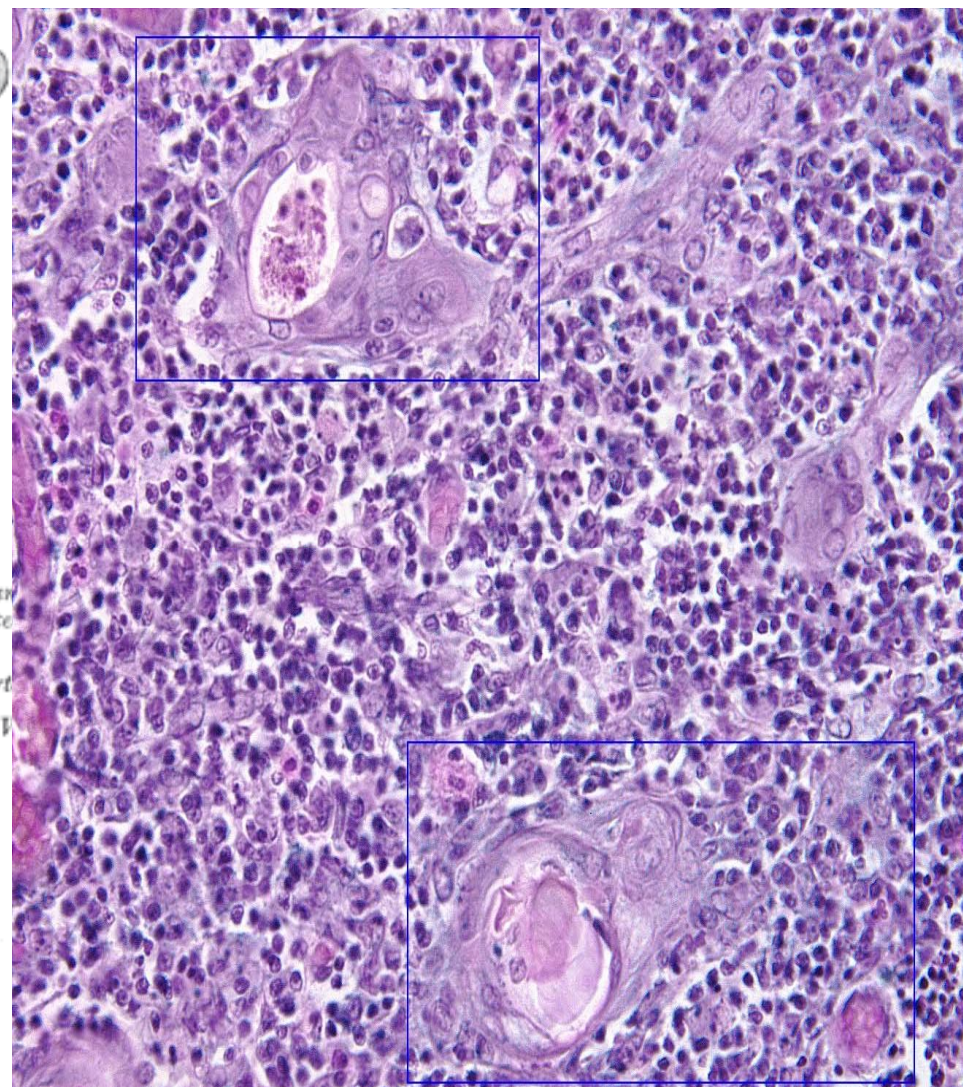
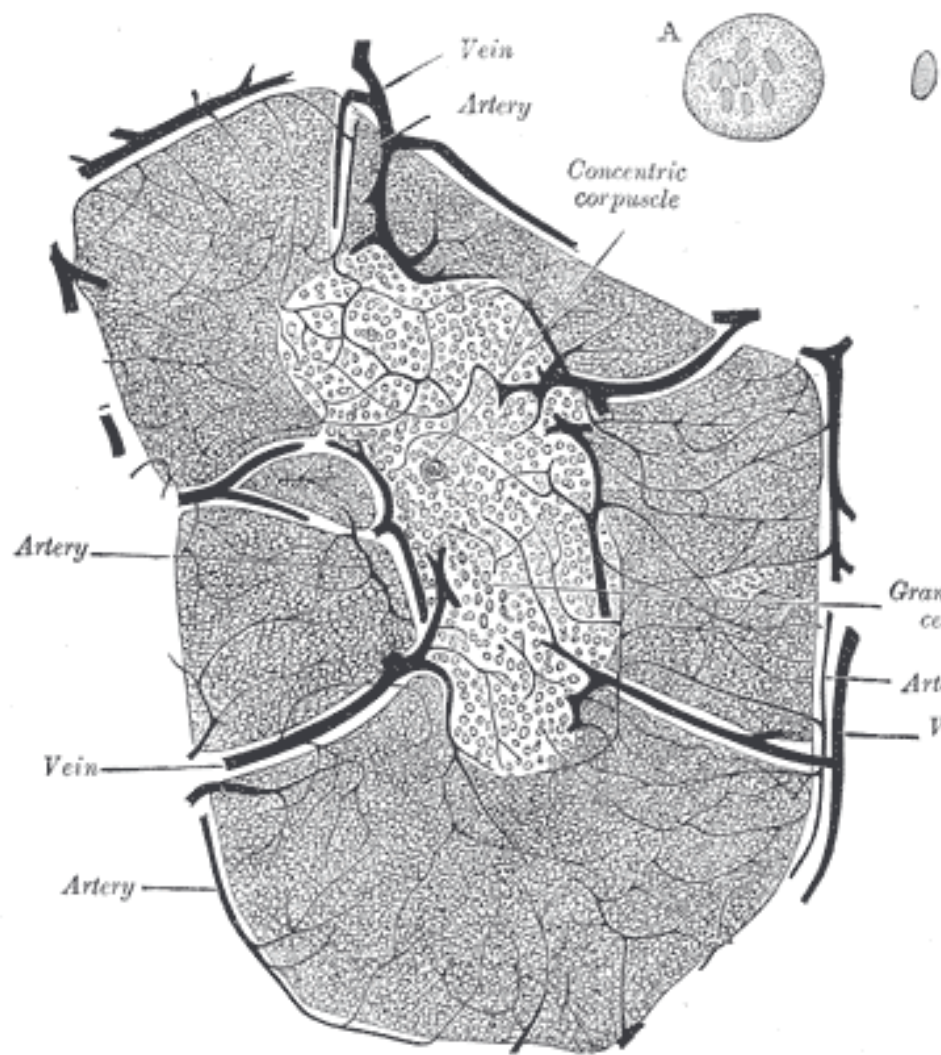
**Thymus, young - Cortex**  
H&E



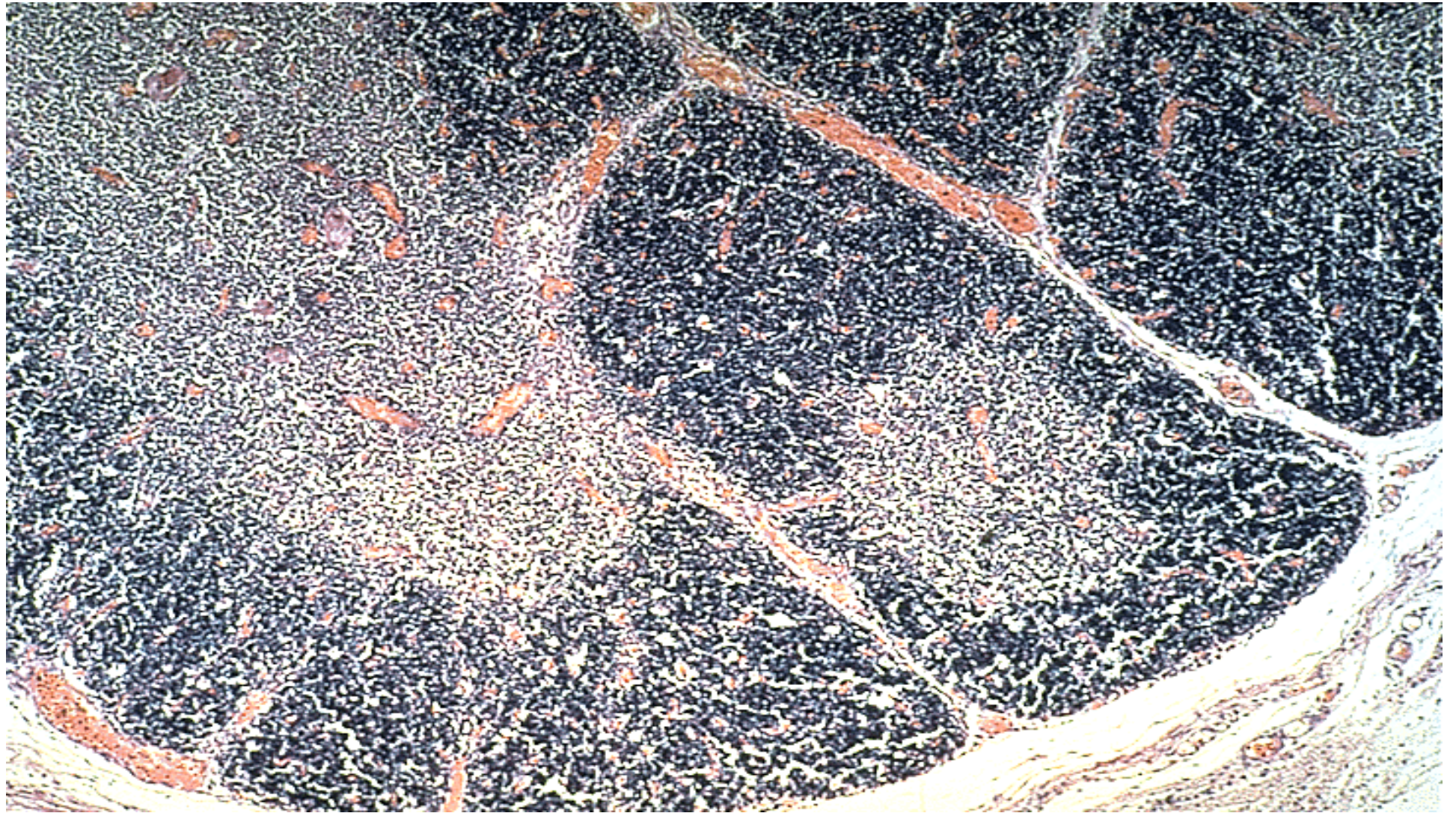
**Thymus, young - Medulla**  
H&E











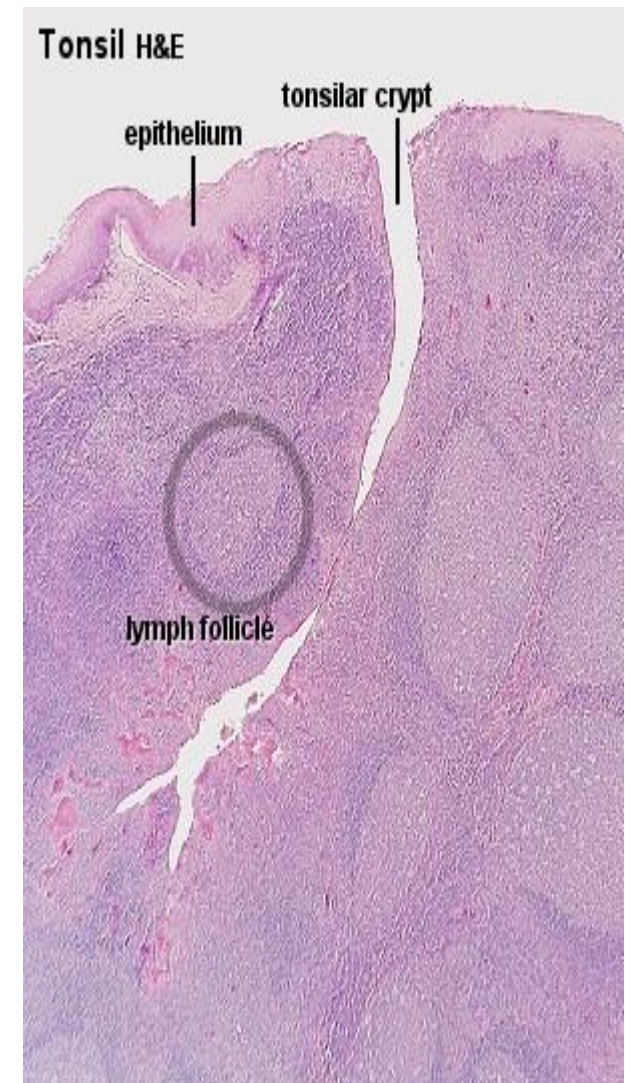


# Tonsils

---

- Simplest lymphoid organs; form a ring of lymphatic tissue around the pharynx
- Location:
  - ▣ Palatine tonsils – either side of the posterior end of the oral cavity
  - ▣ Lingual tonsils – lie at the base of the tongue
  - ▣ Pharyngeal tonsil – posterior wall of the nasopharynx
  - ▣ Tubal tonsils – surround the openings of the auditory tubes into the pharynx

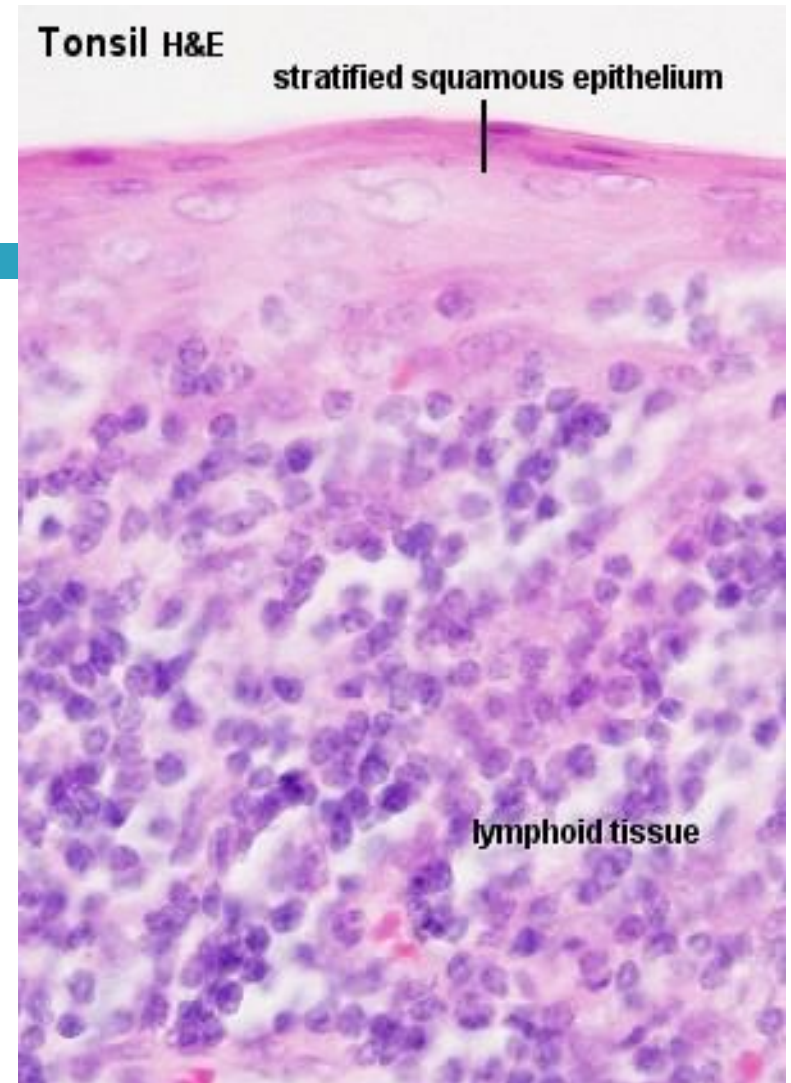
- Depending on their localisation we distinguish between
- palatine tonsils (THE tonsils), which are located in the lateral wall of the oropharynx and covered by a stratified squamous epithelium,
- lingual tonsils which are situated in the lamina propria at the root of the tongue and also covered by a stratified squamous epithelium, and
- pharyngeal tonsils (also called nasopharyngeal tonsils or adenoids) which are located in the upper posterior part of the throat (nasopharynx) and covered by a pseudostratified ciliated epithelium with goblet cells.
- **The tonsils do not have afferent lymph vessels. Efferent lymph vessels are present.**



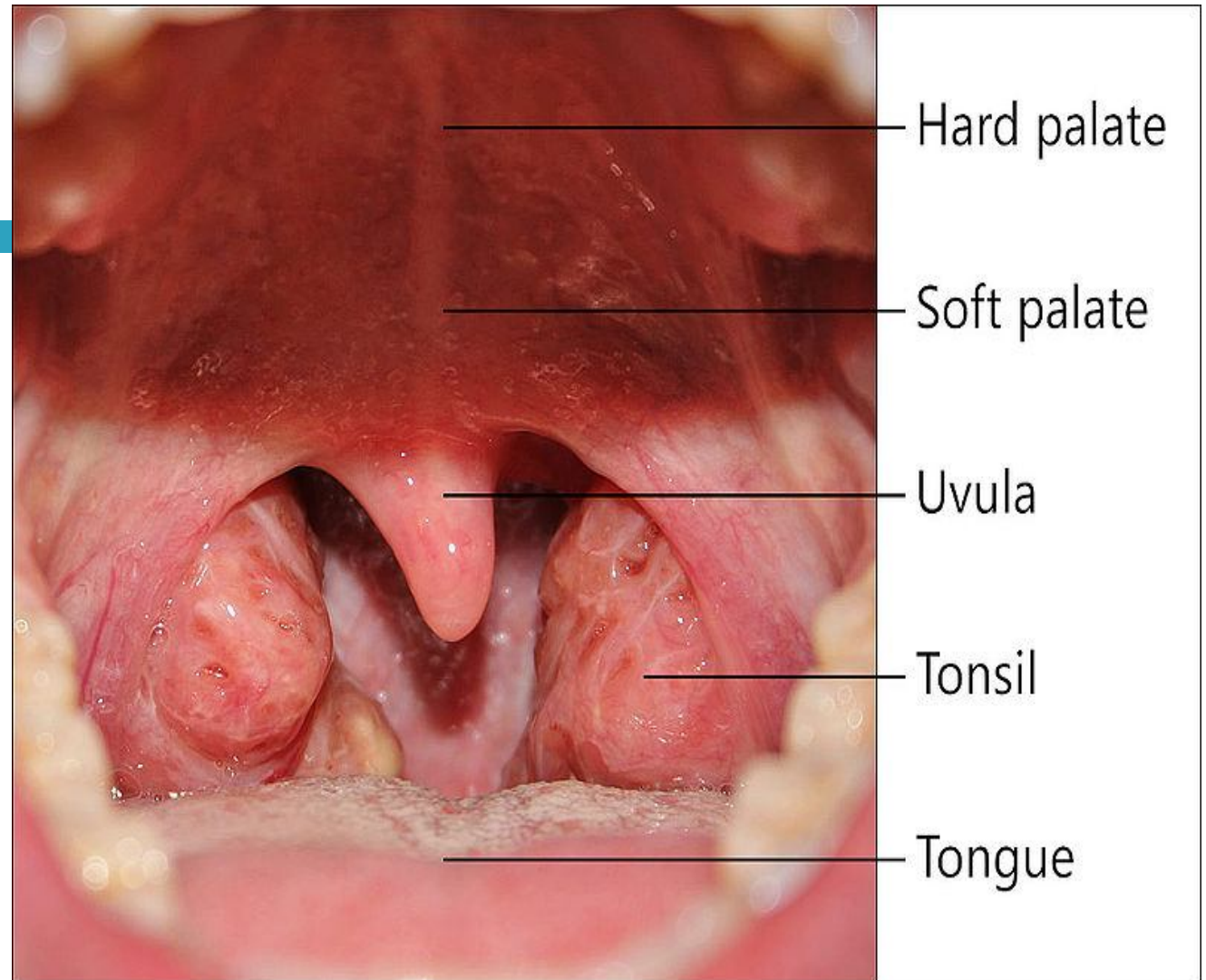
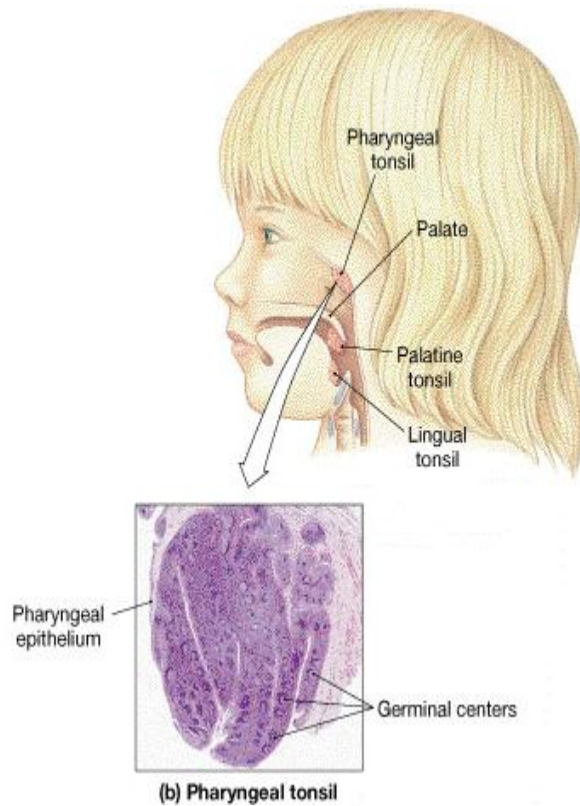


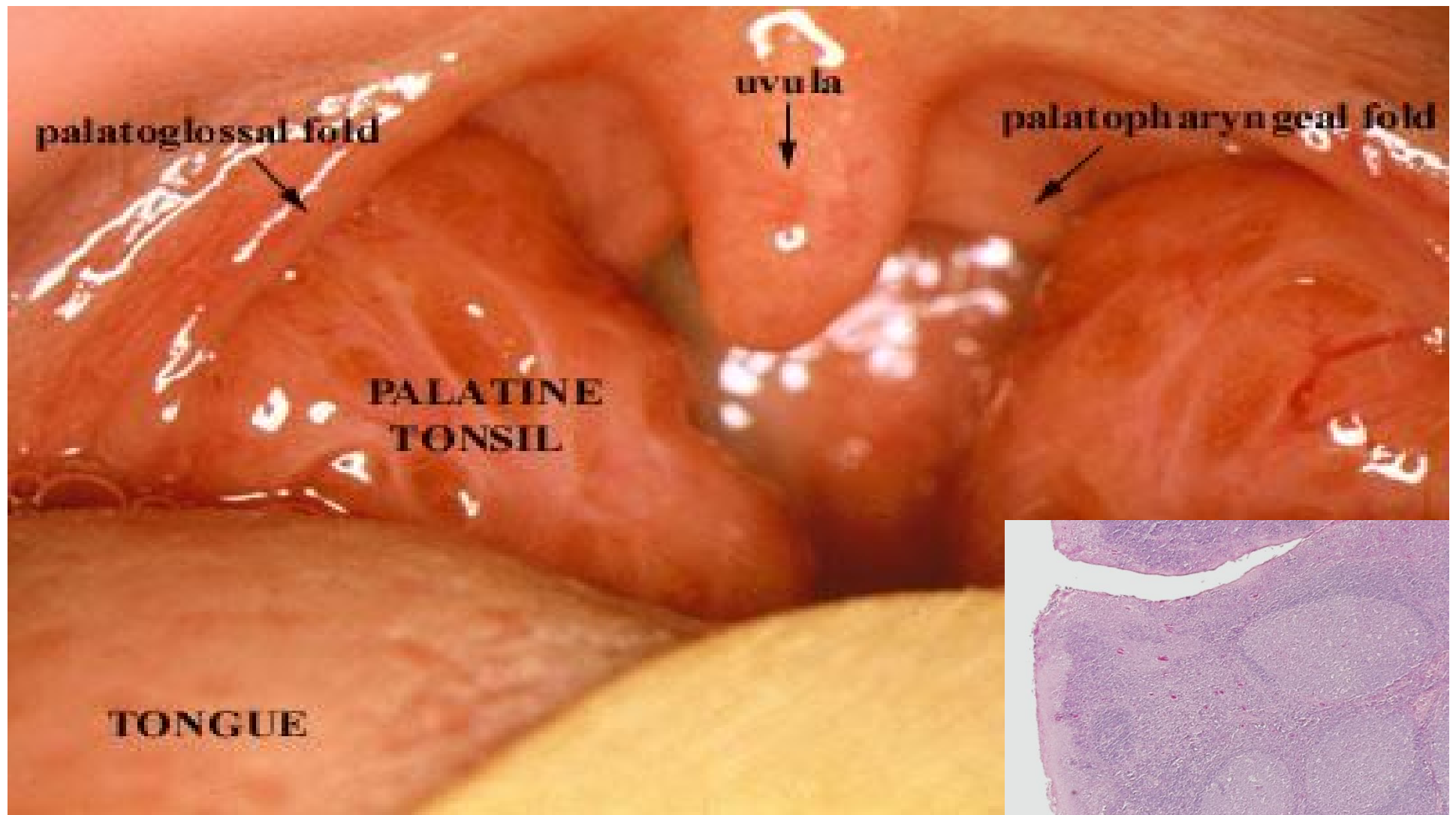
# Tonsils

- Lymphoid tissue of tonsils contains follicles with germinal centers
- Tonsil masses are not fully encapsulated
- Epithelial tissue overlying tonsil masses invaginates, forming blind-ended crypts
- Crypts trap and destroy bacteria and particulate matter



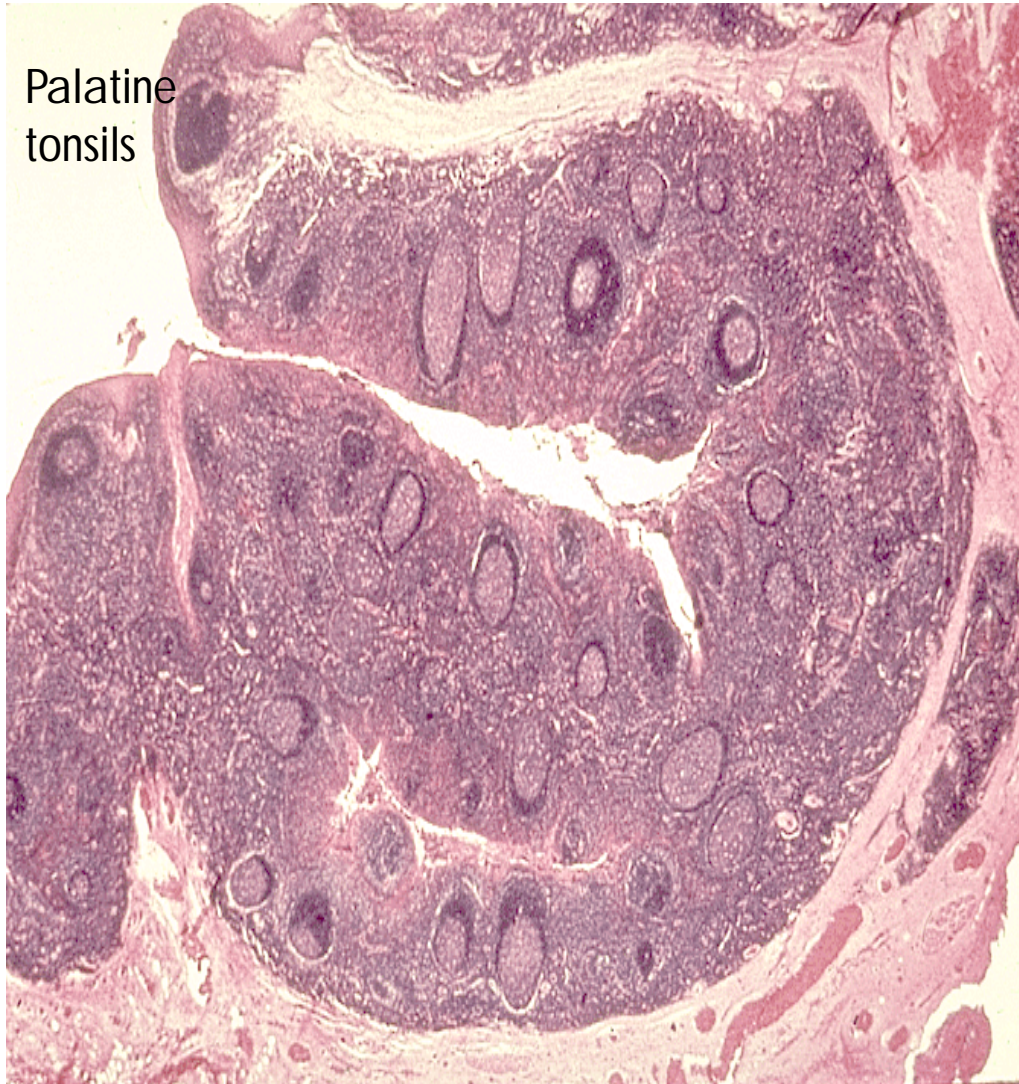
# Tonsils



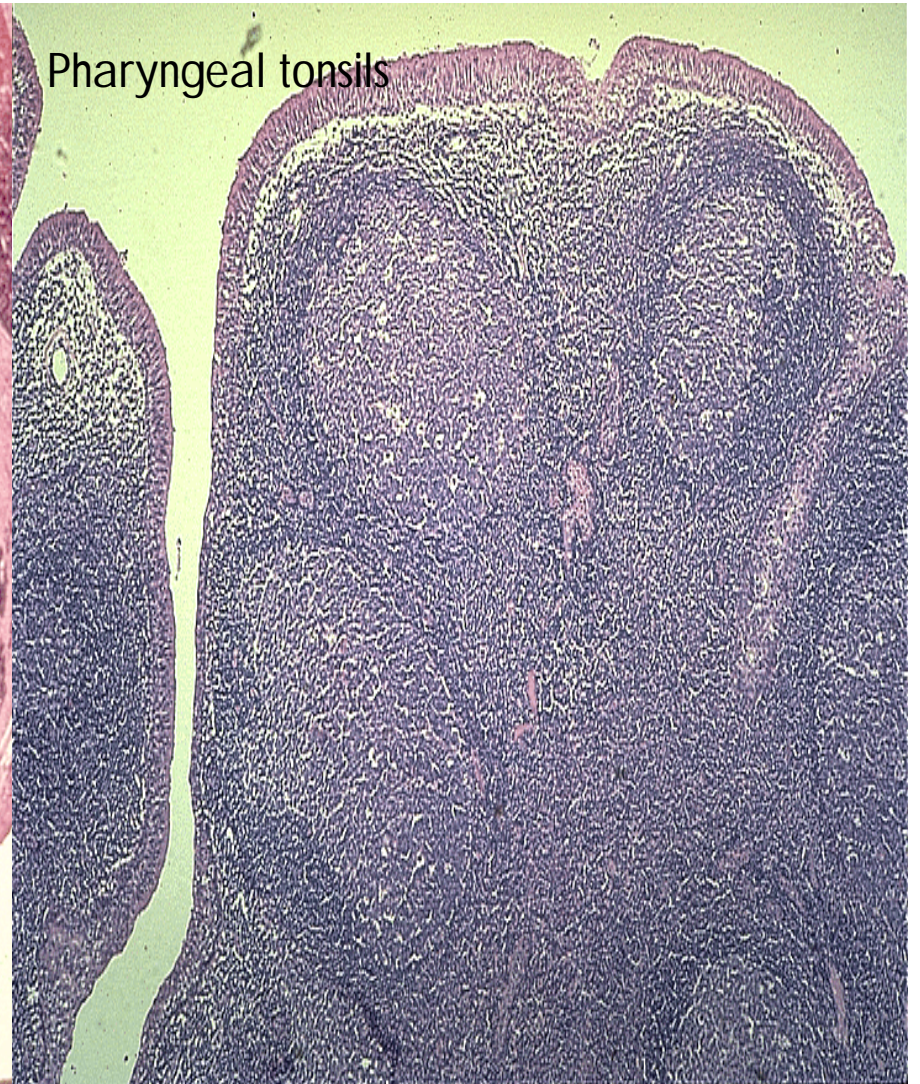




Palatine  
tonsils



Pharyngeal tonsils

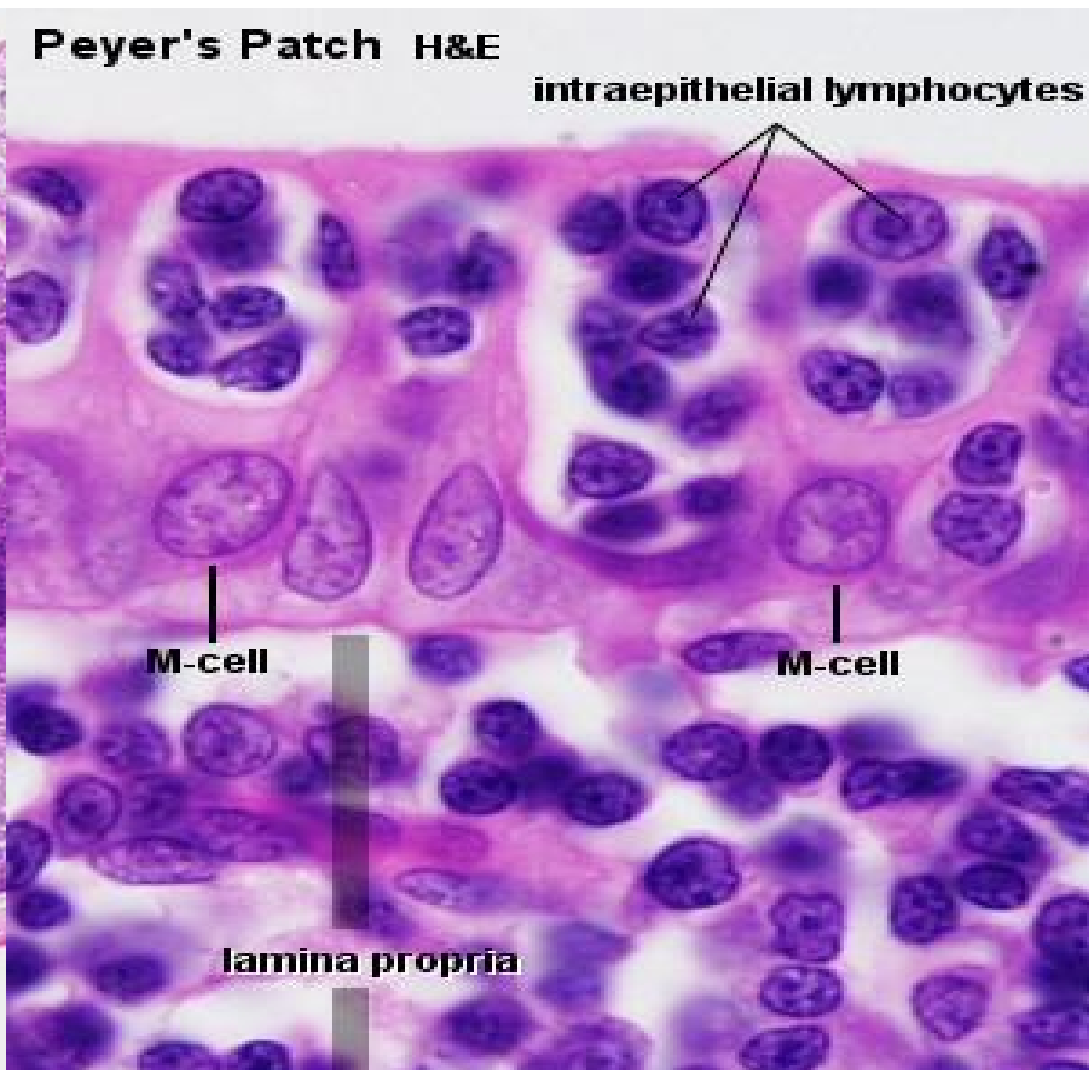
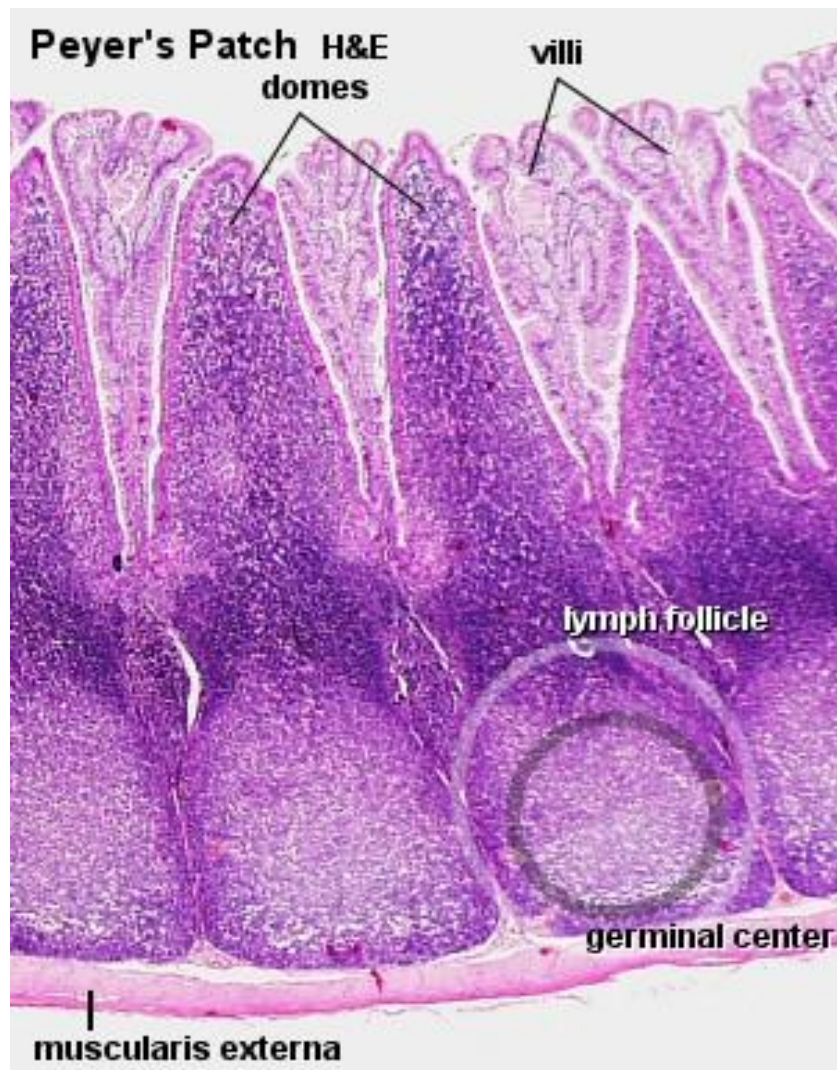



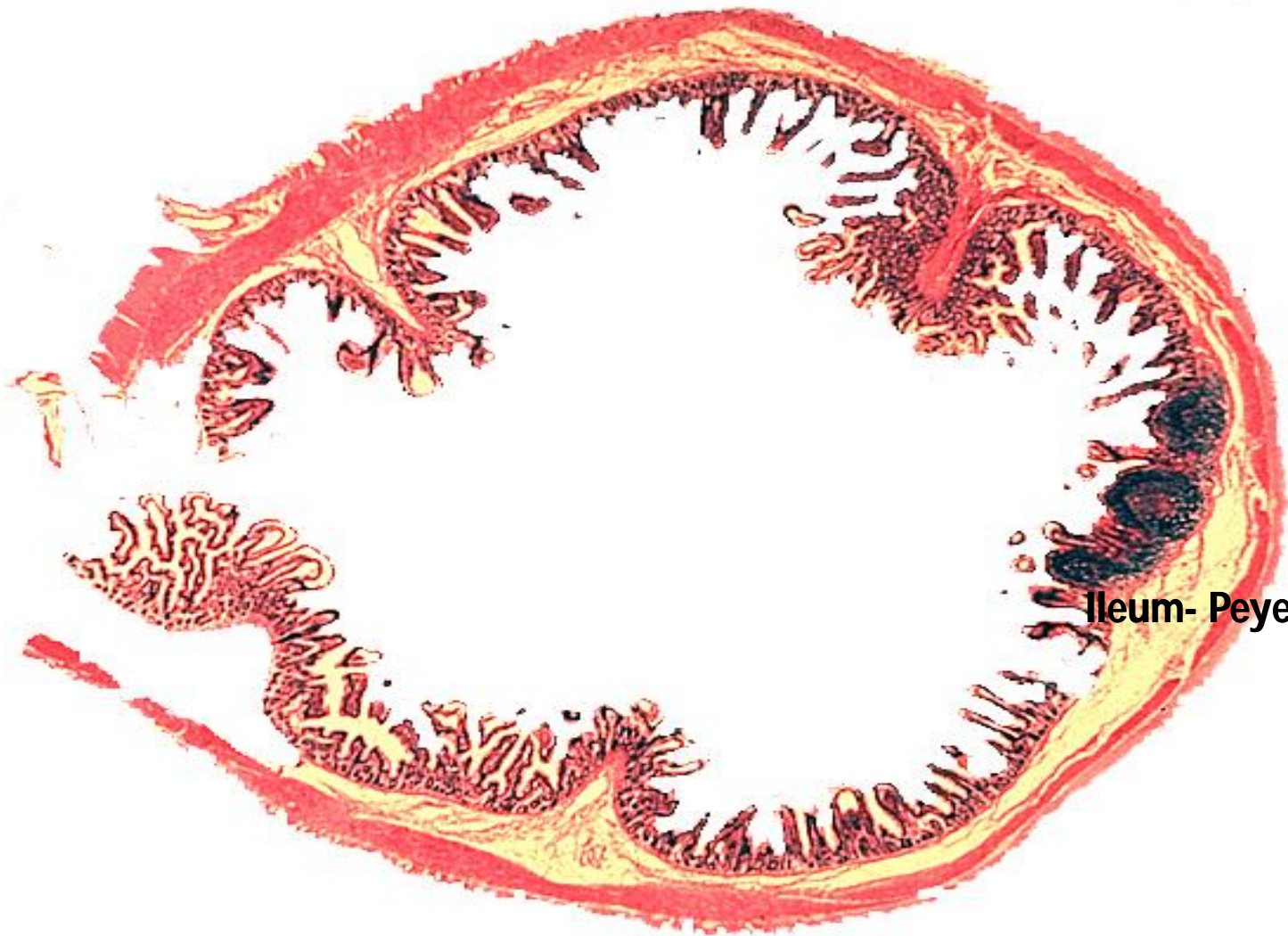# Aggregates of Lymphoid Follicles

---

- **Peyer's patches** – isolated clusters of lymphoid tissue, similar to tonsils
  - ▣ Found in the wall of the distal portion of the small intestine
  - ▣ Similar structures are found in the appendix
- **Peyer's patches and the appendix:**
  - ▣ Destroy bacteria, preventing them from breaching the intestinal wall
  - ▣ Generate “memory” lymphocytes for long-term immunity



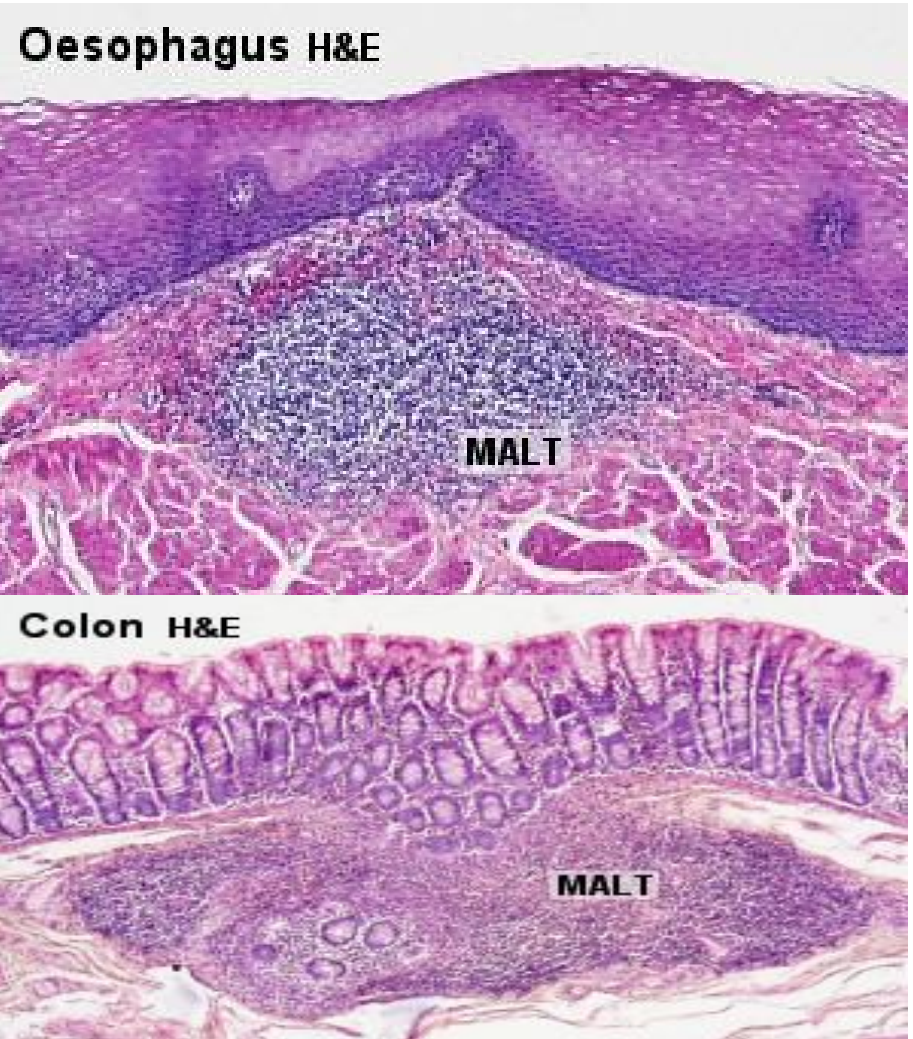




Ileum- Peyer's Patch

# MALT

- **MALT** – mucosa-associated lymphatic tissue:
  - **Peyer's patches**, **tonsils**, and **the appendix** (digestive tract)
  - Lymphoid nodules in the walls of the bronchi (respiratory tract)
- MALT protects the digestive and respiratory systems from foreign matter



# Gut-Associated Lymphoid Tissue - GALT

- Small accumulations of lymphocytes or solitary lymph follicles are found scattered in beneath the epithelium throughout the gastrointestinal tract.
- **The most prominent accumulations occur in the ileum and appendix in the form of Peyer's patches.**
- In the ileum, they form dome-shaped protrusions into the lumen.
- **Beneath the epithelial lining of the domes, Peyer's patches extend from the lamina propria to the submucosa.** Within Peyer's patches, lymph follicles with germinal centers are typically located deep in the submucosa.
- The epithelium in contact with the lymphoid tissue is specialised to facilitate the contact of antigens with cells of the immune system.
- The epithelium appears columnar and contains cells with deeply invaginated basal surfaces - microfold cells or M-cells. Immune system cells can enter these invaginations (intraepithelial pockets) where they are exposed to materials which have been endocytosed by the epithelial cells and then released into the invaginations. Goblet cells are rare or absent in the epithelium which covers the domes.



# Developmental Aspects

---

- lymph nodes are apparent by the fifth week of embryonic development
- Lymphatic organs (except the thymus) arise from mesoderm
  - The thymus (endodermal origin) forms as an outgrowth of the pharynx
  - Except for the spleen and tonsils, lymphoid organs are poorly developed at birth

## **Two forms of immunity:**

- **Humoral or antibody mediated immunity**
- **B cells (mature in bone) make antibodies: specific proteins that bind to specific antigens**

**OR**

- **Cell-mediated immunity**
- **T cytotoxic lymphocytes attack virus infected or tumor cells directly**

